



## PEDIATRIC UROLOGY CASE REPORTS

ISSN 2148-2969

<http://www.pediatricurologycasereports.com>

## Multiple calculi in a single-system orthotopic ureterocele in a two-year-old boy presenting with hematuria: A case report

Hulya Ozturk<sup>1</sup>, Mervan Bektas<sup>2</sup>, Ozgur Mehmet Yis<sup>3</sup>

Pediatric Surgery<sup>1</sup>, Pediatrics<sup>2</sup> and Biochemistry<sup>3</sup> Bolu Abant Izzet Baysal University, School of Medicine, Bolu, Turkey

### ABSTRACT

Ureterocele is the dilatation of the submucosal ureter as a result of a defect in the Chwalla membrane absorption. The many types and clinical presentations of ureters present a significant challenge to clinicians. Although stone formation in the ureterocele is common in adults, it is much less common in pediatric patients. Here, we present a case report of a two-year-old boy with single-system ureteroceles containing multiple small stones.

**Key Words:** Ureterocele; multiple calculi; hematuria; children.

*Copyright © 2018 pediatricurologycasereports.com*

*Corresponding Author: Dr. Hulya Ozturk*

*Department of Pediatric Surgery, Bolu Abant Izzet Baysal University, School of Medicine, Bolu, Turkey*

*E mail: [hulya\\_ztrk@yahoo.com](mailto:hulya_ztrk@yahoo.com)*

*ORCID ID: <https://orcid.org/0000-0001-9277-9119>*

*Accepted for publication: 20 August 2018*

### Introduction

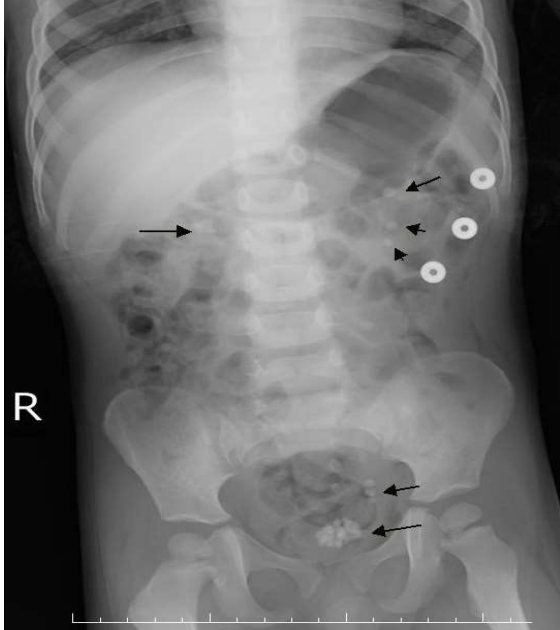
A ureterocele is a congenital cystic dilatation of the lower part of the ureter that can be intravesical (orthotopic) or extravesical (ectopic) [1,2]. This pathologic condition is often found with other anomalies, such as a stenotic ureter orifice or a duplex urinary system. It occurs in 1/500 to 1/4000 newborns and is found more frequently in females than in males [1-3]. Ureterocele can lead to complications such as obstruction, reflux, incontinence, and urinary tract infections, and, as a result, various effects can occur, from upper pole destruction in duplex systems to

renal scarring [1-4]. Additionally, there is variability in the types and clinical features of ureteroceles, which makes their diagnosis and treatment difficult [5]. Calculi formation in the ureterocele is a condition infrequently encountered in the pediatric population [3]. Here, we present a two-year-old male patient who was diagnosed intraoperatively with multiple stones in the left ureterocele, and we discuss the diagnosis and treatment process of this rare entity.

### Case report

A two-year-old male patient was admitted to our clinic with gross hematuria and abdominal pain. He had been experiencing intermittent hematuria and abdominal pain during the prior two weeks. The physical examination and laboratory tests reported normal results except for the presence of hematuria. A plain

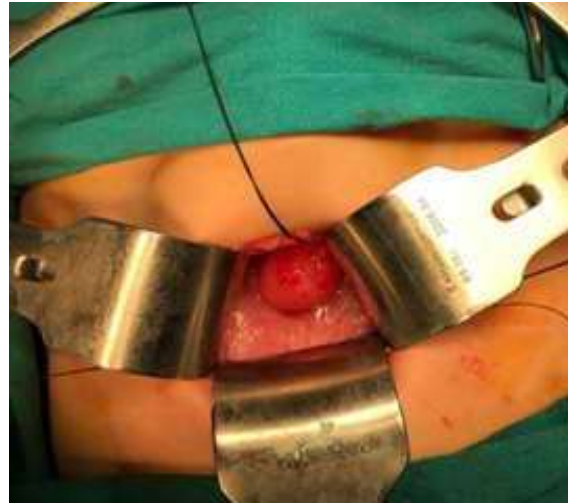abdominal X-ray showed irregular radiopaque shadows in the area of the bladder and other radiopaque stones in the right and left kidneys [Fig. 1].



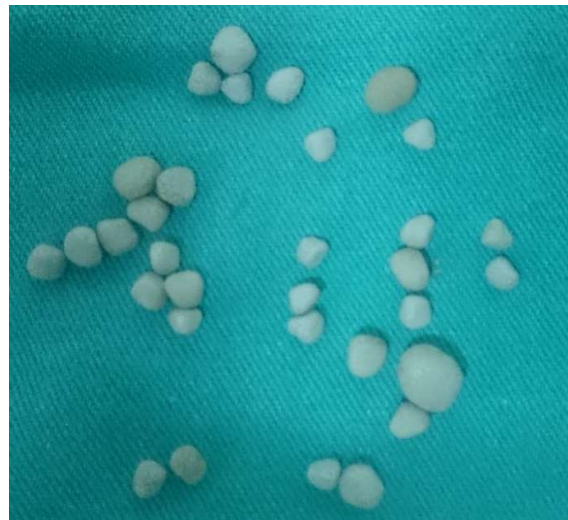**Fig. 1.** Plain abdominal radiograph showing radiopaque stones in the both kidneys and pelvis.

Urinary tract ultrasonography demonstrated a 19mm echoic area with an acoustic shadow in the bladder. In addition, more than one stone in the right and left kidneys were observed. No other pathology was observed in the kidneys. Under general anesthesia, the patient was first placed in the lithotomy position, a 9F cystoscope was inserted into the bladder, the right ureteral orifice was identified, and a large intravesical ureterocele was detected in the left ureteric location. No stones were detected in the bladder. As the left ureteral orifice could not be determined, entry into the ureterocele with a resectoscope became necessary. However, successful entry could not be achieved because the ureterocele was thick-walled, edematous, hyperemic, fragile, and had

an irregular surface. After reaching the bladder with a Pfannenstiel incision, the ureterocele was opened by surgical incision, and approximately 20 pieces of stone were removed [Figs. 2, 3].



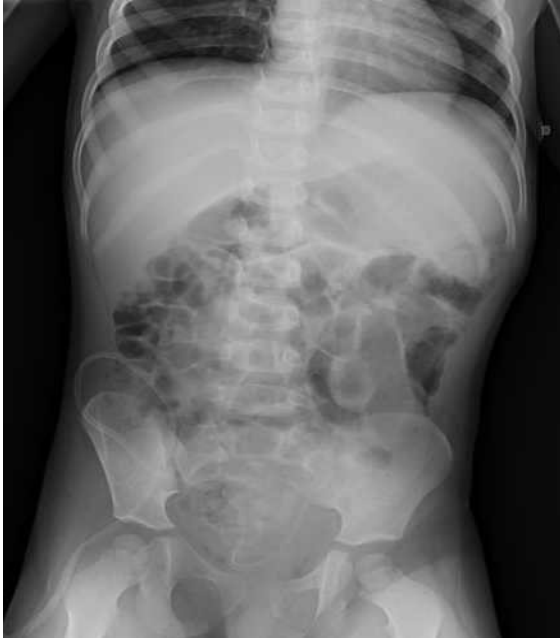**Fig. 2.** Ureterocele appearance in bladder.



**Fig. 3.** Removed multiple stones from the ureterocele.

Next, the left ureter underwent the Politano-Leadbetter re-implantation technique. Analysis of the stones showed that their composition was calcium oxalate. In addition, the patient dropped the left kidney stones by the urethral route within one month after

surgery [Fig. 4]. The patient is undergoing regular clinical, radiological, and laboratory follow-up for six months, and his general health status is good.



**Fig. 4.** Plain abdominal radiograph taken after surgery.

### Discussion

Although the pathogenesis of this developmental anomaly is unknown, it has been suggested that failure in the regression of the Chwalla membrane is a consequence [6]. Stenotic orifice ureterocele, rather than duplex ureters, are the most common type in the single ureter system. Additionally, single system and intravesical ureteroceles are almost exclusively found in adults. The incidence of stones in ureteroceles has been reported as approximately 4–39%. The rate is generally lower in children [3,7].

The clinical presentation of ureteroceles in the pediatric age group usually consists of recurrent urinary tract infections or urosepsis, renal scarring in the duplex system, incontinence, failure to thrive, urinary tract calculus, bladder outlet obstruction, or vaginal

or urethral prolapse [7,8]. In ureterocele cases, stone formation occurs for various reasons, such as urinary stasis, obstruction, ureteral atony, urinary tract infection, or family history. Patients may remain asymptomatic or may present with evidence of hematuria or obstruction [9-11].

Typically, 50–70% of patients with ureteroceles can be diagnosed by ultrasonography and intravenous pyelogram [1-11]. The presence of ureterocele wall thickening, irregularity, and edema may have precluded our radiologist's diagnosis of this condition on ultrasound. In addition, the inability to detect more than one stone in the ureterocele can be attributed to the inexperience of the radiologist.

In adults, primary treatment of ureterocele begins with minimally invasive methods. These procedures usually include transurethral incision of the ureterocele and extraction of the calculus [11,12]. This minimally invasive technique is easy to perform, comfortable, and superior to endoscopic resection and open surgery, but its use should be discussed in pediatric patients, especially if there is related vesicoureteral reflux (VUR) [13]. Excision of the ureterocele with open or endoscopic surgery presents minimal risks for iatrogenic vesicoureteral reflux and other surgical complications. Upper-pole heminephrectomy and partial upper ureterectomy are alternative treatments in pediatric patients [14].

In our case, the ureterocele was diagnosed intraoperatively during endoscopic examination and was complicated by multiple stones. The left ureteral orifice could not be determined. Additionally, successful entry into the ureterocele with a resectoscope was not possible because the ureterocele was thick-walled, edematous, hyperemic, irregular, and fragile. The ureterocele was opened with a

surgical incision, and approximately 20 pieces of stone were removed. Later, the left ureter was re-implanted using the Politano-Leadbetter technique to prevent the development of a potential VUR. Additionally, out patient's follow-ups have shown no reflux or urinary system infection. As demonstrated by this case, ureteroceles represent challenges in terms of diagnosis and treatment due to the diversity of clinical presentations and types. Thus, treatment should be individualized for each case and for the current pathology. As in our case, hematuria may be the first presentation of urolithiasis and ureterocele in children. In addition, the possibility of stones in the ureterocele should be considered in cases with bladder stone diagnosis. Ureteroceles complicated with stones can be managed efficiently by endoscopic resection or open surgery if necessary, but they require long-term follow-up.

### Compliance with ethical statements

*Conflicts of Interest:* None.

*Financial disclosure:* None.

*Consent:* All photos were taken with parental consent.

### References

- [1]Sander JC, Bilgutay AN, Stanasel I, Koh CJ, Janzen N, Gonzales ET, Roth DR, Seth A. Outcomes of endoscopic incision for the treatment of ureterocele in children at a single institution. *J Urol*. 2015;193(2):662-66.
- [2]Sauvage P, Becmeur F, Moog R, Kauffmann I. Is one-stage ureterocele repair possible in children? *Eur Urol*. 2002;42(6):607-13; discussion 613.
- [3]Shamsa A, Asadpour AA, Abolbashari M, Hariri MK. Bilateral simple orthotopic ureteroceles with bilateral stones in an adult: a case report and review of literature. *Urol J*. 2010;7(3):209-11.
- [4]Chtourou M, Sallami S, Rekik H, Binous MY, Kbaier I, Horchani A. Ureterocele in adults complicated with calculi: diagnostic and therapeutic features. Report of 20 cases. *Prog Urol*. 2002;12(6):1213-20.
- [5]Atta ON, Alhawari HH, Murshidi MM, Tarawneh E, Murshidi MM. An adult ureterocele complicated by a large stone: A case report. *Int J Surg Case Rep*. 2018;44:166-71.
- [6]Weiss JP. Embryogenesis of ureteral anomalies: a unifying theory. *Aust N Z J Surg*. 1988;58(8):631-38.
- [7]Çalışkan S. Cobra-Head Stone in Single-System Ureterocele. *Iran J Med Sci*. 2017 ;42(2):221-22.
- [8]Murshidi MS. Orthotopic and ectopic ureteroceles in children. *Int Urol Nephrol*. 1990;22(1):45-56.
- [9]Schlussel RN, Retik AB. Ectopic ureter, ureterocele, and other anomalies of the ureter. In: Wein AJ, Kavousi LR, Novick AC, Partin A, Peters CA (eds) *CampbellWalsh urology*, 9th ed. W. B. Saunders, Philadelphia, 2007:3398.
- [10]Singh I. Adult bilateral non-obstructing orthotopic ureteroceles with multiple calculi: endoscopic management with review of literature. *Int Urol Nephrol*. 2007;39(1):71-74.
- [11]Sarsu SB, Koku N, Karakus SC. Multiple Stones in a Single-System Ureterocele in a Child. *APSP J Case Rep*. 2015;6(2):19.
- [12]Mizuno K, Kamisawa H, Hamamoto S, Okamura T, Kohri K. Bilateral single-system ureteroceles with multiple calculi in an adult woman. *Urology*. 2008;72(2):294-95.

- [13] Yoo E, Kim H, Chung S. Bladder surgery as first-line treatment of complete duplex system complicated with ureterocele. *J Pediatr Urol*. 2007;3(4):291-94.
- [14] Adorisio O, Elia A, Landi L, Taverna M, Malvasio V, Danti AD. Effectiveness of primary endoscopic incision in treatment of ectopic ureterocele associated with duplex system. *Urology*. 2011;77(1):191-94.

Access this article online

<http://pediatricurologycasereports.com>

Quick Response Code

