



PEDIATRIC UROLOGY CASE REPORTS

ISSN 2148-2969

<http://www.pediatricurologycasereports.com>

Diagnosis and surgical repair of congenital H-type rectovestibular fistula in girls with normal anus: Two case reports and a review of the literature

Mehmet Hanifi Okur, Suat Cal, Selcuk Otcu

Department of Pediatric Surgery, Dicle University, School of Medicine, Diyarbakir, Turkey

ABSTRACT

Congenital H-type rectovestibular fistula with normal anus is a rare form of anorectal malformations. In the diagnosis of a female patient with H-type fistula, history may have an important role, creating a high degree of suspicion and calling for direct careful examination of the vestibule. There is also no consensus on the optimal treatment of this rare anomaly. Here, we present the diagnosis, clinical and anatomical features, and treatment results in the cases of two girls who had an H-type fistula with normal anus.

Key Words: H-type rectovestibular fistula; anorectal malformation; perineal canal; double termination of the alimentary tract; girls.

Copyright © 2018 [pediatricurologycasereports.com](http://www.pediatricurologycasereports.com)

Corresponding Author: Dr. Mehmet Hanifi Okur
Department of Pediatric Surgery, Dicle University,
School of Medicine, Diyarbakir, Turkey
E mail: m.hanifi-okur@hotmail.com
ORCID ID: <https://orcid.org/0000-0002-6720-1515>
Accepted for publication: 18 August 2018

Introduction

Anorectal malformations (ARMs) are common congenital abnormalities that constitute a significant part of proctological childhood diseases. Congenital H-type rectovestibular fistula, a rare variant on this spectrum, is found in only 3% of the world's normal anus cases. H-type rectovestibular fistula is reported to be 12.5% higher in East Asia and India, although there are a small number of ARM cases in North America [1–3]. However, the reason for this is not fully known. In addition, the H-type rectovestibular fistula accounts for 7% to 14%

of all ARMs in girls and is higher in girls than in boys [4]. Although there is no consensus on the optimal treatment of this rare anomaly, surgical repairs including perineal repair, vestibulo-anal pull-through, anterior perineal anorectoplasty, and a limited or formal posterior sagittal anorectoplasty (PSARP) have been described [1, 5–7]. Despite these diverse treatment approaches, fistula recurrence is observed in 5–30% of cases [6–8]. Here, we present the diagnosis, clinical and anatomical features, and treatment results in the cases of two girls who had an H-type fistula with normal anus.

Case report 1

The patient was six months old when she applied to our clinic. According to the patient history, she had applied to an outside hospital

at three months of age with the complaint that stool came from the vagina and with a urinary-tract infection and vulvovaginitis. It was understood that the patient had undergone a diverting sigmoid colostomy in the same health center. However, it was also reported that the location of the fistula could not be determined precisely. In order to confirm the diagnosis, the patient was first examined under anesthesia. She was found to have an H-type rectovestibular fistula with a normal anus. Later, definitive repair of the fistula was carried out. The preoperative mechanical bowel cleansing was performed at the distal opening of the sigmoid colostomy. When clean stool appeared, the procedure was terminated. Under general anesthesia, the vaginal and perianal region of the patient, who was brought to the lithotomy position, was washed with antiseptic solutions and draped in sterile fashion. First, the rectovestibular fistula was cannulated with a suitable volume Hegar dilator [Figs. 1, 2].

Multiple 5/0 silk sutures were placed around the opening on the vestibular side of the fistula to serve as retraction during dissection. Thereafter, a circumferential incision was made around the fistula tract using a fine electrocautery needle, and the incision was advanced in the direction of the vestibular rectum.

The entire fistula tract was resected, and the openings of the vestibule and rectum were approximated with interrupted 4/0 Vicryl sutures. No evidence of re-fistulization or anal stenosis was observed. The patient's stoma was closed after three months.

Case report 2

A six-month-old-girl born at term was brought to our clinic by her mother, who had noticed stool output from the vaginal vestibulum and with a urinary-tract infection and vulvovaginitis. A physical exam revealed that the patient had a normally positioned anus with adequate sphincter tone. Stool output was evident through the vaginal orifice. The patient was taken to the operating room for a recto-genital exam under anesthesia, where a rectovestibular fistulous tract one cm proximal to the dentate line was easily canalized using a using a 24 GA angiocatheter. The patient had a normal, non-stenotic anus. The diagnosis was consistent with a congenital H-type rectovestibular fistula. The patient underwent a diverting sigmoid colostomy and was discharged. Follow up in the pediatric-surgery outpatient clinic showed no clinical deterioration or evidence of infection, and the patient had a definitive surgery one month later. The definitive treatment in this case was the same as the procedure used in the first case.

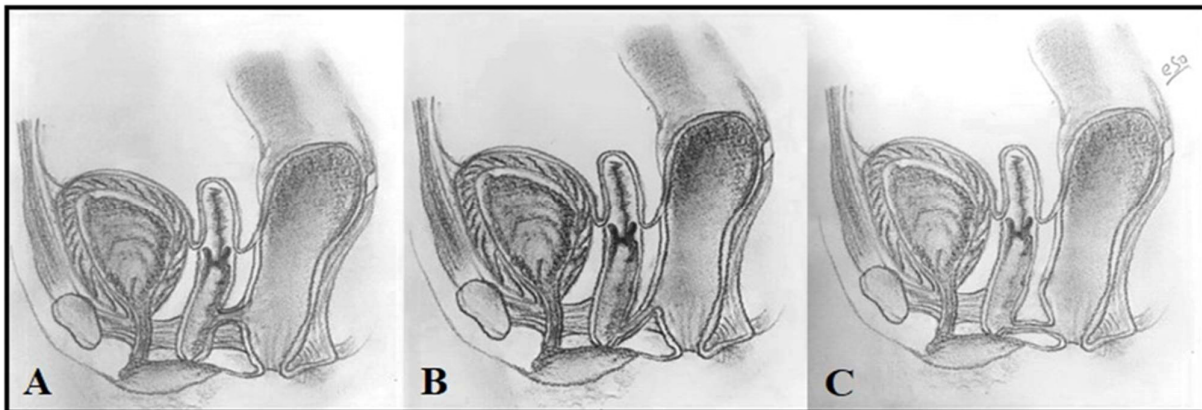


Fig. 1. Three types of congenital H-Type fistula in females: A-rectovaginal fistula, B-rectovestibular fistula and, C-anovestibular fistula.

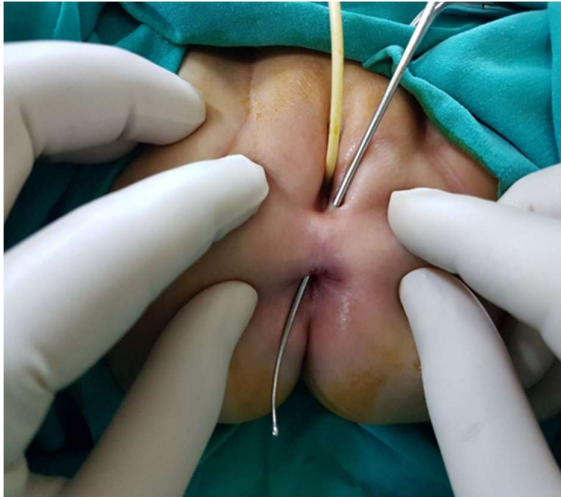

Fig. 2. Case 1, H-type rectovestibular fistula, the Hegar dilator crossing the tract and the two openings of the fistulous tract are shown.

Discussion

H-type anorectal malformation is a congenital recto-urogenital connection associated with a normal or ectopic anal opening [6]. The etiology of H-type fistulas is uncertain, but the condition is generally thought to be congenital in cases associated with H-type ARMs. Although various theories have been proposed to explain the embryology of the fistula, it appears that, based on recent advances in the understanding of embryology, a faulty embryonic caudal-folding process may explain the formation of an H-type anorectal anomaly [6, 9, 10]. The incidence of female cases has been reported in a proportion ranging from 0.7% (USA) to 14% (Asia) of all anorectal malformation cases. In addition, this malformation was found to be 2.5–6 times more common in females than in males in regional series [1–4]. In females, these anomalies are of three types: rectovaginal, anovestibular, and rectovestibular fistula, associated with normal localization and size of the anus [1, 2, 8, 11]. Generally, the volume of the fistula varies from 1 to 6 mm and is less than 1 cm in infancy. However, the size of the

fistula, especially in girls, can increase with the child's age and the vagina or vestibule's becoming larger [12].

H-type fistula can rarely be diagnosed immediately after birth. The most common presentation in the majority of female patients is the passage of a small amount of fecal matter from the vestibule. Patients may also present with constipation, labial abscesses, and recurrent urinary-tract infections [1, 6, 8]. Both of our patients had complaints of stool output from the vestibule and urinary-tract infection. The diagnosis of our patients was possible only by careful examination under anesthesia and catheterization of the fistula tract. In our review, examination under anesthesia was the most helpful way of confirming the diagnosis and was also useful for checking for anorectal stenosis using Hegar dilators, as in other studies [1]. Vestibuloscopy and vaginoscopy can help some diagnoses but not all.

Various surgical techniques for repair of H-type vaginal or vestibular fistulae have been described from the initial detection of anomalies in 1960 to the present [13, 14]. Among these procedures, perineal repair, fistulectomy, abdominoperineal repair, PSARP, vestibulo-anal pull-through, anterior perineal anorectoplasty, and a trans-anal approach are generally described in the literature [6, 8, 11, 12]. In both of our cases, excision of the whole tract through a circumferential vestibular incision and repair of the defect through the rectum were performed. In addition, the opening of a colostomy before or during fistula repair is controversial and has been claimed not to reduce the recurrence rate [5]. However, the surgeon may decide to open the colostomy according to the characteristics of the patient. A sigmoid colostomy was performed before definitive surgery in both of our cases. These

may be prefer to in recurrent cases, for high anomalies such as a rectovaginal fistula in girls, or for safer repair [12]. After H-type fistula repair, fistula recurrence has been reported in 5–30% of cases and wound disruption in 0–25% of cases. Recurrence, which is a major complication in these cases, can be prevented by full excision of the fistula tract. Additionally, it is important that the vestibular and rectal repair be performed on different planes of suture lines [3]. The epithelium of the fistula tract in females is lined with stratified squamous [10]. Females with H-type fistula usually have normal sphincter control, and incontinence has not been reported in post-operative follow-up [15], as in our cases.

In conclusion, in the diagnosis of a female patient with H-type fistula, history may have an important role, creating a high degree of suspicion and calling for direct careful examination of the vestibule. Although colostomy is not widely preferred in females with H-type fistula repair, the ostomy was opened prior to fistula repair in both of the cases presented here, and the treatment was safely applied. No complications such as recurrence developed. Additionally, complete excision of the fistula tract and adequate mobilization may reduce the likelihood of recurrence.

Compliance with ethical statements

Conflicts of Interest: None.

Financial disclosure: None.

Consent: All photos were taken with parental consent.

References

[1] Lawal TA, Chatoorgoon K, Bischoff A, Peña A, Levitt MA. Management of H-type

rectovestibular and rectovaginal fistulas. *J Pediatr Surg.* 2011;46(6):1226-30.

[2] Banu T, Hannan MJ, Hoque M, Aziz MA, Lakhoo K. Anovestibular fistula with normal anus. *J Pediatr Surg.* 2008;43(3):526-29.

[3] Kelleher DC, Henderson PW, Coran A, Spigland NA. The surgical management of H-type rectovestibular fistula: a case report and brief review of the literature. *Pediatr Surg Int.* 2012;28(6):653-56.

[4] Tsuchida Y, Saito S, Honna T, Makino S, Kaneko M, Hazama H. Double termination of the alimentary tract in females: a report of 12 cases and a literature review. *J Pediatr Surg.* 1984;19(3):292-96.

[5] Kulshrestha S, Kulshrestha M, Prakash G, Gangopadhyay AN, Sarkar B. Management of congenital and acquired H-type anorectal fistulae in girls by anterior sagittal anorectovaginoplasty. *J Pediatr Surg.* 1998;33(8):1224-28.

[6] Rintala RJ, Mildh L, Lindahl H. H-type anorectal malformations: incidence and clinical characteristics. *J Pediatr Surg.* 1996;31(4):559-62.

[7] Otamuradov FA, Ergashev N Sh. The H-type anorectal malformations in girls. *Int J Gastroenterol Hepatol Transpl Nutr* 2016;1(iii): 16-19

[8] Li L, Zhang TC, Zhou CB, Pang WB, Chen YJ, Zhang JZ. Rectovestibular fistula with normal anus: a simple resection or an extensive perineal dissection? *J Pediatr Surg.* 2010 ;45(3):519-24.

[9] Nievelstein RA, van der Werff JF, Verbeek FJ, Valk J, Vermeij-Keers C. Normal and abnormal embryonic development of the anorectum in human embryos. *Teratology.* 1998;57(2):70-78.

- [10] van der Putte SC. Normal and abnormal development of the anorectum. *J Pediatr Surg.* 1986;21(5):434-40.
- [11] Tsugawa C, Nishijima E, Muraji T, Satoh S, Kimura K. Surgical repair of rectovestibular fistula with normal anus. *J Pediatr Surg.* 1999;34(11):1703-5.
- [12] Sharma S, Gupta DK. Diversities of H-type anorectal malformation: a systematic review on a rare variant of the Krickbeck classification. *Pediatr Surg Int.* 2017;33(1):3-13.
- [13] Bryndorf J, Madsen CM. Ectopic anus in the female. *Acta Chir Scand.* 1960;118:466-478.
- [14] Chatterjee SK, Talukder BC. Double termination of the alimentary tract in female infants. *J Pediatr Surg.* 1969;4:237-43.
- [15] Wu YM, Wang CD, Lv F, Zhang C, Yan ZL. The Surgical Management of H-Type Rectovestibular Fistula: A Novel Modification. *Eur J Pediatr Surg.* 2016;26(4):336-39.

Access this article online

<http://pediatricurologycasereports.com>

Quick Response Code

