

Original Research Article

A comparative evaluation of relationship between Collum angle and root resorption of maxillary central incisors in Class I and Class II Division 2 malocclusion following non-extraction orthodontic treatment - A radiographic study

Poorva Attarde^{1*}, Vishnupriya TR¹, Kiran Kumar HC¹

¹Dept. of Orthodontics and Dentofacial Orthopedics, Bapuji Dental College and Hospital, Davangere, Karnataka, India

Abstract

Objective: To evaluate and compare the relationship between the Collum angle of maxillary central incisors and root resorption following non extraction orthodontic treatment.

Materials and Methods: A total of 80 patients (age range 13–25 years) were divided into two groups based on malocclusion type and Collum angle. The relationship between Collum angle and root resorption was assessed using the Chi-square test.

Results: Group I (Class I) subjects showed a mean Collum angle of -7.4° pre-treatment and -5.5° post-treatment, while Group II (Class II Division 2) had a significantly higher angle of 8.2° pre-treatment and 5.9° post-treatment. Pre-treatment root resorption was milder in both groups, with Group II showing predominantly Grade 0 resorption. Post-treatment, root resorption severity increased in both groups, but was more pronounced in Group II, with 25% showing Grade 3 resorption. Overall, 99% of patients exhibited some degree of resorption, with statistically significant differences between groups both before ($p = 0.003$) and after ($p = 0.013$) treatment, indicating that higher Collum angles in Class II Division 2 malocclusions are associated with greater root resorption following orthodontic therapy.

Conclusions: The Collum Angle of maxillary central incisors in Class II Division 2 malocclusions was greater than Class I malocclusions and is associated with increased root resorption following orthodontic treatment.

Keywords: Collum angle, Orthodontically induced root resorption, Class I and Class II Division 2 malocclusion, Anterior teeth biomechanics, Orthodontic treatment.

Received: 30-05-2025; **Accepted:** 18-06-2025; **Available Online:** 20-06-2025

This is an Open Access (OA) journal, and articles are distributed under the terms of the [Creative Commons Attribution-NonCommercial-ShareAlike 4.0 International License](https://creativecommons.org/licenses/by-nc-sa/4.0/) which allows others to remix, tweak, and build upon the work non-commercially, as long as appropriate credit is given and the new creations are licensed under the identical terms.

For reprints contact: reprint@ipinnovative.com

1. Introduction

Anatomy of a tooth exhibits considerable variability, influencing occlusion and three-dimensional positioning within the oral cavity. It is assumed that the root follows the same longitudinal axis of the crown. However, there is considerable evidence in the literature enlightening the variability in the relationship between the root and the crown. The collum angle, denotes the angular difference between the crown and root axis and the morphological bending that occurs between the crown and root leading to inaccuracies in clinical assessments. Recognizing and understanding the implications of the collum angle is vital for accurate diagnosis and effective treatment planning.¹

The variability of crown form is readily visible and adjustable clinically through alterations in wire or bracket positioning. However, the root positioning, which is less apparent, is often overlooked despite its significant impact on treatment success and stability. Deviances in root angulations can induce unintended axial loads during orthodontic tooth movement, potentially causing the root to encroach on the labial or lingual cortical plates thereby increasing the potential risk of root resorption, a very critical concern in orthodontic treatment.²

Orthodontic treatment has been consistently associated with an increased risk of root resorption, particularly in teeth with pronounced collum angles. Research indicates that the

*Corresponding author: Poorva Attarde
 Email: poorva.pravin.92@gmail.com

collum angle is a characteristic feature of Angle's Class II Division 2 malocclusion and in these cases, the crown-root relationship presents unique biomechanical challenges that complicate tooth movements and increase susceptibility to root resorption.³ Root resorption is a pathological process resulting in the irreversible loss of substantial amount of tooth material in root apex. Orthodontic forces exert stress on the periodontal ligament and alveolar bone, triggering inflammatory biochemical changes that could lead to root resorption. A greater collum angle may alter the distribution of orthodontic forces on the root surface, leading to high susceptibility of root resorption.⁴

Profound orthodontic literature has explored the relationship between Collum angle and root resorption. Despite this, a few studies have explicitly examined the direct relationship between the maxillary central incisors collum angle and root resorption following orthodontic treatment. This study aimed to evaluate the prevalence and degree of relationship between the collum angle and root resorption in class I and Class II div 2 malocclusion following non extraction orthodontic treatment using pre adjusted edgewise appliance. There by exploring the potential clinical guidelines for manging pronounced collum angle in maxillary central incisors and also bridge the gap between anatomical variability and orthodontic treatment outcomes, ultimately contributing to improve patient care and long-term stability of the orthodontic treatment.

2. Materials and Methods

This retrospective study involved the evaluation of pretreatment and post-treatment lateral cephalograms and intraoral periapical radiographs of 80 orthodontically treated individuals of Class I and Class II Division 2 malocclusion. The radiographs were obtained from the archives of the Department of Orthodontics and Dentofacial Orthopaedics, Bapuji Dental College and Hospital, Davangere. The sample included two equal groups based on the type of malocclusion. Group I comprised patients with Class I malocclusion, and Group II consisted of patients with Class II Division 2 malocclusion, with all participants treated non-extraction treatment modality using Preadjusted Edgewise with MBT prescriptions. The age of the subjects ranged between 13 and 25 years. The sample size determination was based on the parameters: population means ($\mu_A = 10.2$ and $\mu_B = 8.5$), standard deviation ($\sigma = 2.0$), a Type I error (α) of 5%, and study power ($1-\beta$) of 80%, which yielded a total sample size of 80. Exclusion criteria involved patients with maxillary central incisors that were restored, prosthetically replaced, previously traumatized, or had undergone root canal therapy.

Standardised lateral cephalograms were obtained in habitual occlusion with lips at rest. The radiographs were manually traced by the investigator and cross-verified by a co-investigator to minimize observer bias. The study placed particular emphasis on evaluating the collum angle and root

resorption. The collum angle was measured using the method described by Delivanis and Kuftevec (1980), which involves defining the longitudinal axis of the incisor, the root (Ap to D), and the crown (IS to D) (**Figure 1**). A positive collum angle was recorded when the crown was inclined lingually relative to the root, and a negative value was recorded when the crown was inclined facially.

Root resorption was graded on a five-point scale (based on Malmgren et al.) (**Table 1**) by assessing the more visible maxillary central incisor on intraoral periapical radiographs at the beginning and end of the treatment. The severity of external apical root resorption and its potential correlation with the type of malocclusion and incisor collum angle were analyzed.

Table 1: Root resorption estimate

Grade 0	No root resorption
Grade 1	Irregular root contour
Grade 2	Root resorption apically amounting to less than 2 mm; minor resorption
Grade 3	Root resorption apically from 2 mm to one third of the original root length; severe resorption
Grade 4	Root resorption exceeding one-third of the original root length; extreme resorption

The reliability and reproducibility of measurements were ensured through rigorous validation procedures. The co-investigator verified all cephalometric tracings, and intra-observer reliability was assessed by reanalyzing 20 randomly selected cephalograms after a two-week interval using Dahlberg's formula. To further minimise intra- and inter-observer variability, 10 cephalograms were retraced and re-evaluated after one month, and five intraoral periapical radiographs from each group were independently reviewed by the Head of the Department of Oral Medicine and Radiology. Statistical analysis was carried out based on the distribution of the data. The chi-square test was employed to evaluate the association between the type of malocclusion and the incidence of root resorption. All analyses were conducted to determine whether malocclusion type had a significant influence on collum angle and apical root resorption.

3. Results

The mean pre-treatment age in Group I (16 ± 3.09 years) and Group II (15.9 ± 3.08 years), and the mean post-treatment ages in Group I (18.8 ± 3.24 years) and Group II (18.4 ± 3.39 years), with mean treatment durations of 2.8 ± 1.33 years and 2.6 years. The pre-treatment Collum angle in Group I ($-7.4^\circ \pm 2.55^\circ$), in Group II ($8.2^\circ \pm 3.13^\circ$), with a p-value of <0.001 , indicating high statistical significance. Post-treatment, the Collum angle reduced to $-5.5^\circ \pm 2.35^\circ$ in Group I and $5.9^\circ \pm 2.27^\circ$ in Group II, with a p-value of <0.001 , which was also highly significant.

The ANB angle in Group I ($2.6^\circ \pm 1.03^\circ$) and Group II ($4.6^\circ \pm 1.57^\circ$), with a highly significant p-value of <0.001 . The findings suggest that a greater Collum angle in Class II, Division 2 malocclusions is associated with increased root resorption post-treatment. These results emphasize the importance of considering the Collum angle in treatment planning to minimize the risk of excessive root resorption.

In Group 1 (Class I malocclusion), 55% (22 out of 40 patients) exhibited an average growth pattern, whereas in Group 2 (Class II Division 2 malocclusion), this percentage was lower at 40% (16 out of 40 patients). The overall prevalence of the average growth pattern across both groups was 47.5% (38 out of 80 patients). The horizontal growth pattern was observed in 42.5% (17 out of 40) of Group 1 patients, while Group 2 showed a higher prevalence of 60% (24 out of 40 patients). The combined occurrence of the horizontal growth pattern across both groups was 51.2% (41 out of 80 patients). Vertical growth patterns were the least common, with only 2.5% (1 out of 40) of patients in Group 1 displaying this pattern, and none in Group 2. The overall prevalence of the vertical growth pattern was just 1.2% (1 out of 80 patients). These results indicate that the horizontal growth pattern was more frequent in Class II Division 2 malocclusion cases, whereas the average growth pattern was more common in Class I malocclusion cases. Vertical growth patterns were exceedingly rare among all study participants.

Table 2 analysed the influence of the Collum angle on root resorption in orthodontic treatment among 80 patients, divided into Class I malocclusion (Group I) and Class II Division 2 malocclusion (Group II). Statistical tests were conducted to compare pre-treatment and post-treatment values.

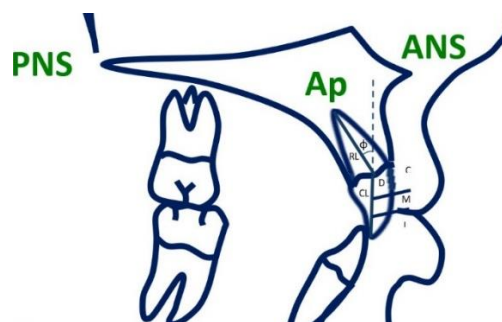


Figure 1: Cephalometric landmarks for the measurement of collum angle; C – Cervical third of incisor, M – Middle third of incisor, I – Incisal third of incisor; Θ - Collum angle - The angle between the lines Ap-D and D-IS, Point Ap - The radiographic apex of the root, Point D - The midpoint between the lingual and facial projections of the cemento-enamel junction, RL - Longitudinal axis of the root, CL - Longitudinal axis of the crown, IS – Incision superior

The pre-treatment Collum angle was significantly higher in Group II ($8.2^\circ \pm 3.13^\circ$) compared to Group I ($-7.4^\circ \pm 2.55^\circ$) ($p < 0.001$). Post-treatment, the Collum angle reduced in both groups but remained significantly different ($p < 0.001$). Root resorption was minimal before treatment but significantly increased post-treatment, with more severe resorption in Class II Division 2 cases ($p = 0.013$). Age, treatment duration, and mandibular plane angle showed no significant differences between groups. The findings highlight the increased risk of root resorption in Class II Division 2 malocclusion patients due to a higher Collum angle.

Table 3 The pre-treatment root resorption analysis was conducted to evaluate its prevalence among the study participants. Pre-treatment root resorption analysis based on Malmgren et al. grading showed that in Group I, 50% of patients had Grade 0 resorption, 45% had Grade 1, and 5% had Grade 2. In Group II, 80% had Grade 0 resorption, 20% had Grade 1, and none had Grade 2. Comparing both the groups, 65% of patients had Grade 0, 32.5% had Grade 1, and 2.5% had Grade 2 resorption. The p-value of 0.003 indicated a statistically significant difference in pre-treatment root resorption between the groups.

Table 2: Descriptive statistics of study groups

	Group I			Group II			t	df	p-value
	n	Mean	\pm SD	n	Mean	\pm SD			
Pretreatment Age	40	16.0	3.09	40	15.9	3.08	0.18	78	0.857
Post Treatment Age	40	18.8	3.24	40	18.4	3.39	0.44	78	0.662
Duration	40	2.8	1.33	40	2.6	0.93	0.78	78	0.438
Pretreatment Collum Angle	40	-7.4	2.55	40	8.2	3.13	24.35	78	< 0.001
Post Treatment Collum Angle	40	-5.5	2.35	40	5.9	2.27	21.91	78	< 0.001
Pre-treatment Root Resorption	40	0.6	0.60	40	0.2	0.41	3.07	78	0.003
Post-Treatment Root Resorption	40	1.4	0.87	40	1.9	0.80	2.54	78	0.013
ANB Angle	40	2.6	1.03	40	4.6	1.57	6.67	78	< 0.001
Mandibular Plane Angle	40	28.5	3.88	40	28.5	5.31	0.00	78	1.000

Table 3: Frequency distribution of pre-treatment and post-treatment root resorption

		Group			
		I		II	
		N	%	N	%
Pre-treatment root resorption	0	20	50.0%	32	80.0%
	1	18	45.0%	8	20.0%
	2	2	5.0%	0	.0%
Total		40	100.0%	40	100%
Post-treatment root resorption	0	8	20%	0	0%
	1	11	27.5%	16	40%
	2	19	47.5%	14	35%
	3	2	5%	10	25%
Total		40	100.0%	40	100%

The post-treatment root resorption analysis was conducted to assess the distribution of different growth patterns among the study participants. Post-treatment root resorption, Group I, 20% of patients showed Grade 0, 27.5% showed Grade 1, 47.5% showed Grade 2, and 5% showed Grade 3 resorption. In Group II, none had Grade 0 resorption, 40% had Grade 1, 35% had Grade 2, and 25% had Grade 3 resorption. In total, comparing both groups, 10% had Grade 0, 33.8% had Grade 1, 41.2% had Grade 2, and 15% had Grade 3 root resorption post-treatment. The p-value of 0.013 indicated statistical significance.

4. Discussion

The literature is evident with the findings that the alignment of the crown and root axis of incisors is assumed to be identical. However, crown dimensions and structure are under moderate genetic control and the movement of the root is more susceptible to environmental factors.⁵ In orthodontics, root angulation relative to the crown is of particular interest, especially for single-rooted anterior teeth, as deviant angulations can complicate axial loading, repositioning and potentially increasing the root to be in close proximity to the cortical plates. Which may result in increased stress on the root apex during torque application, predisposing it to external apical root resorption (EARR).¹ This concept was supported by Alhaidary SA et al. (2024), who reported that variations in root-crown angulation directly influence the risk of EARR during torquing movements.⁶

Class I malocclusion typically presents with normal to mildly proclined incisors, while Class II Division 2 malocclusion is characterized by retroclined maxillary central incisors with an increased Collum angle. This anatomical difference was expected to influence the force vectors during treatment, particularly when incisor proclination is required to achieve ideal overjet and incisor display. Harris EF (1993), extensively described the morphological variations of the maxillary central incisor,

emphasizing that root-to-crown relations vary due to curvature differences¹.

The current study's finding of a significantly higher mean Collum angle in Class II Division 2 malocclusion ($8.2^\circ \pm 3.13^\circ$) than in Class I ($-7.4^\circ \pm 2.55^\circ$) is consistent with previous literature by Srinivasan(2013),⁷ who noted retroclined incisors in Class II Division 2 patients displaying increased Collum angles. On evaluating this between the 2 groups the mean pre-treatment Collum angle in Group I was reduced to $-5.5^\circ \pm 2.35^\circ$ post-treatment and in Group II, the pre-treatment Collum angle was reduced to $5.9^\circ \pm 2.27^\circ$ following orthodontics treatments. These findings indicate that the crown-root shape of the maxillary central incisor in Class II Division 2 malocclusions varies from that in Class I malocclusion.

Post-treatment root resorption was significantly more severe in the Class II Division 2 group, with 25% of cases showing Grade 3 resorption, compared to only 5% in Class I. It revealed 99% of cases displayed root resorption with a moderate grade ranging between 1 and 2. These findings align with Mirabella and Artun (1995),⁸ who demonstrated that teeth undergoing significant torquing or root movement, particularly maxillary central incisors, are more susceptible to apical resorption. It also highlighted the susceptibility of maxillary incisors to EARR due to their frequent involvement in torque movements. Further, studies also emphasized that retroclined incisors in Class II Division 2 cases often require aggressive torque and labial root movement during alignment, increasing mechanical stress on the apical root third, which can explain an increased percentage of resorption observed in this study.⁹⁻¹²

In support of these findings, Agarwal et al. (2016) found that patients with increased incisor inclination change and root morphology irregularities showed significantly more EARR post-treatment.¹³

Despite these associations, several studies challenge the deterministic role of the Collum angle in predicting root

resorption. Weltman et al. (2010), in a systematic review, emphasized the multifactorial etiology of EARR, highlighting treatment duration, force magnitude, root morphology, and genetic predisposition as confounding variables.¹⁴ This suggests that while high Collum angles may predispose teeth to higher resorption risk, they are not the sole determinant.

Additionally, Mavragani et al. (2002) found no strong correlation between initial incisor inclination and the extent of root resorption, suggesting that individual biological variability plays a substantial role.¹⁵ Levander and Malmgren (2000) also argued that orthodontic-induced root resorption is not always related to tooth movement magnitude or direction but may be influenced by patient-specific responses, including inflammatory mediator expression.¹⁶

5. Conclusion

The present study measured the collum angle and the root resorption in maxillary central incisors for Class I and Class II Division 2 malocclusion and evaluated whether the presence of collum angle of maxillary central incisors can cause root resorption of the teeth following orthodontic treatment.

The following conclusions were drawn:

1. The collum angle of maxillary incisors in Class II division 2 malocclusion was higher compared to Class I cases.
2. The crown of the maxillary central incisor in Class II division 2 was placed lingually compared to its root whereas in Class I malocclusion the crown of the maxillary central incisor was placed facially compared to its root.
3. In Class II division 2 malocclusion, the maxillary central incisors showed more root resorption post treatment compared to the control group.
4. So, we can conclude saying that more the crown root angulation deviation before start of treatment, more will be the root resorption post orthodontic treatment.

6. Ethics

The study was approved by the Institutional Ethics Committee with the reference number BDC/Exam/283/2016-17 (Certificate is attached as a supplementary file)

7. Source of Funding

The authors received no financial support for the research, authorship, and/or publication of this article.

8. Conflict of Interest

There is no conflict of interest.

References

1. Harris EF, Hassankladeh S, Harris JT. Maxillary incisor crown-root relationships in different Angle malocclusions. *Am J Orthod Dentofacial Orthop.* 1993;103(1):48–53.
2. Delivanis HP, Kufinec MM. Variation in morphology of the maxillary central incisors found in class II, division 2 malocclusions. *Am J Orthod.* 1980;78(4):438–443.
3. Bryant RM, Sadowsky PL, Hazelrig JB. Variability in three morphologic features of the permanent maxillary central incisor. *Am J Orthod* 1984;86(1):25–32.
4. Levander E, Bajka R, Malmgren O. Early radiographic diagnosis of apical root resorption during orthodontic treatment: A study of maxillary incisors. *Eur J Orthod.* 1998;20(1):57–63.
5. McIntyre GT, Millett DT. Crown-root shape of the permanent maxillary central incisor. *Angle Orthod.* 2003;73:710–5.
6. Alhaidary SA, Al-Haddad KA, Al-Harazi GA, Mashyakhy MH, Adlan SS, Abu-Melha AS. Root-crown Ratio of Maxillary and Mandibular Anterior Permanent Teeth in Yemeni Adults using CBCT. *J Contemp Dent Pract.* 2024;25(12):1119.
7. Srinivasan B, Kailasam V, Chitharanjan A, Ramalingam A. Relationship between crown-root angulation (collum angle) of maxillary central incisors in Class II, division 2 malocclusion and lower lip line. *Orthodontics.* 2013;14(1):e66–e74.
8. Mirabella AD, Årtun J. Prevalence and severity of apical root resorption of maxillary anterior teeth in adult orthodontic patients. *Eur J Orthod.* 1995;17(2):93–9.
9. Remington DN, Joondeph DR, Årtun J, Riedel RA, Chapko MK. Long-term evaluation of root resorption occurring during orthodontic treatment. *Am J Orthod Dentofacial Orthop.* 1989;96(1):43–6.
10. Kaley J, Phillips C. Factors related to root resorption in edgewise practice. *Angle Orthod.* 1991;61(2):125–32.
11. Kjør I. Morphological characteristics of dentitions developing excessive root resorption during orthodontic treatment. *Eur J Orthod.* 1995;17(1):25–34.
12. Baumrind S, Korn EL, Boyd RL. Apical root resorption in orthodontically treated adults. *Am J Orthod Dentofacial Orthop.* 1996;110(3):311–20.
13. Agarwal SS, Chopra SS, Kumar P, Jayan B, Nehra K, Sharma M. A radiographic study of external apical root resorption in patients treated with single-phase fixed orthodontic therapy. *Med J Armed Forces India.* 2016;72(Suppl 1):S8–16.
14. Weltman B, Vig KW, Fields HW, Shanker S, Kaizar EE. Root resorption associated with orthodontic tooth movement: a systematic review. *Am J Orthod Dentofacial Orthop.* 2010;137(4):462–76.
15. Mavragani M, Bøe OE, Wisth PJ, Selvig KA. Changes in root length during orthodontic treatment: advantages for immature teeth. *Eur J Orthod.* 2002;24(1):91–7.
16. Levander E, Malmgren O. Long-term follow-up of maxillary incisors with sever apical root resorption. *The European Journal of Orthodontics.* 2000;22(1):85–92.

Cite this article: Attarde P, Vishnupriya TR, Kiran Kumar HC. A comparative evaluation of relationship between Collum angle and root resorption of maxillary central incisors in Class I and Class II Division 2 malocclusion following non-extraction orthodontic treatment - A radiographic study. *J Pierre Fauchard Acad.* 2025;39(1):9-13