

Case Report

Small Cell Neuroendocrine Carcinoma of Bartholin's Gland: A Case Report

^{*1}Medyouni Hajar, ¹Chouef Jihane, ¹Siyouri Oumaima, ¹El Hakym Samia, ²Mhirech Samia, ¹Amaadour Lamiae, ¹Oualla Karima, ¹Benbrahim Zineb, ¹Arifi Samia, ¹Mellas Nawfel

¹Medical Oncology Department, Chu Hassan II, Fes, Morocco

²Radiotherapy Department, Chu Hassan II, Fes, Morocco

*Corresponding Author Email: hajarmedyouunifmpf@gmail.com

Received: February 03, 2024

Accepted: March 10, 2024

Published: March 18, 2024

Abstract

Small cell carcinoma (SCC) is a rare tumor predominantly found in the lungs, with only 5% occurring outside the pulmonary system. Despite its common occurrence in the cervix, SCC can also develop in the ovaries, endometrium, vagina, and vulva. Primary carcinoma of the Bartholin's gland (BGC) represents a minute fraction of gynecological cancers, often presenting diagnostic challenges due to its deep-seated location. We present the case of a 43-year-old menopausal patient with familial cancer predisposition. She presented with a localized mass in the right Bartholin's gland and underwent excision surgery. Histological analysis confirmed a highly aggressive neuroendocrine carcinoma morphologically consistent with small cell neuroendocrine carcinoma. The patient underwent radiochemotherapy with cisplatin and etoposide, followed by pelvic and inguinal radiotherapy and vulvar brachytherapy. Imaging revealed metastatic lymph node dissemination, necessitating aggressive treatment. In conclusion, SCC of the BG is a rare and aggressive malignancy requiring multidisciplinary management for optimal outcomes. Further research is needed to establish standardized treatment protocols and improve prognosis.

Keywords: Small Cell Carcinoma, Bartholin's Gland Carcinoma, Neuroendocrine Carcinoma, Radiochemotherapy.

Introduction

Small cell carcinoma is a rare tumor that most commonly occurs in the lungs. Only 5% of cases occur outside the lungs. Regarding the female genital tract, cervical involvement is the most common; however, small cell carcinoma can develop in the ovary, endometrium, vagina, and vulva. Primary carcinoma of the Bartholin's gland (BGC) is an extremely rare malignancy accounting for <5% of all vulvar malignancies and representing 0.001% of gynecological cancers in the United States [1, 2]. Regardless of the location, small cell carcinoma is a highly aggressive tumor with a grave prognosis due to early systemic metastases, even for low-grade tumors.

Case Report

This concerns a 43-year-old patient, menopausal, with a history of intermittent asthma and childhood seizures, G2P0. The patient had a noteworthy obstetric history marked by two miscarriages, one of which necessitated an aspiration procedure. Ovarian dystrophy with elevated prolactin levels, with a maternal aunt diagnosed with breast cancer at the age of 54 and a paternal cousin undergoing treatment for stomach cancer around the age of 30. She presents with a localized mass in the right Bartholin's gland since the end of June 2022 and underwent excision surgery on 09/02/2023.

Histology and Immunohistochemistry (Figure 1)

The specimen measures 4 x 3.5 x 2 cm. The material shows massive infiltration by an organized tumor proliferation arranged in voluminous masses, separated by sparsely vascularized conjunctive septa, mildly inflammatory. The tumor cells are relatively monomorphic, small to medium-sized, with a high nucleocytoplasmic ratio. The cytoplasm is faintly visible and basophilic. The nuclei are elongated, with dusty chromatin, often lacking visible nucleoli. Mitoses are frequent, with areas of tumor necrosis. The neuroendocrine nature of the tumor proliferation is confirmed by the expression of chromogranin A,

synaptophysin, and INSM1. The Ki-67 index is evaluated at 80%. Further immunohistochemical study was performed to rule out differential diagnoses. There is no expression of OCT3/4, which could suggest a germ cell tumor. Absence of CK20, neurofilaments, and SATB2 expression, which could suggest Merkel cell carcinoma. No expression of neuroectodermal markers, CD99, PhoxB2, and NKX2. No expression of androgen receptors or NKX3.1. The expression of muscle markers (desmin, myogenin, myo-D1) is undetectable. In our study, we did not find the presence of malpighian markers (p40, p63), and the expression of SMARCA4 and SMARCB1 proteins is conserved.

Conclusion

In this study we have observed a vulvar localization of a neuroendocrine carcinoma (18 mitoses/2 mm² and Ki-67 80%), morphologically favoring small cell neuroendocrine carcinoma and presence of perineural invasion and emboli. A review at a specialized center confirmed a poorly differentiated neuroendocrine neoplasm with high histological grade.

MS Classification

Small Cell Type Neuroendocrine Carcinoma: The case was discussed in the rare gynecological tumor double reading network, which proposed the same diagnosis. Abdominopelvic MRI performed on 07/03/2023: Right inguinal and external iliac lymphadenopathies. No other suspicious abdominopelvic lesions indicative of distant dissemination.

PET Scan on 07/03/2023: Right inguinal, obturator, and external iliac metastatic lymph node dissemination. Right vulvar and paravulvar uptake interpretation is complicated due to recent surgery: persistent neoplastic disease versus inflammatory changes. No other focal hypermetabolic lesions suspicious of neoplastic origin.

Gynecology Committee on 07/03/2023: Indication for concurrent radiochemotherapy with cisplatin and etoposide. Pelvic and inguinal radiotherapy at a dose of 45 Gy with an integrated boost on suspicious lymph nodes followed by vulvar brachytherapy if possible, otherwise radiotherapy boost. Treatment may begin with two cycles of cisplatin and etoposide chemotherapy before initiating concurrent radiochemotherapy. C1 cisplatin and etoposide performed on March 22, 2023. Start of radiotherapy at C3 from May 4, 2023. C4 received on May 25. End of radiotherapy on 06/06/2023. Reevaluation MRI on 26/05: Shows T2 hypersignal suspect of right-sided small lip tumor formation, periurethral, compatible with clinical examination with a nodular formation at 7 o'clock. The disease responds at the lymph node level. In our study the patient received a vaginal and interstitial brachytherapy for a better therapeutic index and a continued cisplatin plus etoposide chemotherapy for a total of 8 cycles with concurrent chemotherapy during brachytherapy. End of brachytherapy on July 5, 2023. The patient received last chemotherapy on July 6, 2023. The patient is under surveillance with imaging control every 3 months since July 2023. The patient developed peripheral axonal neuropathy related to cisplatin. The diagnosis of radiculalgia was considered in October following episodes of lower limb pain. Imaging revealed minimal L5-S1 disc protrusion without conflict. She does not complain of radicular pain but describes difficulties related to peripheral neuropathy with pain affecting all four limbs at the extremities, mainly neuropathic pain, and balance disturbances. There is no motor deficit. Our patient's clinical examination revealed: No evidence for radiculalgia. Negative Lasègue's sign. No low back pain today. Absence of osteotendinous reflexes. Proprioceptive impairment sign with unstable gait and non-lateralized Romberg's sign.

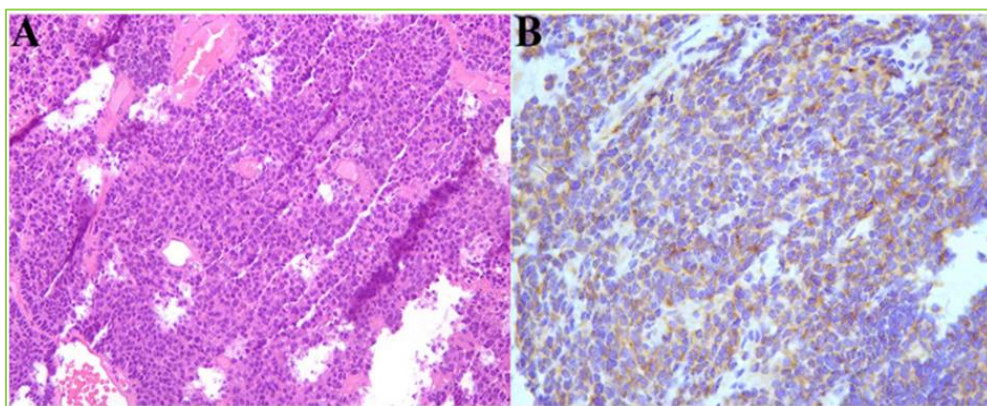


Figure 1: A low-power view of the tumor biopsy under a light microscope. (A) Hematoxylin and eosin staining. (B) Chromogranin staining. In total, ~50% of the tumor cells are positive (magnification, ×20).

Discussion

SCNC of the BG is often diagnosed late since the lesions are deep within the vulva and present with similar symptoms to most vulvar diseases, including abscesses or cysts [5]. A foreign language literature search was not performed. Due to the potentially aggressive behavior of SCNC, prompt diagnosis is required [8]. However, SCNC of the BG is often diagnosed late since the lesions are deep within the vulva and present with similar symptoms to most vulvar diseases, including abscesses or cysts [5]. Patients usually complain of pain, swelling on the vulva, dyspareunia and bleeding [6, 7]. In cases where BGC is suspected, the clinical diagnostic criteria is as follows: The tumor must be primarily located in the BG area; the surrounding skin must be undamaged; areas of apparent transition from normal to neoplastic elements must be observed; the histological tumor type must be consistent with the BG origin; there must be no evidence of a previous or subsequent primary tumor of similar histologic type elsewhere [8, 12].

Di Donato et al. [4] collected all published manuscripts regarding BGC and the median age of patients was 52.99 ± 13.94 years. Therefore, independent of whether a patient is pre-or post-menopausal, every mass within the BG area should be considered as a potential carcinoma until proven to be benign with biopsies of adequate size and depth [3, 9]. Diagnosis of BGC is established based upon histological examination. Abundant apoptotic debris and mitotic figures may be seen in SCNC of BG, and immunohistochemical stains were strongly positive for CAM 5.2, NSE, SYN, CHG, CD56 and CD10 [4, 10, 11]. There is presently no consensus on the treatment of BGC due to the lack of randomized controlled trials and large cases in the literature. The treatment of BGC may include extensive vulvar surgery, and inguinal and pelvic lymphadenectomy, similar to treatment of SCC of the vulva. SCNC is a subtype of neuroendocrine cancer, resembling small cell carcinoma of the lung [12]. It has a poor prognosis and the use of cisplatin and etoposide is recommended as in small cell pulmonary tumors [13, 14].

Conclusion

Small cell carcinoma (SCC) of the Bartholin's gland (BG) represents a rare and aggressive malignancy with significant diagnostic and therapeutic challenges. Despite its rarity, prompt diagnosis and aggressive multidisciplinary management are essential for optimizing patient outcomes. Treatment modalities including surgery, radiotherapy, and chemotherapy mirror those used for small cell lung carcinoma, underscoring the importance of a comprehensive approach.

Further research is needed to elucidate optimal treatment strategies and improve prognosis for patients with SCC of the BG. Additionally, enhanced awareness among healthcare providers regarding the clinical presentation and diagnostic workup of this rare malignancy is crucial for early detection and timely intervention.

Declarations

Acknowledgments: I would like to extend my sincere thanks to all the participants involved in this study. Additionally, I am grateful to my university and my department for the support and resources provided. Special appreciation goes to my colleagues and friends for their valuable insights and collaboration. Without your contributions, this article would not have been possible. Thank you all for your dedication and support.

Author Contributions: All authors contributed equally.

Conflict of Interest: The authors declare that they have no competing interests.

Consent to Publish: The authors agree to publish the paper in African Journal of Medicine and Pharma Research.

Data Availability Statement: The data presented in this study are available upon request from the corresponding author.

Funding: This research received no external funding.

Institutional Review Board Statement: No ethics committee approval is required at our institution for a case report involving a limited number of patients.

Informed Consent Statement: Informed consent was obtained from all subjects involved in this study.

Research Content: The research content of manuscript is original and has not been published elsewhere.

References

1. DePasquale SE, McGuinness TB, Mangan CE, Husson M, Woodland MB. Adenoid cystic carcinoma of Bartholin's gland: a review of the literature and report of a patient. *Gynecol Oncol.* 1996;61(1):122-5.
2. Nasu K, Kawano Y, Takai N, Kashima K, Miyakawa I. Adenoid cystic carcinoma of Bartholin's gland: case report with review of the literature. *Gynecol Obstet Invest.* 2005;59(1):54-58.

3. Ouldamer L, Chraibi Z, Arbion F, Barillot I, Body G. Bartholin's gland carcinoma: epidemiology and therapeutic management. *Surg Oncol*. 2013;22(2):117-22.
4. Di Donato V, Casorelli A, Bardhi E, Vena F, Marchetti C, Muzii L, Panici PB. Bartholin gland cancer. *Crit Rev Oncol Hematol*. 2017;117:1-11.
5. Khoury-Collado F, Elliott KS, Lee YC, Chen PC, Abulafia O. Merkel cell carcinoma of the Bartholin's gland. *Gynecol Oncol*. 2005;97(3):928-31.
6. Bhalwal AB, Nick AM, Dos Reis R, Chen CL, Munsell MF, Ramalingam P, Salcedo MP, Ramirez PT, Sood AK, Schmeler KM. Carcinoma of the Bartholin gland: a review of 33 cases. *Int J Gynecol Cancer*. 2016;26(4):785-789.
7. Yang SY, Lee JW, Kim WS, Jung KL, Lee SJ, Lee JH, Bae DS, Kim BG. Adenoid cystic carcinoma of the Bartholin's gland: report of two cases and review of the literature. *Gynecol Oncol*. 2006;100(2):422-425.
8. Copeland LJ, Sneige N, Gershenson DM, Saul PB, Stringer CA, Seski JC. Adenoid cystic carcinoma of Bartholin gland. *Obstet Gynecol*. 1986;67(1):115-20.
9. Lee MY, Dalpiaz A, Schwamb R, Miao Y, Waltzer W, Khan A. Clinical pathology of Bartholin's glands: a review of the literature. *Curr Urol*. 2015;8(1):22-25.
10. Rosén C, Malmström H. Invasive cancer of the vulva. *Gynecol Oncol*. 1997;65(2):213-217.
11. Groben P, Reddick R, Askin F. The pathologic spectrum of small cell carcinoma of the cervix. *Int J Gynecol Pathol*. 1985;4(1):42-57.
12. González-Bugatto F, Añón-Requena MJ, López-Guerrero MA, Báez-Perea JM, Bartha JL, Hervías-Vivancos B. Vulvar leiomyosarcoma in Bartholin's gland area: a case report and literature review. *Arch Gynecol Obstet*. 2009;279:171-174.
13. Dakhil CS, Wick JA, Kumar AK, Satyan MT, Neupane P. Extrapulmonary small cell carcinoma: the University of Kansas experience and review of literature. *Med Oncol*. 2014;31:1872014.
14. Yildirim Y, Elagoz S, Koyuncu A, Aydin C, Karadayi K. Management of neuroendocrine carcinomas of the breast: a rare entity. *Oncol Lett*. 2011;2(5):887-90.

Citation: Hajar M, Jihane C, Oumaima S, Samia EH, Samia M, Lamiae A, Karima O, Zineb B, Samia A, Nawfel M. Small Cell Neuroendocrine Carcinoma of Bartholin's Gland: A Case Report. *Afr J Med Pharm Res*. 2024;2(1):1-4.

Copyright: ©2024 Hajar M, et al. This is an open-access article distributed under the terms of the Creative Commons Attribution License (<https://creativecommons.org/licenses/by/4.0/>), which permits unrestricted use, distribution, and reproduction in any medium, provided the original author and source are credited.