

Case Report

Management of Dental Anterior Open Bite Treated by Combination of Orthodontics and Cosmetic Dentistry: A 2 Years Follow Up Case Report

¹Sharmin Sultana, ²Mohammad Zakir Hossain, ³Amit Bhardwaj

To cite: Sultana S, Hossain Mohd. Z, Bhardwaj A. Management of Dental Anterior Open Bite Treated by Combination of Orthodontics and Cosmetic Dentistry: A 2 Years Follow Up Case Report. J Contemp Orthod 2018;2(3): 27-32.

Received on:
25-07-2018

Accepted on:
16-08-2018

Source of Support: Nil

Conflict of Interest: None

¹PhD candidate, ²Ex-Professor and Head, ³Professor and Head
¹Orthodontic Unit, ^{2,3}Department of Orthodontics and Dentofacial Orthopedics
¹School of Dental Sciences, Health Campus, University Sains Malaysia, Kubang Kerian, Kelantan, Malaysia.
²Dhaka Dental College and Hospital, Mirpur, Dhaka, Bangladesh.
³Modern Dental College and Research Center, Gandhinagar, Airport Road, Indore, Madhya Pradesh, India

ABSTRACT

Dental anterior open bite associated with decreased incisor dentoalveolar height. The occlusal planes in the dental anterior open bite usually diverge from the mesial to the first premolar forward. The outcome of this case report describe a notable treatment of dental anterior open bite. Here a male patient aged 22 years presented 4.2 mm anterior open bite along with increased lower anterior facial height. Other features are as follows - competent lip, deficient incisor display during rest and smile, fractured enamel of both upper central incisors. Treatment was carried out by extrusion of both upper and lower incisors with camouflage non-extraction therapy followed by composite buildup of fractured upper central incisors. There was no recurrence of anterior open bite, and balanced occlusion was maintained during the follow up of next 2 years after treatment completion which suggest a long term stability of occlusion.

Key words: Dental anterior open bite, Camouflage non-extraction, Fixed orthodontic appliances.

INTRODUCTION

Anterior open bite (AOB) is herein defined as a vertical gap between the maxillary and mandibular incisor teeth in centric relation.¹ Dental anterior open bite associated with decreased incisor dentoalveolar height, normal or less anterior and posterior vertical dimension, competent lip, deficient incisor display at rest and smile and occlusal plane diverge from the mesial to the first premolar teeth forward.^{2,3} Hypodivergent subjects display a decreased dentoalveolar heights as compared to the normodivergent subjects.^{4,5} Several etiologies for an open-bite have been suggested, including unfavorable growth patterns, heredity, digital habits, and tongue function.⁶ Dental anterior open bite can be possible to treat in various way such as extrusion of both upper and lower incisor teeth, multibrackets in conjunction with high-pull headgear therapy to intrude 1st molar teeth, temporary skeletal anchorage device to intrude molar teeth, 2nd premolar extraction therapy facilitates the closure of anterior open bite by inducing a counterclockwise mandibular rotation without molar intrusion, multiple-loop

edgewise archwire (MEAW) therapy in conjunction with vertical elastic.^{3,5,7,8}

This is a case report of anterior open bite revealed a fruitful treatment outcome done by extrusion of both maxillary and mandibular front teeth by using vertical elastics with camouflage non-extraction therapy followed by composite buildup of fracture enamel of upper central incisor teeth.

CASE HISTORY AND DIAGNOSIS

A 22 years old male came to the Orthodontic Department of Dhaka Dental College and Hospital, Bangladesh, for Orthodontic treatment with chief complains of upper and lower anterior teeth not meeting together along with slightly broken upper front teeth. Extraoral clinical examination indicated convex face profile with competent lip, slight increased lower anterior face height, deficient incisor display at rest and smile (**Figure 1**). Intraoral examination revealed 4.2 mm anterior open bite without overlapping of upper and lower anterior teeth with class II molar and canine relationship in right side and

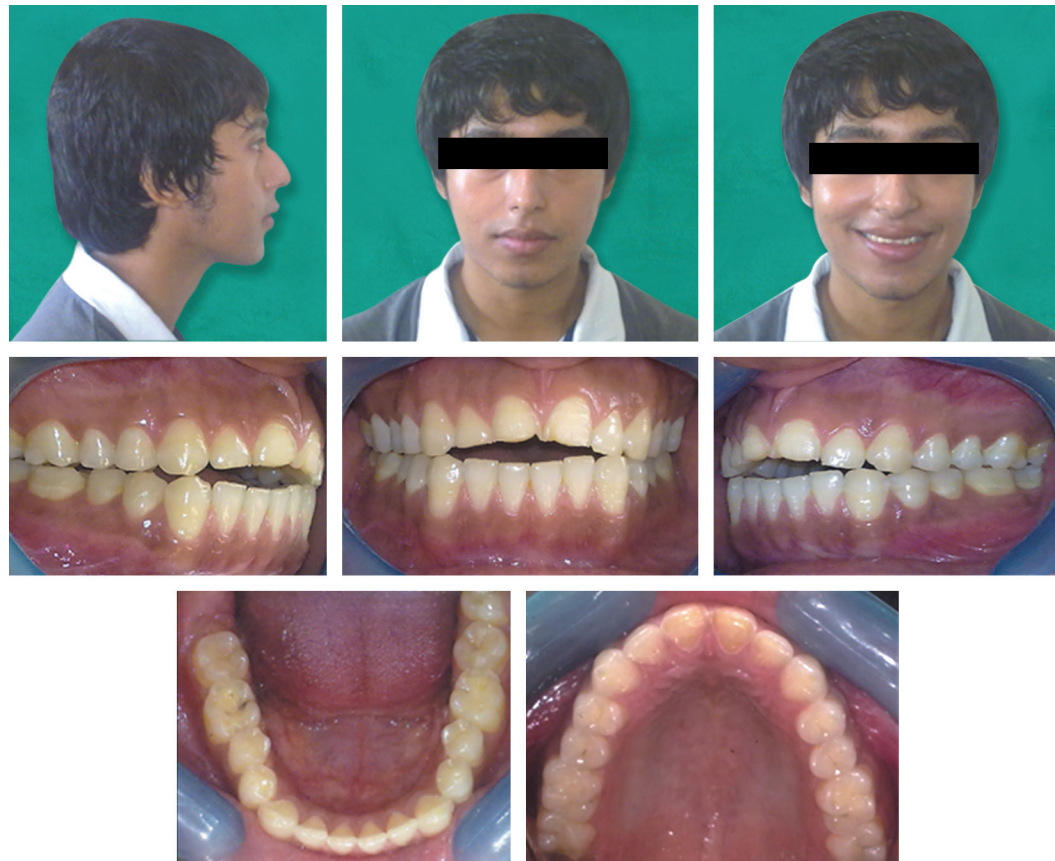

Figure 1 Pretreatment facial and intraoral photos

class I molar and canine relationship in left side. Patient also have fracture enamel on upper both central incisor (**Figure 1**).

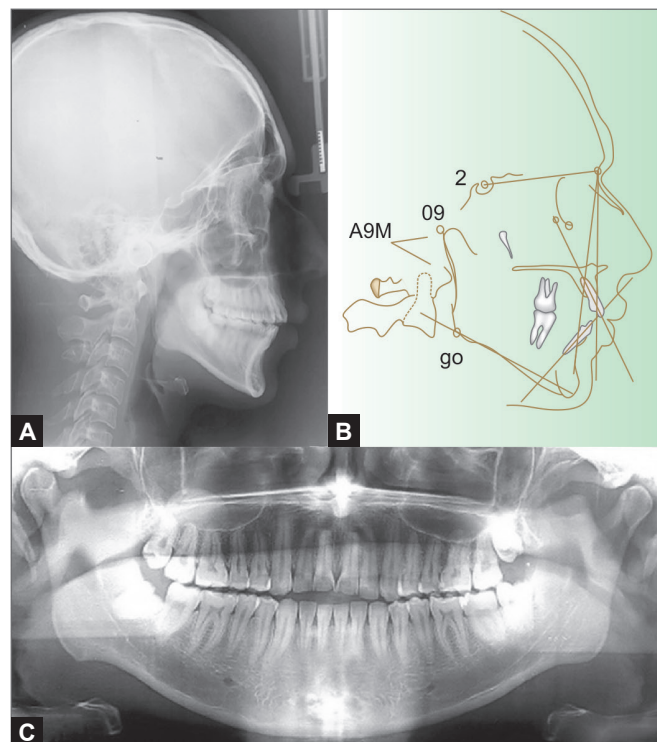
Examination of panoramic radiograph showed permanent dentition with all teeth present including the third molars in all quadrants. The lateral cephalometric radiograph revealed average growth of maxilla (SNA: 81°), retrognathic mandible (SNB: 75°), skeletal Class II malocclusion (ANB: 6°), and slight vertical growth pattern (MPA: 34.4°). Upper anterior dentoalveolar height (UADH) was 20.3mm and lower anterior dentoalveolar height (LADH) was 33mm, which was reduced from normal value and indicated the key finding that this case was a dental anterior open bite malocclusion (**Figure 2**).

TREATMENT OBJECTIVES

The initial treatment objectives were (1) To improve the anterior open bite with ideal overjet and overbite, (2) To establish an acceptable functional occlusion (3) Composite buildup to improve fracture incisal edge, (4) Improve aesthetic smile.

TREATMENT ALTERNATIVES

There are various factors cognate to AOB malocclusion, and the treatment is challenging in orthodontics. First the patient



Figures 2A to C (A) Pretreatment lateral cephalogram, (B) Panoramic radiograph and (C) Cephalometric tracing

ought to be diagnosed properly so that the stability and retention can be maintained after completion of treatment. The first treatment alternative would be intrusion of the posterior teeth by placing temporary anchorage devices, which is also a method to treat skeletal AOB in non-growing patients. Second alternative could be retraction and vertical repositioning of the maxillary and mandibular anterior teeth by extraction of the premolars, and extrusion of the anterior segment with elastics in growing patient. Third alternative could be orthognathic surgery if the AOB is associated with skeletal discrepancies.

TREATMENT MECHANICS AND PROGRESS

Considering all aspects of the case in detail, non extraction camouflage treatment plan was established and started with fixed orthodontic appliance. 0.014" nickel-titanium archwire was used for initial leveling and alignment of the maxillary and mandibular dental arch, using the 0.018" slot standard edgewise braces. After 3 months of consecutive visit, simultaneous extrusion of both maxillary and mandibular anterior teeth was achieved by using a 0.016" ss round archwire along with vertical box elastic. Class III elastics with triangular shape was used to prevent molar extrusion during simultaneous extrusion of both maxillary and mandibular anterior teeth (**Figure 3**). After 6 months period final dental occlusal settling were performed and the total orthodontic treatment period was approximately 11 months. On debonding day composite buildup were performed to improve aesthetic of fracture enamel of upper central incisal edge.

RESULT

The post-treatment facial photograph showed a dramatic change in smiling view of the patient, more upper incisor teeth

were visible and upper lip rested on gingival margin during smiling. Intraoral photograph showed acceptable occlusion with improved overbite of 3 mm and the overjet of 4 mm (**Figure 4**). The periodontal tissues remained healthy during and after active orthodontic treatment. There is evidence of mild root resorption was present in panoramic radiograph after active treatment, however root parallelism was satisfactory. Cephalometric evaluation showed that improved inter-incisal angle (IIA) and UADH (**Figure 5 and Table 1**).

After two years of retention, there was no relapse tendency of anterior open bite, However, a slight change of overjet and overbite which became 3 mm and 2 mm respectively. During this time acceptable occlusion, aesthetic facial and smile view was maintained. The outcome of this results indicated a long-term stability of the occlusion (**Figure 6**).

DISCUSSION

Looked with the confinement of orthodontic treatment in government hospital of Bangladesh, we decided to treat this patient by simultaneous extrusion of both maxillary and mandibular anterior teeth with standard edgewise fixed orthodontic appliance. However, patient also had reduced UADH and LADH indicated dental anterior open bite malocclusion. Therefore, UADH is considered as an important landmark of orthodontic treatment, in case patient has hypodivergent facial growth,^{4,5} and the extrusion of the maxillary incisors may be considered during the treatment instead of intrusion of molar teeth or surgical correction. Furthermore, anterior open bite is known as one of the severe occlusal traits and proper management depends on the severity of the skeletal discrepancies. The high relapse tendency of anterior open bite cases is approximately 20% whether it is corrected by surgical or nonsurgical.^{3,8} There is not obvious justification for this instability and the

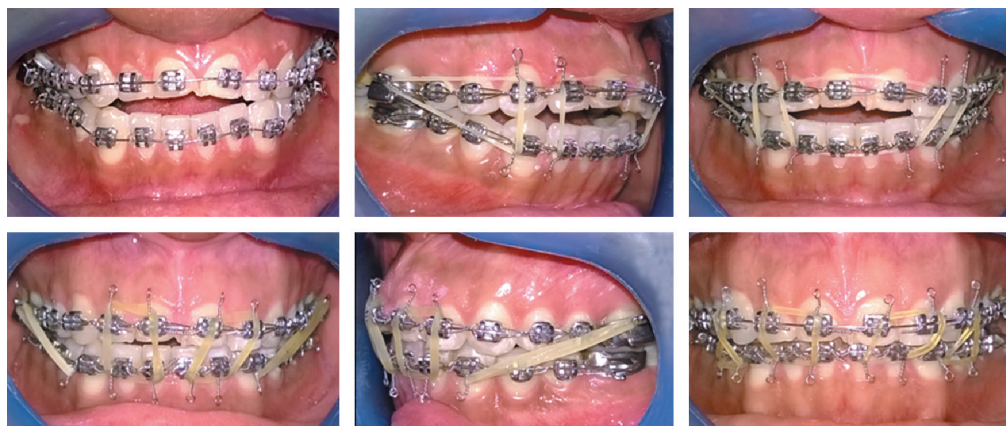
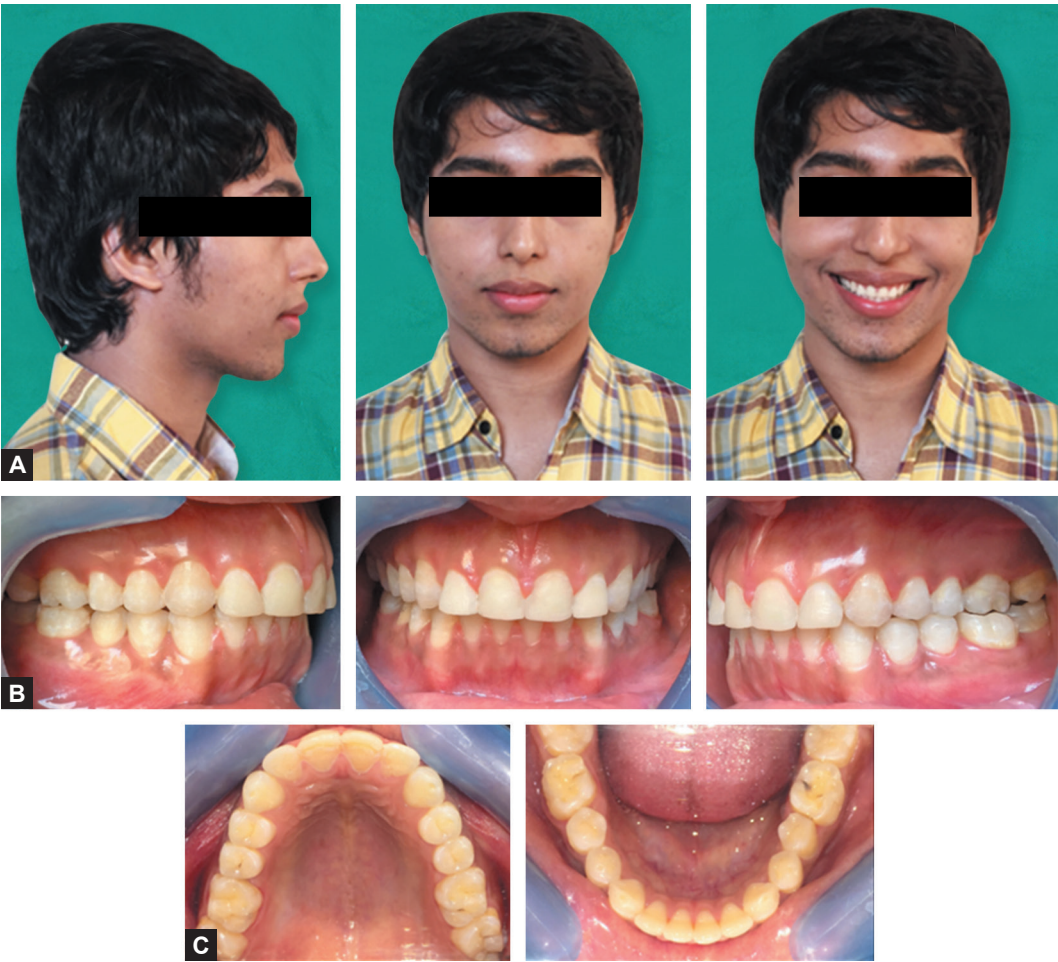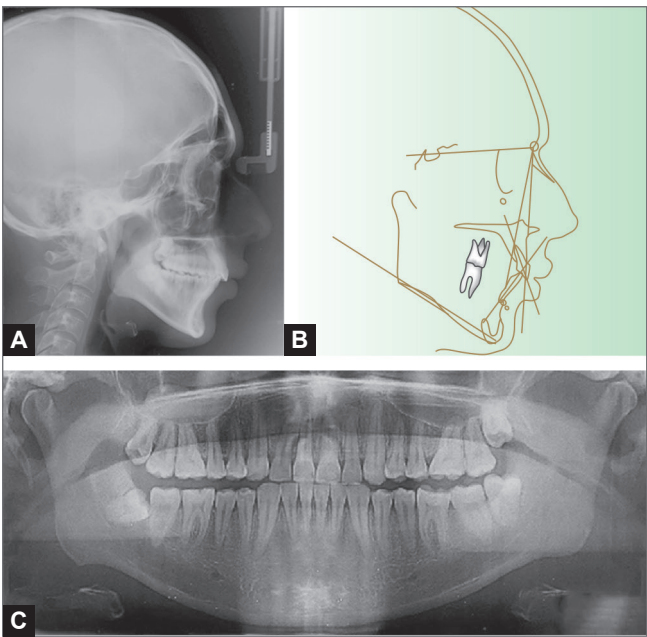


Figure 3 Progressive intra oral photograph



Figures 4A to C (A) Post-treatment facial; (B and C) Intraoral photos



Figures 5A to C (A) Post-treatment lateral cephalogram, (B) Cephalometric tracing (Immediately after debonding) and (C) Panoramic radiograph

Table 1
Cephalometric summary

Variables	Pre-treatment	Post-treatment
Angle (°)		
SNA	81	81
SNB	75	75
ANB	6	6
IIA	111	124
MPA	34.4	34
U1 to NA	23	22
L1 to NB	27	25
Liner (mm)		
UADH	20.3	24.3
LADH	33.2	38
U1 to NA	3.5	2
L1 to NB	7	7

*IIA (Inter incisal angle) *MPA (Mandibular plane angle) *UADH (Upper anterior dentoalveolar height) *LADH (Lower anterior dentoalveolar height).

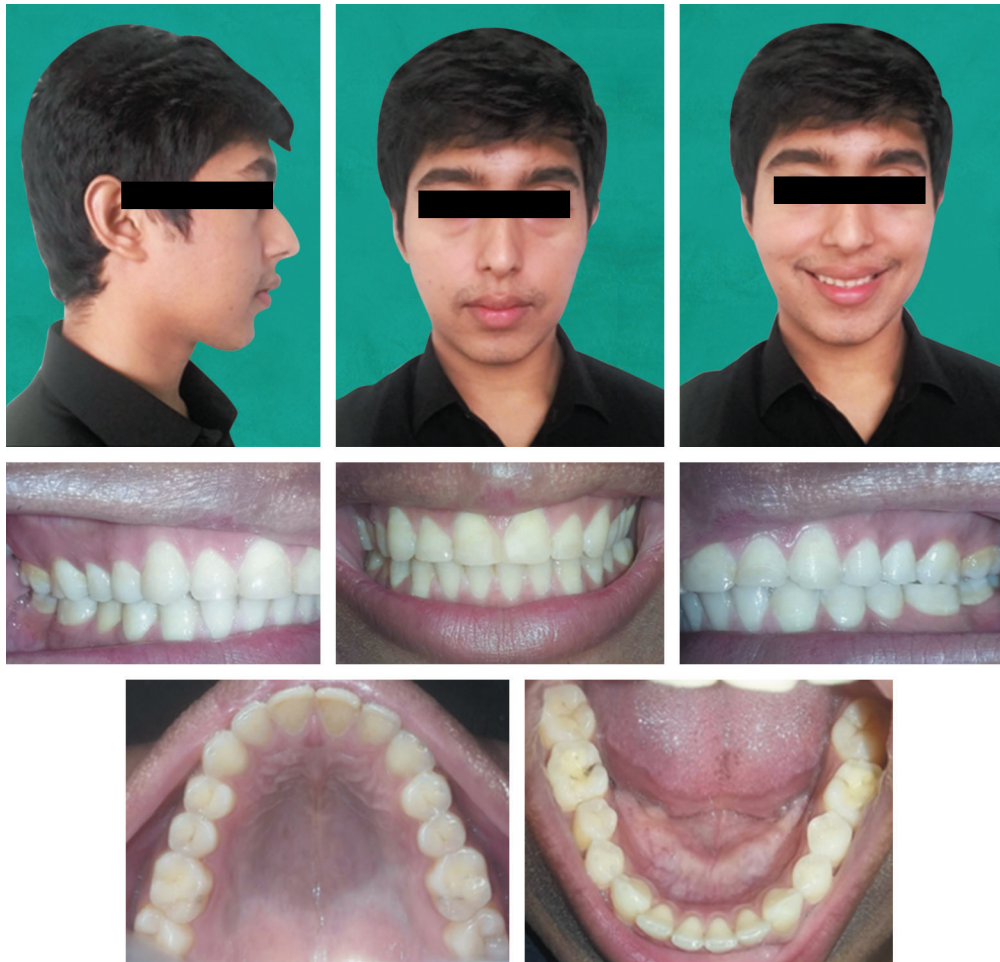

Figure 6 Extraoral and Intraoral photographs 2 years after treatment (longest follow-up)

complex interaction of all possible etiologic factors of the open bite cases. If the management does not address the possible etiologic factor, relapse is more prone to happen.⁹ Furthermore, overcorrection is highly recommended for this type of malocclusion and should incorporate upper and lower fixed retainers that include the first premolars as a retention of this malocclusion.

CONCLUSION

Considering UADH with simultaneous extrusion of both maxillary and mandibular front teeth is of abundant significance to achieve a stable functional occlusion. Combination of composite buildup with orthodontic treatment brings excellent smile and profile view. The steadiness of the results was kept up at the long duration follow-up periods.

Address for Correspondence

Sharmin Sultana
Universiti Sains Malaysia
Orthodontic Unit, School of Dental Sciences
Health Campus, International Hostel, Kubang Kerian
Kelantan, Malaysia.
E-mail: sharminkhulna@yahoo.com

REFERENCES

1. Artese A, Drummond S, Nascimento JM, et al. Criteria for diagnosing and treating anterior open bite with stability. *Dental Press J Orthod.* 2011;16(3):136-61.
2. Islam Z, Shaikh AJ, Fida M. Dentoalveolar heights in vertical and sagittal Facial Patterns. *J Coll Physicians Surg Pak.* 2016;26(9):753-7.
3. Nanda R. Biomechanics and esthetic strategies in clinical orthodontics. Elsevier Inc. 2005; pp. 156-75.

4. Janson GR, Metaxas A, Woodside DG. Variation in maxillary and mandibular molar and incisor vertical dimensions in 12-year old subjects with excess, normal and short lower anterior face height. *Am J Orthod Dentofacial Orthop.* 1994;106(4):409-18.
5. Shtelny J, Sakuda M. Open bite: Diagnosis and treatment. *Am J Orthod Dentofacial Orthop.* 1964;50:337-58.
6. Cal-Neto JP, Quintao CC, Menezes LM, et al. Severe Anterior Open-Bite Malocclusion Orthognathic Surgery or Several Years of Orthodontics? *Angle Ortho.* 2006;76(4):728-33.
7. Kuroda S, Katayama A, Yamamoto T. Severe Anterior Open-Bite Case Treated Using Titanium Screw Anchorage. *Angle Orthodo.* 2004;74(4):558-67.
8. Tanakaa E, Iwabeb T, Kawaic N, et al. An adult case of skeletal open bite with a large lower anterior facial height. *Angle Orthodo.* 2005;75(3):465-71.
9. Alexander CD. Open bite, dental alveolar protrusion, Class I malocclusion: a successful treatment result. *Am J Orthod Dentofacial Orthop.* 1999;116(5):494-500.