

Correction of Class II Division 2 Malocclusion by Fixed Functional Class II Corrector Appliance: Case Report

To cite: Kumar M, Sharma H, Bohara P. Correction of class II division 2 malocclusion by fixed functional class II corrector appliance: case report. *Journal of contemporary orthodontics*, February 2018, Vol 2, Issue 1 (page 54-60)

Received on: 03/01/2018

Accepted on: 29/01/2018

Source of Support: Nil

Conflict of Interest: None

Kumar M¹, Sharma H², Bohara P³, Mishra S⁴, Kushwah A⁵

¹Professor, Department of Orthodontics and Dentofacial Orthopaedics Teerthanker Mahaveer Dental College, Moradabad, Uttar Pradesh, India

²Professor, Department of Orthodontics and Dentofacial Orthopaedics Teerthanker Mahaveer Dental College, Moradabad, Uttar Pradesh, India

³Consultant Orthodontist

⁴Consultant Orthodontist

⁵Postgraduate student, Department of Orthodontics and Dentofacial Orthopaedics Teerthanker Mahaveer Dental College, Moradabad, Uttar Pradesh, India

ABSTRACT

This case report demonstrates the efficacy of fixed functional Class II corrector Powerscope™ in the correction of Class II division 2 malocclusion. A patient having Class II division 2 malocclusion with retruded mandible was treated using Preadjusted-Edgewise MBT 0.022" prescription and fixed functional class II corrector appliance Powerscope™. Pre, mid, post- treatment and one year post-treatment follow up photographs, orthopantomograms and lateral cephalograms were taken. Cephalometric analysis was done. 8 months of fixed functional Class II corrector appliance Powerscope™ wear obtained stable and successful results with improvement in facial profile, skeletal jaw relationship, and mild increase in IMPA. One year follow up record shows stable results achieved by fixed functional Class II corrector appliance Powerscope™.

Keywords: Powerscope™, Class II division 2 malocclusion, Fixed functional, Class II corrector appliance.

INTRODUCTION

The prevalence of malocclusion is greater in recent time as comparison to hundred years ago. The malocclusion can be dental, skeletal or both. On the basis of "Angle's postulate" malocclusion either be dental class I, class II or class III and skeletal malocclusion decided by maxillary and mandibular bone size and position. A dental and skeletal Class II malocclusion is most challenging malocclusion in sagittal plane which generally occur due to retrognathism of mandible as compare to maxillary prognathism.¹ Weiland and Droschi found that about 37% of malocclusions are Class II.²

For the correction of retruded mandible removable and fixed functional appliances are a choice of treatment in early and late growing stage. Patient within adolescent growth spurt stage can be treated by removable functional appliance like Activator, Bionator, Twin block, Franckel and in pubertal growth spurt stage or late pubertal stage fixed functional appliance such as Herbst, Jasper jumper, Mandibular anterior repositioning

appliance (MARA), Eureka springs, etc. are used for treatment which also categorized in Intermaxillary Noncompliance Appliance.³ Fixed functional appliances are reported to correct Class II skeletal problems by enhancing mandibular growth and by eliciting dentoalveolar effects.⁴

This case report present a nonextraction treatment approach for correction of skeletal class II relationship of maxillary and mandibular arch with the help of fixed functional class II corrector Powerscope appliance.

DIAGNOSIS

A 14-year-old adolescent female patient reported with the chief complaint of two forwardly placed teeth in upper front region. Extra oral examination revealed that she has mesoprosopic facial form, mesocephalic head shape, acute nasolabial angle, competent lips, convex facial profile with retrusive mandible, posterior facial divergence, normal mandibular plane and average clinical FMA (Fig. 1). Intraoral examination revealed

Class II division 2 malocclusion, with overjet of 3 mm and overbite of 5 mm, retroclination IRT upper 11, 21, rotations in relation to 12, 22.

The lateral cephalometric tracing showed a skeletal relationship slightly towards Class II relation with a horizontal growth pattern. The upper central incisors were retroclined

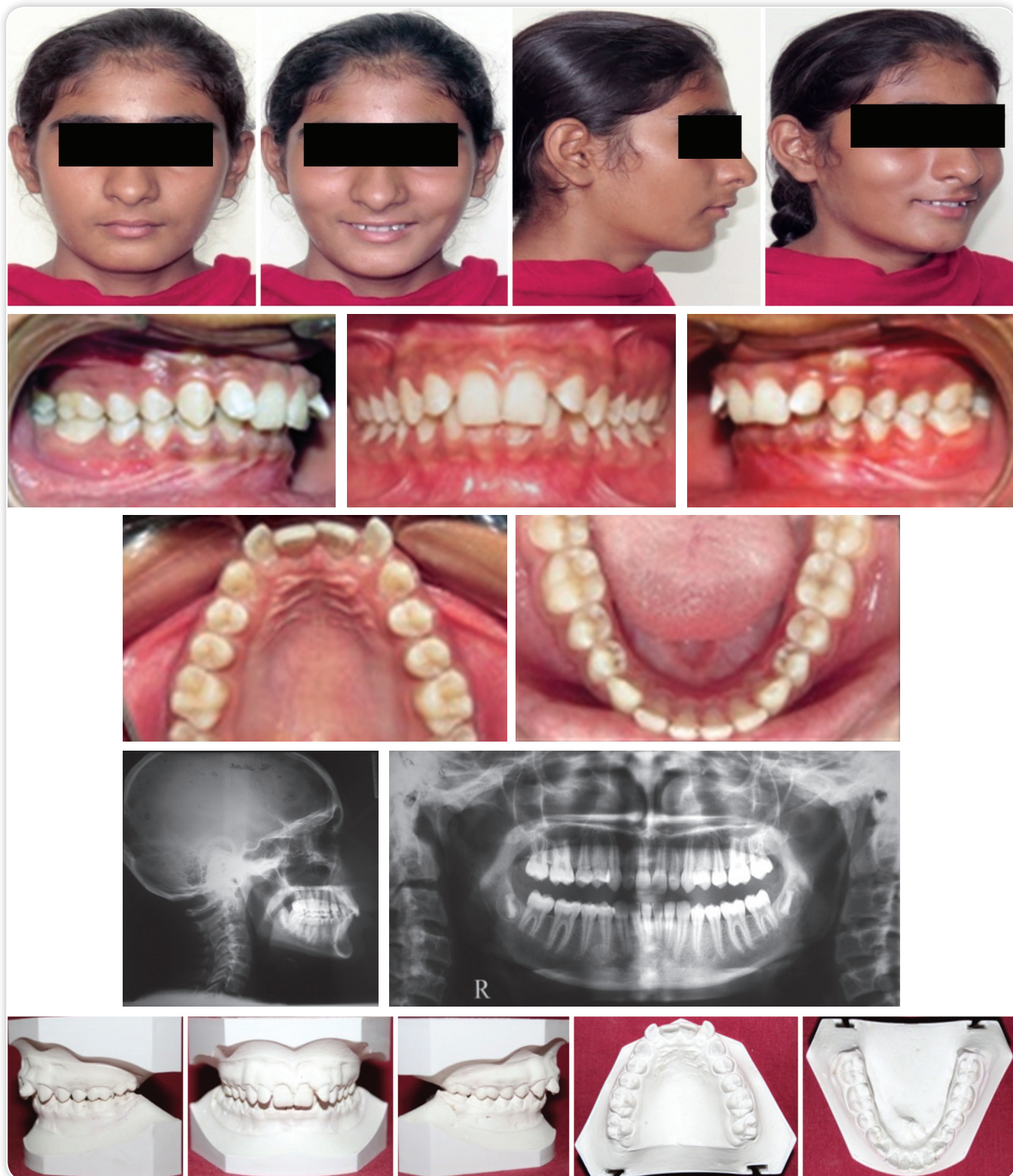

Figure 1 Pretreatment

and upper lateral incisors were proclined with rotation while the lower incisors were properly inclined. The panoramic radiograph revealed proportional condylar structures and the presence of all permanent teeth.

TREATMENT PLAN

Treatment goals were to correct the patient's skeletal and dental relationships and achieve balanced soft-tissue profile. Three treatment modalities were discussed. First, all first premolar extraction or secondly, upper first premolar and lower second premolar extraction followed by finishing the case in ideal Class I molar and canine relation. Thirdly, the use of fixed functional appliance to address the skeletal problem and best utilized remaining growth potential of the patient for her own benefit.

TREATMENT PROGRESS AND RESULTS

Full fixed preadjusted Edgewise appliance MBT 0.022" prescription were placed to level and align both arches. After achieving the leveling and alignment within seven months and transpalatal arch placed in maxillary arch for reinforcement of anchorage. 0.019" × 0.025" stainless steel archwires were inserted after figure of eight ligation from first molar to first molar in both arches. 10° of lingual crown torque was given in

lower anteriors. A fixed functional Class II corrector appliance, the Powerscope™, was placed with equal activation on both side to correct the mandibular retrognathism and achieve Class I relation (Fig. 2). Because it is worn full-time, it does not depend on patient compliance.

After eight months, the Powerscope appliance was removed and OPG and lateral cephalogram taken to check skeletal improvement (Fig. 3) and lighter. 016" stainless steel archwires were inserted, along with vertical elastics.

After 18 months of active treatment, skeletal and dental Class I relationships had been attained, and the fixed appliances were removed (Fig. 4). The patient's facial profile was orthognathic because of the soft-tissue modifications and the mandibular advancement. The lower incisors were slightly proclined, while the upper incisors were upright.

Cephalometric superimpositions showed that mandibular and maxillary growth had occurred during orthodontic treatment (Fig. 5, Table 1). Significant improvement was observed in the patient's dental and soft tissue esthetics, achievement of ideal overbite and overjet.

One year follow up record shown stable skeletal, dental and soft tissue esthetics and maintained overjet and overbite which achieved by fixed functional Class II corrector appliance POWERSCOPE™ (Fig. 6).

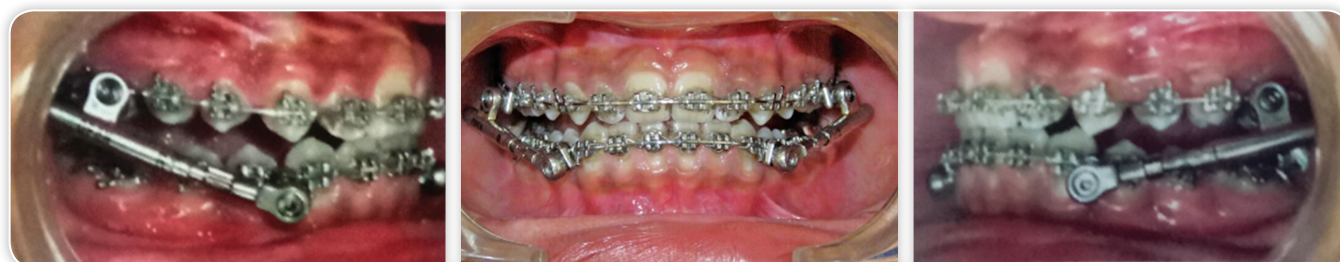

Figure 2 Installation of Powerscope for correction of class II relation

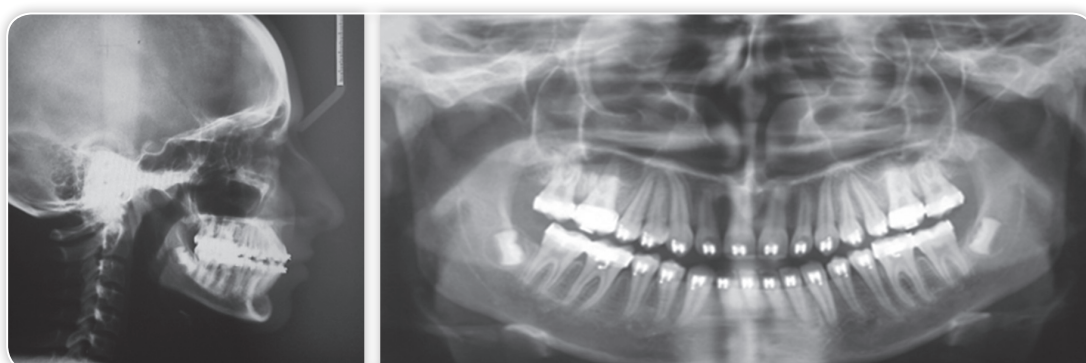

Figure 3 Mid treatment

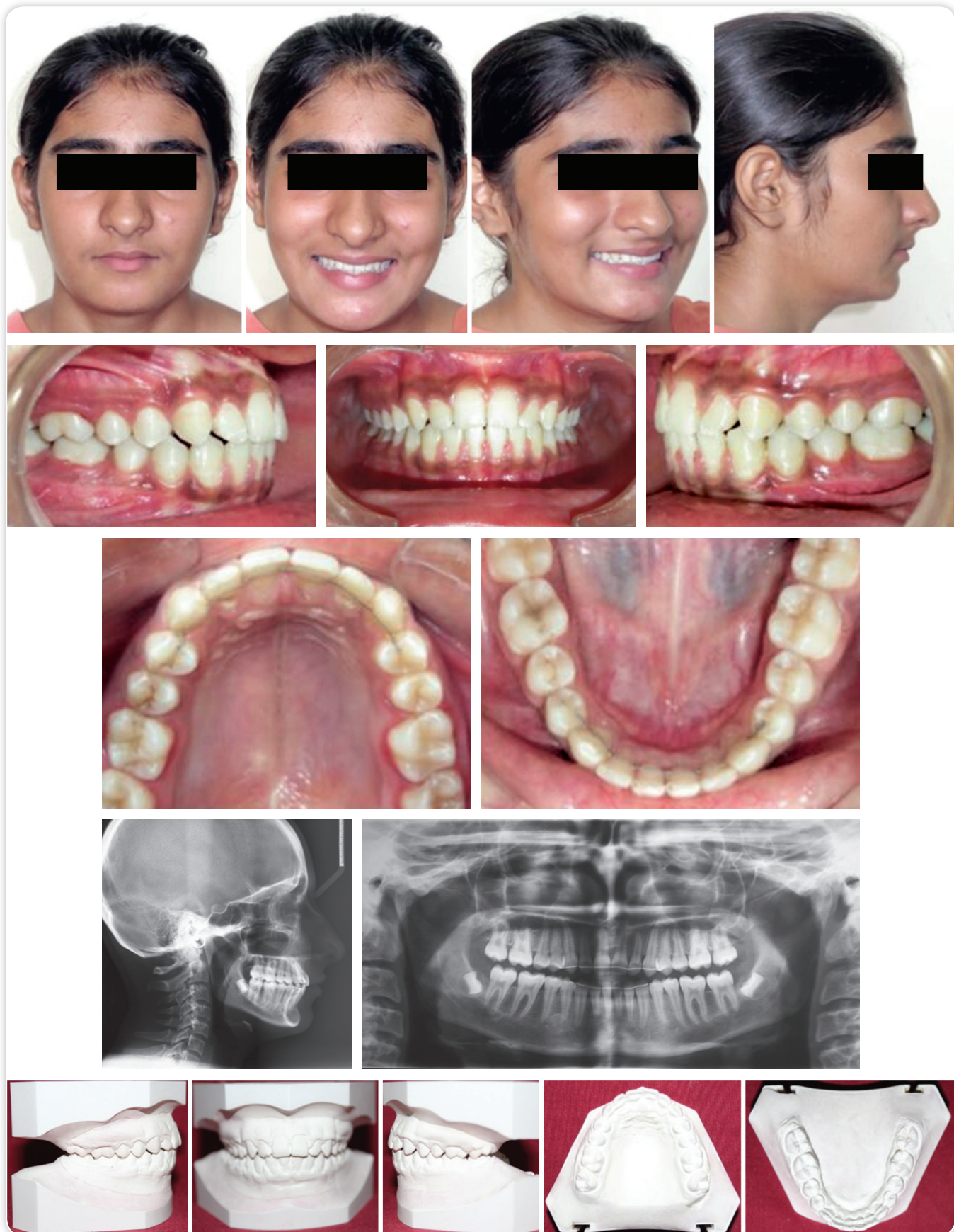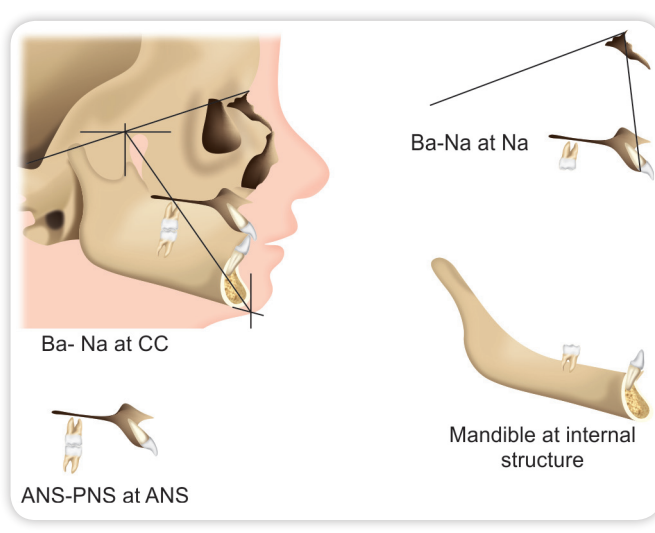


Figure 4 Post-treatment

Table 1

Cephalometric readings of the patient's lateral cephalograms tracing

	Cephalometric data				
	Norm	Pre treatment	Mid treatment	Post treatment	One year follow up
SNA	82°	77.1°	76.6°	77.1°	76.9°
SNB	80°	72.9°	73.7°	74.8°	74.3°
ANB	2°	4.2°	2.9°	2.3°	2.6°
SN-GoGn	32°	31.4°	30.5°	30.6°	30.9°
1/NA	22°	14.6°	27.9°	26.8°	27.3°
1-NA	4.0 mm	1.8 mm	2.9 mm	2 mm	2.8 mm
1/NB	25°	26.3°	27.5°	26.8°	27.1°
1-NB	4.0 mm	4.8 mm	5 mm	3.8 mm	4.4 mm
1/1	131°	134.9°	123.2°	125.2°	124.2°
IMPA	90°	98.7°	100°	99.2°	101°

**Figure 5** Superimposition

DISCUSSION

Noncompliance approaches are an important treatment option for management of skeletal class II malocclusion patient with minimal patient compliance. In old days, headgears and functional appliance used in which patient compliance played an important role to achieve desirable result. Nowadays, we have many noncompliance appliances which are less dependent on patient and correct class II malocclusion by advancing the mandible.³

Siara-Olds NJ et al. found that the MARA group shown temporary maxillary growth restriction and Twin block and Herbst groups shown more increase in SNB when compared

with the Bionator and MARA groups. The Twin block group expressed better vertical dimension control but had significant flaring of the lower incisors.⁵

In this case, powerscope used for correction of class II malocclusion by utilizing remaining growth. Powerscope facilitate the forward and downward displacement of the mandible. They also cause a some amount of distal tipping of the maxillary dentition and posterosuperior distalization of pterygoid plate and thus contribute to the correction of a Class II malocclusion. Proclination of mandibular incisors is the common dentoalveolar side effect seen during fixed functional treatment which prevented by cinch back of mandibular archwire and figure eight consolidation of mandibular arch and lingual crown torque in anterior segment of mandibular arch.^{3,6-9}

In this case, results achieved by Powerscope were shown in Table 1. Fixed functional phase produced remarkable correction of skeletal and dental relationship (Fig. 4). The following changes were seen, ANB angle was reduced 4.2° to 2.9° to 2.3° after active fixed functional phase at post treatment. Only 1.3° of increase is observed in IMPA after fixed functional phase which reduced 0.8° after fixed orthodontic phase by correction of mandibular incisor proclination. The soft tissue improvement was seen with a trend towards orthognathic profile. As the mandibular incisor proclination is the most pronounced dentoalveolar side effect seen during fixed functional treatment. But still significant improvement was noted in the dental esthetics skeletal and soft tissue profile, pleasant smile was achieved for this patient.

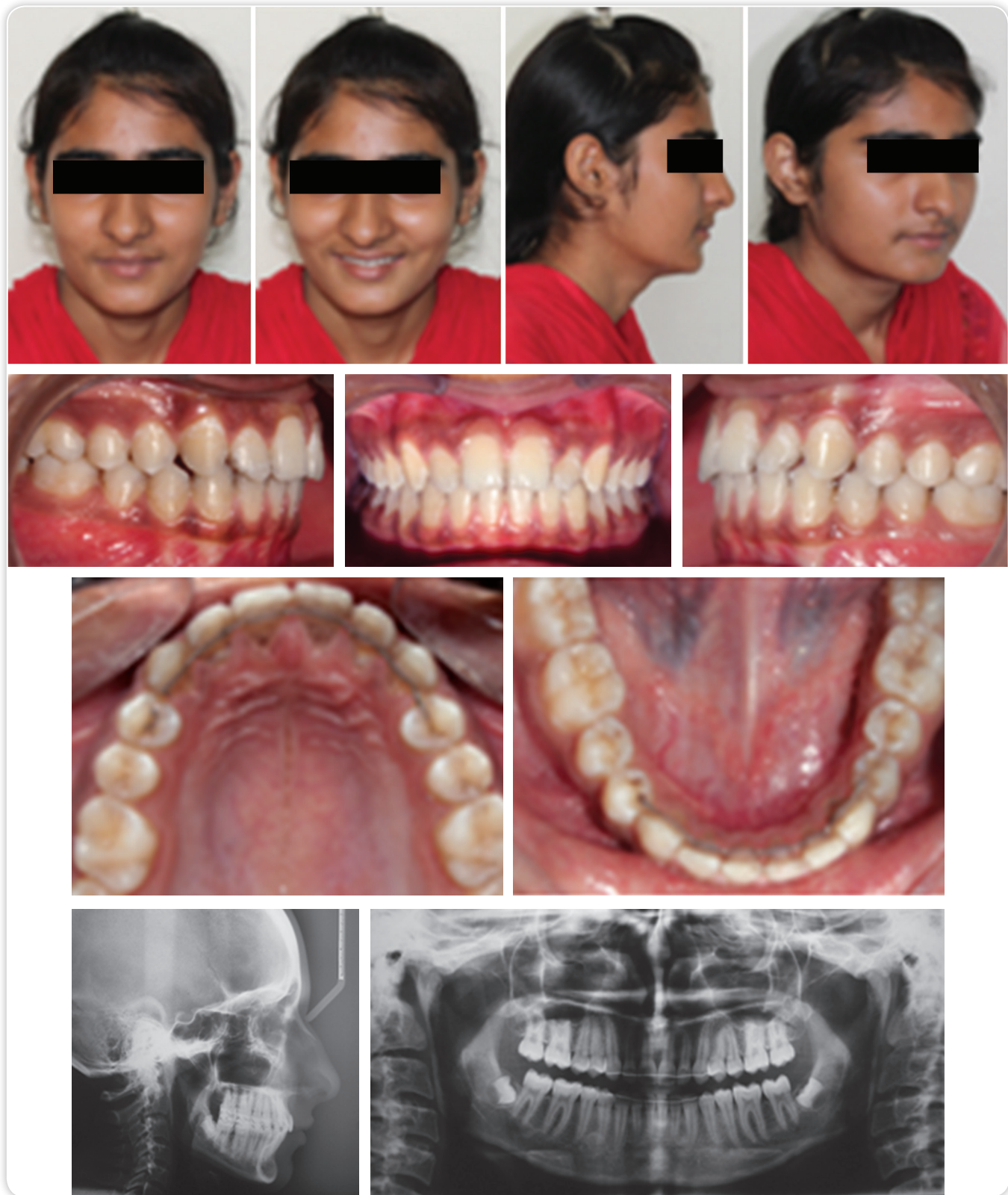

Figure 6 One-year follow up

After one year follow up record shows almost stable result (Table 1 and Fig. 5). Kelly MH¹⁰ study shows that Class II correction seen during this treatment protocol appears generally stable after 12 months following the end of treatment. The relapse during the retention period is statistically significant for overjet, overbite, and the ANB angle. However, the small movements for each of these measures suggest that the relapse is not clinically significant.

CONCLUSION

All those Class II condition which occur due to retruded mandible can be corrected without extraction with the help of fixed functional Class II corrector appliance POWERSCOPE™. This appliance system provided best treatment options for the Class II correction by utilizing remaining growth potential of patient, especially for noncompliant patients, by sagittal forward displacement of the mandible.

Address for Correspondence

Kumar M
Professor
Department of Orthodontics and Dentofacial Orthopaedics
Teerthanker Mahaveer Dental College
Moradabad, Uttar Pradesh, India
e-mail: drmukeshortho@yahoo.co.in

REFERENCES

1. Proffit WR, Field HW, Sarver DM. Contemporary Orthodontics 5th edn, CV Mosby Co; 2013.
2. Weiland FJ, Droschi H. Treatment of class II div I malocclusion with the Jasper jumper. A case report. Am J Orthod Dentofacial Orthop. 1996;109:1-9.
3. Papadopoulos MA. Orthodontic Treatment of the Class II Noncompliant Patient. CV Mosby Co; 2006.
4. Graber TM, Rakosi T, Petrovic A. Dentofacial Orthopedics with Functional Appliances. St. Louis: CV Mosby Co; 1997. pp. 346-52.
5. Siara-Olds NJ, Kulbershb VP, Bergerc J, Bayirli B. Long-term dentoskeletal changes with the bionator, Herbst, Twin block, and MARA functional appliances. Angle Orthodontist. 2010; 80(1):18-29.
6. Pancherz H, Ruf S, Kohlhas P. "Effective condylar growth" and chin position changes in Herbst treatment: A cephalometric-radiographic long-term study. Am J Orthod Dentofacial Orthop. 1998;114:437-46.
7. Pancherz H. Treatment of Class II malocclusion by jumping the bite with the Herbst appliance: a cephalometric investigation. Am J Orthod Dentofacial Orthop. 1979;76:423-41.
8. Jasper JJ, McNamara JA Jr. A correction of inter arch malocclusion using a fixed force module. Am J Orthod Dentofacial-Orthop. 1995;108:641-60.
9. Khumanthem S, Kumar M, Ansari A, Jain A. Correction of Class II using Powerscope Appliance – A case report. Arch of Dent and Med Res. 2016;2(3):120-5.
10. Kaley MH. Long-term post-treatment stability of the Herbst appliance. Chapel Hill. 2006.