

Case Report

Management of Class II Malocclusion with Modified Pendulum Appliance and Second Molar Extraction

To cite: Adeni KM, Parameswaran R, Vijayalakshmi D, Ramaswamy M, Nandakumar A. Management of Class II Malocclusion with Modified Pendulum Appliance and Second Molar Extraction. *Journal of Contemporary Orthodontics*, June 2018, Vol 2, Issue 2, (page 15-21).

Received on:
15/04/018

Accepted on:
18/05/2018

Source of Support: Nil

Conflict of Interest: None

Adeni KM¹, Parameswaran R², Vijayalakshmi D³, Ramaswamy M⁴, Nandakumar A⁵

¹Postgraduate, Meenakshi Ammal Dental College and Hospital
Chennai, India

²Professor, Meenakshi Ammal Dental College and Hospital
Chennai, India

³Professor and Head, Department of Orthodontics
Meenakshi Ammal Dental College and Hospital
Chennai, India

⁴Private Practitioner

⁵Professor, Meenakshi Ammal Dental College and Hospital
Chennai, India

ABSTRACT

Distalization of upper molars aided by second molar extraction is a method of gaining space for alignment of teeth in patients with class II malocclusion who have a pleasant profile. It is a viable treatment alternative when conventional extraction of bicuspid is contraindicated. This case report presents a therapeutic protocol for the management of class II malocclusion by second molar extraction to accelerate molar distalization using a modified pendulum appliance and correction of severe deep bite with anterior crowding and enhance facial esthetics.

Key words: Second molar extraction, molar distalization, modified pendulum appliance, deep bite correction.

INTRODUCTION

Extraction of maxillary second molars for the correction of Class II malocclusions often streamlines orthodontic therapy provided, an appropriate case is selected. Studies have reported several advantages of second molar extraction such as, accelerating molar distalization, stabilizing the occlusion, avoiding arch length discrepancy which would cause impaction of third molar, reducing treatment time and patient compliance.¹⁻³

The main concerns in orthodontic therapy is patient's frontal and profile esthetics. Conventional extraction of premolars to relieve crowding in patients with pleasant profile is viewed critical during retraction phase. Electing for second molar extraction seems to be a wiser decision as there would be minimal impact on patient profile and also resolves crowding in both buccal and labial segment.⁴⁻⁶

Empirical evidences state that as molar distalizes into extraction space there is increase in inter-maxillary angle which would reduce the over bite, thus patients with a horizontal growth pattern have better results.⁷⁻⁹ However, imperative contemplations must be made on the assessment of the eruptive

path and morphology of the third molars before considering extraction of the predecessor.¹⁰⁻¹²

This case report highlights the successful management of class II malocclusion by second molar extraction to accelerate molar distalization in correction of severe deep bite with anterior crowding and to enhance facial esthetics.

DIAGNOSIS AND ETIOLOGY

A 17 years old female patient reported to the Department of Orthodontics and Dentofacial Orthopedics with chief complaint of irregularly placed upper and lower front teeth. No history of serious illnesses or trauma was elicited by the patient.

Extra oral examination revealed a mesoprosopic facial pattern, convex facial profile, average nasolabial angle, deep mentolabial sulcus and low clinical FMA and reduced lower face height. The patient exhibited reduced incisal exposure during smile and a non-consonant smile arc. Intra oral examination revealed ovoid maxillary arch with crowding in anterior region and rotation of 11, 12, 16, 21, 22, and 26. The mandibular arch was ovoid with severe lower anterior crowd-

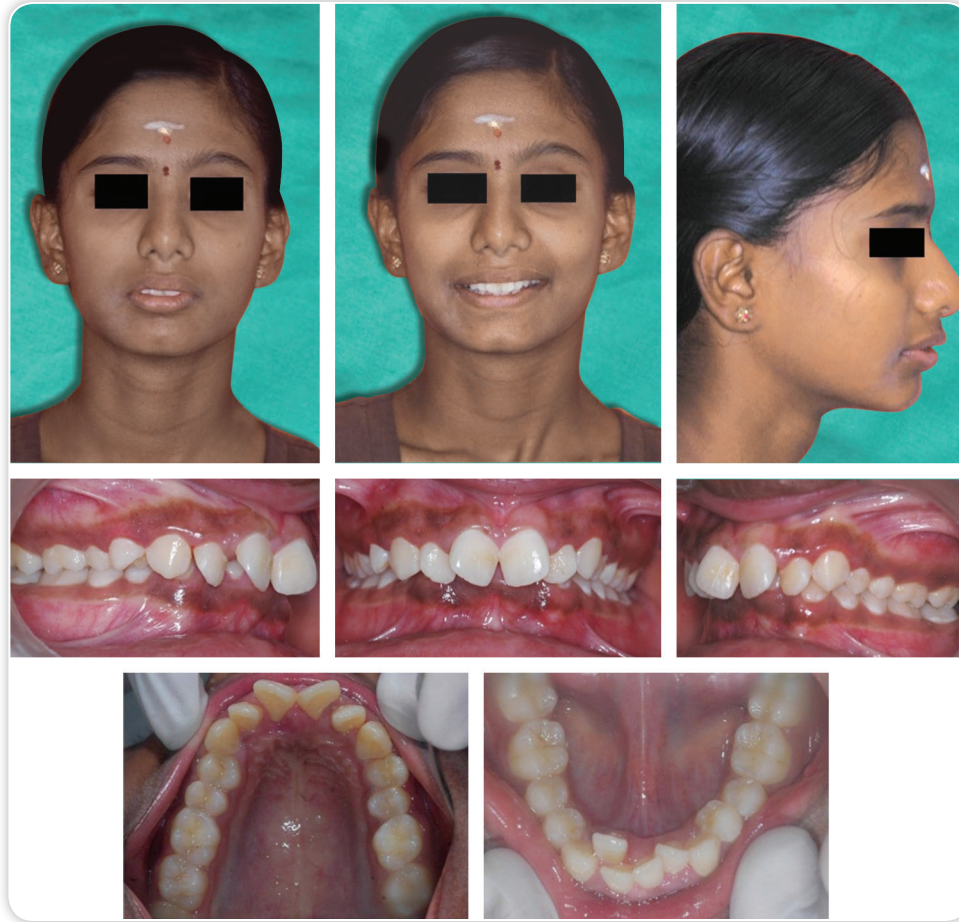

Figure 1 Pre treatment facial and intraoral photographs

ing. Patient exhibited Class II molar and canine relationship bilaterally along with complete deep bite, exaggerated curve of spee and overjet of 8mm. The upper dental midline coincided with facial midline. Scissors bite was present in relation to 14 and 44 region (**Figure 1**).

Model analysis revealed arch length-tooth material discrepancy of 11mm in upper arch and 9 mm in lower arch. There was a Bolton's discrepancy of 5.1 mm overall maxillary excess.

Pretreatment Orthopantomogram (OPG) (**Figure 2**) indicated that patient was in her permanent dentition stage with no missing or supernumerary teeth. Unerupted third molars were present in both the jaws. The upper third molars showed 2/3rd of root development, favourably positioned near CEJ of second molar with no variation in morphology.^{11,12}

Cephalometric evaluation revealed skeletal class II with orthognathic maxilla (SNA-83°) and retrognathic mandible (SNB-76°) on a low mandibular plane angle (FMA-19°). Upper incisors and lower incisors were upright. The upper and lower posterior dentoalveolar height was decreased. Lower

anterior facial height was also found to be reduced (**Figure 2, Table 1**).

Based on the investigations, the case was diagnosed as Angle's dentoalveolar Class II malocclusion on a class II skeletal base attributing to orthognathic maxilla and retrognathic mandible on a low mandibular plane angle with scissors bite in 14-44 region, true deep bite due to intrusion of the posterior teeth resulting in a vertical discrepancy with two different occlusal planes i.e. anterior and posterior and crowding in upper and lower anterior region.

Treatment Objectives

1. To improve facial profile
2. To correct the scissors bite in relation to 14 and 44 region
3. To alleviate the deep bite and achieve ideal over bite
4. To distalize the upper first molars bilaterally
5. To achieve class I molar relationship
6. To achieve class I canine relationship

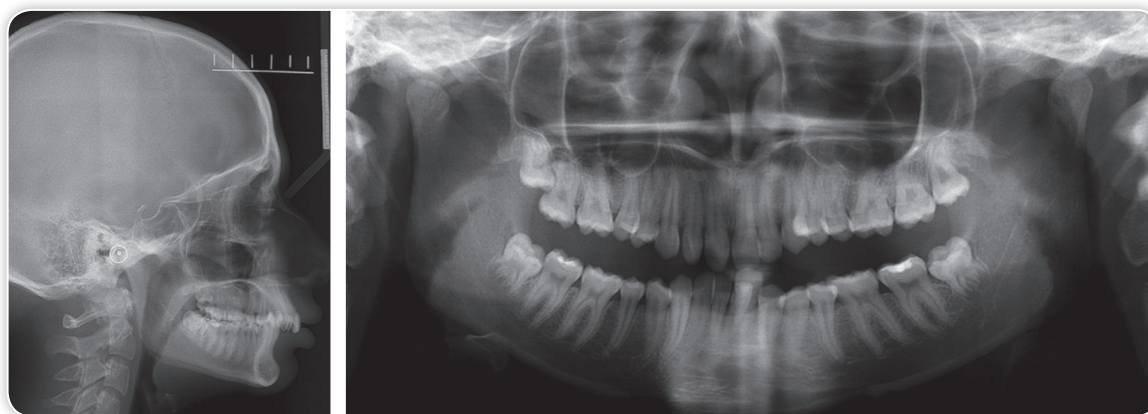


Figure 2 Pre treatment lateral cephalogram and panoramic radiographs

Table 1

Comparison of pre- and post-treatment cephalometric variables

Variables	Norms	Pre-treatment	Post-treatment
Sagittal Skeletal Relationship			
SNA	82	83	81
SNB	80	76	76
ANB	2	7	5
Dental Base Relationship			
U 1 to NA (mm)	4	4	2
U 1 to NA (°)	22	22	23
L 1 to B (mm)	4	3	4
L 1 to B (°)	25	20	23
IMPA	90	94	96
Inter-incisal angle (°)	131	135	132
Vertical Skeletal and Dental Relationship			
FMA	25	19	22
Body length(Go-Me)	71±5mm	65	65
ANS-PNS	48.1-56.1	49	49
Lower anterior facial height (Ans-Gn/HP)	57.6±65.0	48	52
1 TO NF	25.8-29.2	28	27
1 TO MP	39.0-42.6	39	38
6 TO NF	21.7-24.3	19	22
6 TO MP	30.2-34.0	28	31
Soft Tissue			
Nasolabial angle (°)	90-110	93	91

7. To de-crowd and align the upper and lower teeth
8. To achieve ideal overjet.

Treatment Alternatives

- *Surgical treatment plan:* Mandibular advancement by tripoding would be effective in reducing the overbite, achieving class I molar and canine relationship, increase

the lower facial height and overall improvement in facial profile. However, this approach was rejected by the patient.

- *Fixed functional appliance:* Firstly post pubertal growth wouldn't permit for maximum skeletal correction. Secondly, the appliance causes intrusion of upper molar which would further worsen the existing deep bite. Also it necessitates patient cooperation.

- *Extraction of 14, 24:* Retraction of anterior teeth will result in obtuse nasolabial angle which would worsen the profile.
- *Extraction of 15, 25:* Due to 'wedge effect' concept it would deepen the bite further.
- Thus, an alternative compromise in such clinical scenario where surgical treatment is not accepted and camouflage by premolar extractions is unfavorable, then molar distalization followed by extraction of 17, 27 is indicated: The molar distalization allows normalization of upper incisors inclination without altering nasolabial angle, provides space for decrowding and alignment, reduces overjet as well as achieve canine guidance. The molar extrusion produced by intra oral distalizing appliance is promising as it will cause bite opening, steepens the mandibular plane and improves the lower facial height. The normally erupting third molars would glide to occlusion and replace the extraction space and avoids complications of third molar impaction as well.

Treatment Plan

Based on the clinical and radiological observation, the treatment was decided to be extraction of 17 and 27. Molar distalization using Pendulum appliance followed by fixed orthodontic therapy.

Treatment Progress

The pendulum appliance was preactivated and cemented in place. The nance button was modified in such a way that it would act like an anterior bite plane by disoccluding the dentition which in turn would allow supra eruption of the posterior teeth (**Figure 3**). This was followed by bilateral therapeutic ex-

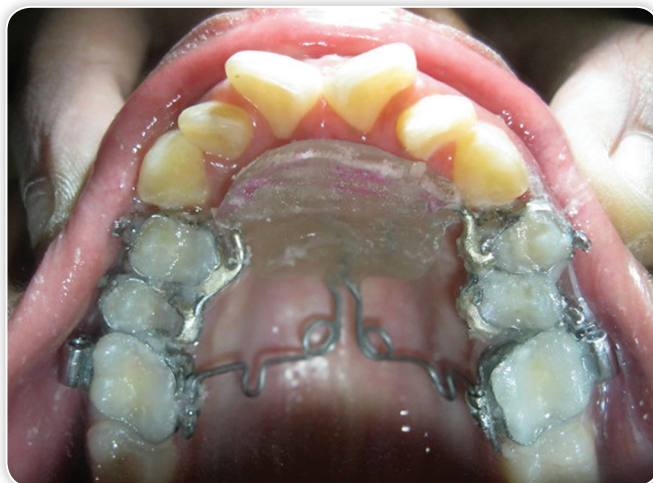

Figure 3 Modified pendulum appliance for molar distalization

traction of the upper second permanent molars which allowed the upper third molars to spontaneously erupt in place of the extraction space. Though good amount of molar distalization had occurred, there was some relapse seen in relation to 16. Anchor loss is an inevitable side effect that occurs with any conventional intra oral distalizing appliance owing to the rotation along the palatal root axis. This can be avoided if proper intercuspation is established immediately, post distalization. Thus, a modified distalizer was used to regain the space lost by anchor loss. On the affected side the Nance button was incorporated with a soldered post and an open coil spring to further distalise the molar which had relapsed (**Figure 4**). At this juncture, fixed appliance was initiated with 0.016" NiTi in both upper and lower arches segmentally using Pre-Adjusted Edgewise prescription. Once Class I molar relation was achieved, the anteriors were strapped up for final arch coordination and aligning & leveling was done sequentially progressing from 16 X 22 NiTi, 17 X 25 NiTi and 19 X 25 NiTi (**Figure 5**). This was followed by therapeutic extraction of the completely blocked out incisor 41. Inter-proximal slicing in upper arch was performed to compensate for the Bolton's discrepancy. Space closure was accomplished using tear drop loop retraction on 19 X 25 SS. Finally, settling was done using intermaxillary elastics using 0.014 SS for better intercuspation.

In the retention phase a wraparound retainer was placed in the maxillary arch and a bonded lingual retainer in the mandibular arch on the same day of debonding. Gingivoplasty was performed to address the unaesthetic gingival marginal heights in upper arch.

At the end of the orthodontic treatment, it was possible to observe stable occlusion with Class I molar and canine relationships, adequate overbite and overjet and good form of dental arches. Overall, the treatment outcome was pleasing in delivering a vibrant smile to the patient (**Figure 6**).

DISCUSSION

Most clinicians talk reluctantly about the extraction of second molars. Some authors even believe that distalization is best done when second molar eruption is not completed.¹³ However Kinzinger et al¹⁴ stated that, molar distalization is possible even when second molars are fully erupted. But when more of distal movement is required and clinical scenarios doesn't permit extraction of the upper first bicuspsids, then the only beneficial option would be to extract the upper second molars and let the third molars drift into extraction space.¹⁵ Nevertheless, the detrimental aspects are the angulation and position of the third molar with respect to second molar which would be the deciding key factor to extract the second molar or not. Thus,

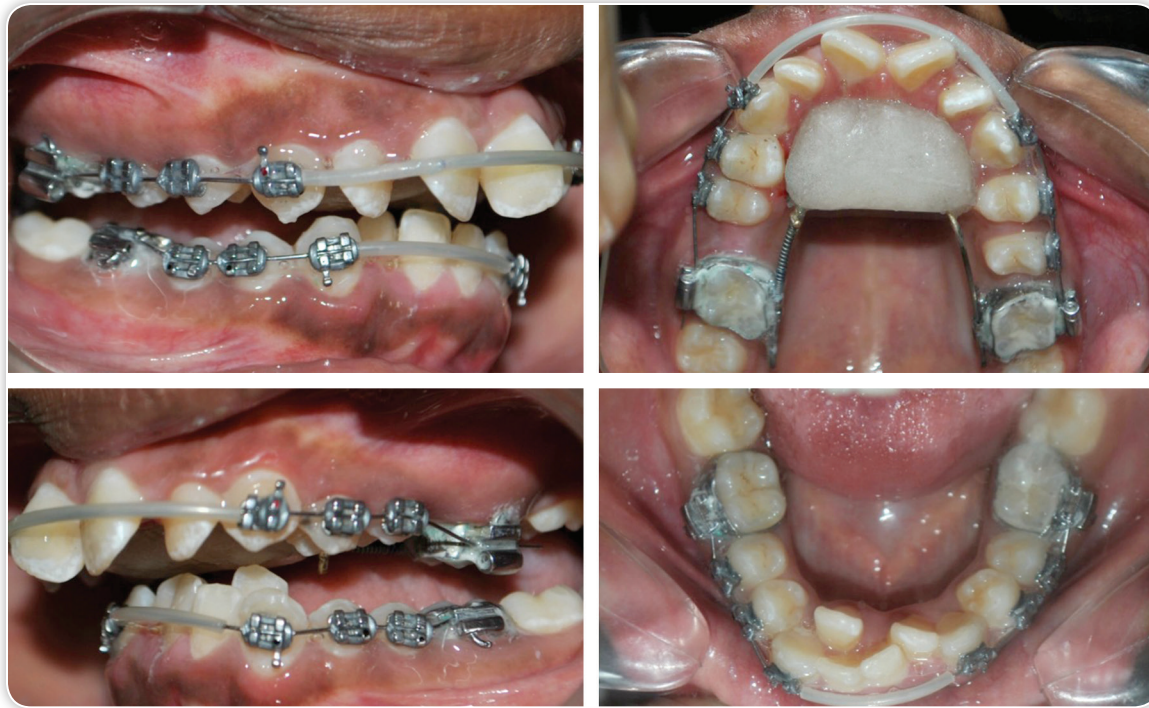

Figure 4 Modified molar distalizer

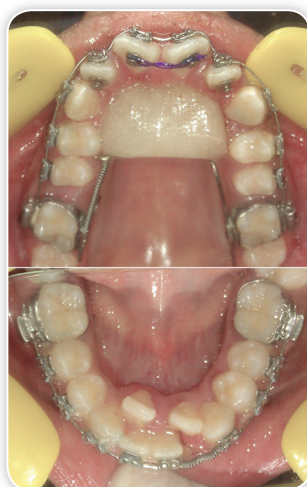

Figure 5 Completed strap up photographs

the primary prerequisite will be the radiographic confirmation that third molars are favorably positioned with normal morphology.^{10,12} The present case had a class II malocclusion with ideally positioned third molars, a pleasant profile, crowding in upper and anterior region with upright incisors. Therefore, this patient was a good candidate to attempt molar distalization with second molar extraction.

Cephalometric values indicated that, by distalization, an increase in mandibular plane angle was evident and resultant increase in lower anterior facial height (**Figures 7 and 8, Table 1**). Apart from this, the use of versatile pendulum appliance proved to be effective in distalizing maxillary molars with minimal patient compliance. Modest amount of over bite correction was seen due to the wedge bite opening tendency of the appliance which may have caused by the extrusion of posterior teeth or molar being distalized in the arc of closure.¹⁶ These changes are expected in accordance with molar distalization cases.^{17,18} The third molars had adequately erupted into the extraction space of second molars. The soft tissue profile was maintained throughout the treatment. Overall the entire treatment outcome was beneficial in accomplishing the treatment goals.

CONCLUSION

The process of distalization is dependent on critical decision making, regarding extractions and prudent selection of intra oral distalizing appliance. When properly indicated, upper second molar extraction serves as a valuable adjunct in orthodontic treatment. This therapeutic option offers several advantages such as: treatment mechanics is simplified by accelerating distalization, maintains a harmonious profile, better stability, shortens treatment duration and good patient compliance.

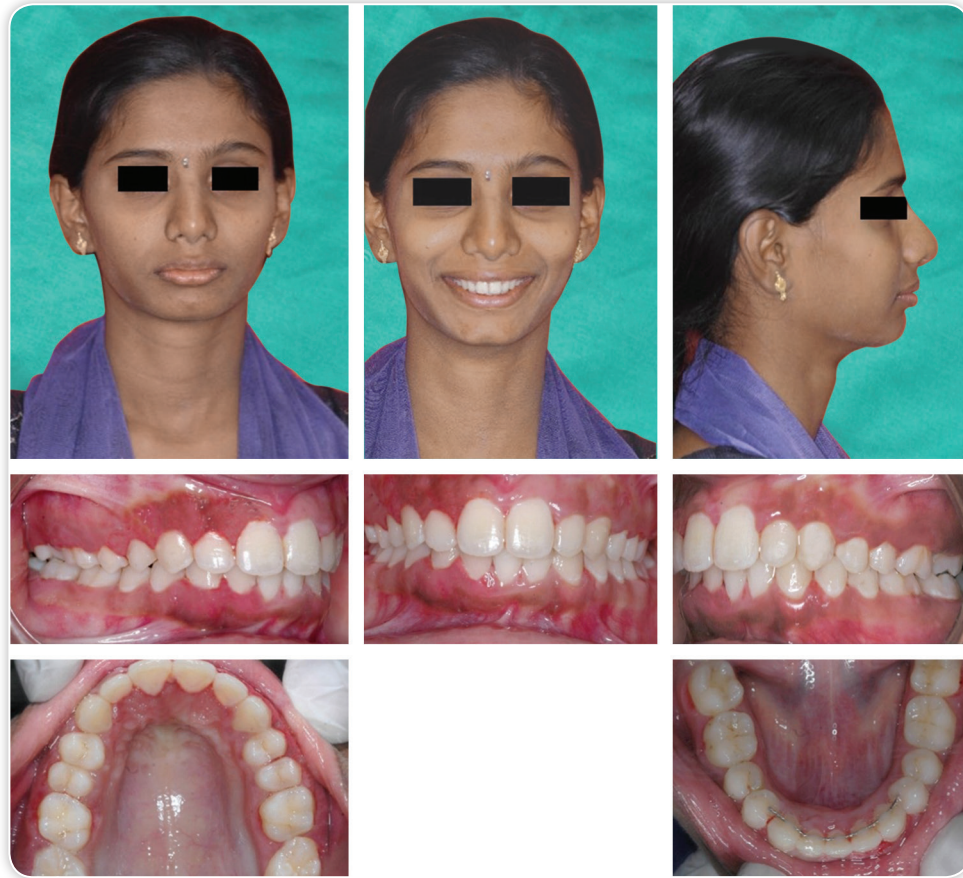

Figure 6 Post treatment facial and intraoral photographs

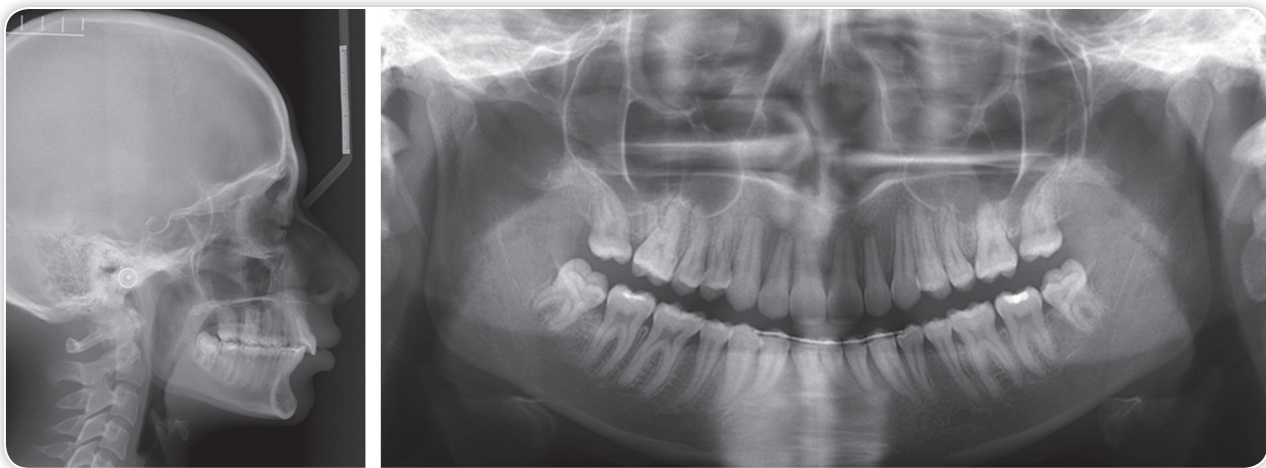


Figure 7 Post treatment lateral cephalogram and panoramic radiographs

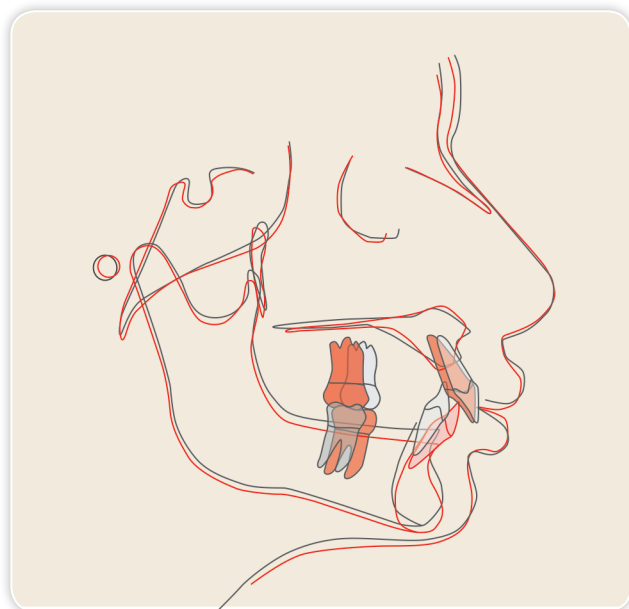


Figure 8 Superimposition of pre and post treatment lateral cephalogram

Address for Correspondence

Adeni K Moina
Postgraduate
Meenakshi Ammal Dental College
and Hospital
Chennai, India
E-mail: drmoinaadeni@gmail.com

REFERENCES

1. Lehman R. A consideration of the advantages of second molar extractions in orthodontics. *Eur J Orthod.* 1979;1:119-24.
2. Liddle DW. Second molar extraction in orthodontic treatment. *Am J Orthod.* 1977;72:599-616.
3. Waters D, Harris EF. Cephalometric comparison of maxillary second molar extraction and nonextraction treatments in patients with Class II malocclusions. *Am J Orthod Dentofacial Orthop.* 2001;120(6):608-13.
4. Romanides N, Servoss JM, Kleinrock S, Lohner J. Anterior and posterior dental changes in second molar extraction cases. *J Clin Orthod.* 1990;24(9):559-63.
5. Staggers JA. A comparison of results of second molar and first premolar extraction treatment. *Am J Orthod Dentofacial Orthop.* 1990;98(5):430-6.
6. T.M.Grabner. Maxillary second molar extraction in class II malocclusion. *Am J Orthod.* 1969;56(4):331-53.
7. Magness WB. Extraction of second molars. *J Clin Orthod.* 1986;20:519-22.
8. Basdra EK, Komposch G. Maxillary second molar extraction treatment. *J Clin Orthod.* 1994;28:476-81.
9. Aynur Aras. Class II Correction with the Modified Sagittal Appliance and Maxillary Second Molar Extraction. *The Angle Orthodontist.* 2000;70(4):332-8.
10. Moffitt AH. Eruption and function of maxillary third molars after extraction of second molars. *Angle Orthod.* 1998;68(2):147-52.
11. Sharon Orton-Gibbs, Victor Crow and Harry S. Orton. Eruption of third permanent molars after the extraction of second permanent molars. Part 1: Assessment of third molar position and size. *Am J Orthod Dentofacial Orthop.* 2001;119:226-38.
12. Mauricio Barbieri Mezomo, Manon Pierret, Gabriella Rosenbach, Carlos Alberto E. Tavares. Extraction of upper second molars for treatment of Angle Class II malocclusion. *Dental Press J Orthod.* 2010;15(3):94-105.
13. Bolla E, Muratore F, Carano A, Bowman SJ. Evaluation of maxillary molar distalization with the distal jet: A comparison with other contemporary methods. *Angle Orthod.* 2002;72:481-94.
14. Kinzinger GS, Fritz UB, Sander FG, Diedrich PR. Efficiency of a pendulum appliance for molar distalization related to second and third molar eruption stage. *Am J Orthod Dentofacial Orthop.* 2004;125:8-23.
15. Hilgers JJ. The pendulum appliance for Class II non-compliance therapy. *J Clin Orthod.* 1992;26:706-14.
16. Ghosh J, Nanda RS. Evaluation of an intraoral maxillary molar distalization technique. *Am J Orthod Dentofacial Orthop.* 1996;110:639-46.
17. Bussick TJ, McNamara JA Jr. Dentoalveolar and skeletal changes associated with the pendulum appliance. *Am J Orthod Dentofacial Orthop.* 2000;117:333-43.
18. Shashikala Kumari, Bhagyalakshmi A. Evaluation of maxillary molar distalization with Hilgers's Pendulum appliance and M-pendulum appliance—A comparative clinical study. *Journal of Indian Orthodontic Society.* 2007;4:84-9.