

Diagnostic setup procedure simplified : a case report

Dr. Sunanda Roychoudhury^a, Dr. Kumar Amit^b

Abstract:

Proper classification and diagnosis are prerequisites for determining the nature of an orthodontic problem. The diagnostic methods have shifted from a two dimensional to three dimensional approach. Despite advances in orthodontic diagnostic aids, the setup technique provides the foundation on which the modern day three dimensional diagnosis of malocclusion is based. Kesling, after developing a tooth positioner as an aid in finishing orthodontic treatments, suggested that cutting and repositioning the teeth in duplicate study models of the malocclusions would allow simulation of the results before starting orthodontic treatment. The aim of this article is to present a simplified method of doing diagnostic setup with the objective of encouraging its use in day to day clinical practice.

Keywords: Diagnostic aids, Setup, Tooth positioner, Malocclusion, Simulation.

INTRODUCTION

The objective of orthodontic treatment is to establish optimal proximal and occlusal contact of the teeth within the framework of acceptable facial esthetics, normal function, and reasonable stability. These objectives of treatment for an individual are not always compatible, and good clinical orthodontics consists of achieving a balance between these factors. Proper classification and diagnosis are prerequisites for determining the nature of an orthodontic problem. Once the nature of the problem has been determined, a treatment plan can then define the steps necessary to achieve a balance of the objectives of treatment.¹

Until the recent past, the emphasis in planning orthodontic treatment was based on photographs, model analysis, and cephalometric analysis. The contemporary approach involves a much more detailed clinical examination where many aspects of the treatment plan reveal themselves as a function of the systematic evaluation of the functional and aesthetic presentation of the patient.² The diagnostic methods have shifted from a two dimensional to three dimensional approach. Despite advances in orthodontic diagnostic aids, the setup technique provides the foundation on which the modern day three dimensional diagnosis of malocclusion is based.

Setup is a technique whereby teeth are reassembled in plaster models to depict the patient's malocclusion.³⁻⁸ In carrying out this diagnosis, the teeth are separated from each other and from the bases of upper and lower casts, allowing them to be repositioned within the framework of orthodontic treatment planning. Setup's key advantage lies in allowing professionals to ascertain that treatment planning is indeed viable in each case. It answers questions

such as the following: Are extractions necessary or will the mere stripping of interproximal prove sufficient to align the teeth? How much interproximal stripping should be performed and on which teeth? What precautions would be necessary to ensure proper anchorage?

THE KESLING SETUP

In 1953, Kesling, after developing a tooth positioner as an aid in finishing orthodontic treatments, suggested that cutting and repositioning the teeth in duplicate study models of the malocclusions would allow simulation of the results before starting orthodontic treatment.⁹ While it can be quite laborious, it features considerable advantages, especially in borderline cases where there are clinical issues. Using a setup, treatment plans become less speculative, resembling a real treatment and providing orthodontists with reliable information.¹⁰

The accuracy of Kesling set-up in planning space requirement is unsurpassed but the lengthy laboratory procedures often make it impractical to use in a busy clinical practice. This article is an attempt to present a simplified method of doing Kesling set-up and its use has been demonstrated using a case report.

CASE REPORT

An eighteen year old Indian Asian female reported to outpatient department of our institution with chief complaint of irregularly placed upper and lower front teeth. Clinical examination revealed that the patient had a mesocephalic head with mesoprosopic facial pattern. Patient had slightly convex profile, straight divergence, obtuse nasolabial angle and competent lips.. The patient had Angle's class I malocclusion bilaterally with 3 mm overjet, 3 mm overbite, moderate crowding in maxillary anterior region and severe crowding in mandibular anterior region. **Figure 1a, 1b and 1c**

^a Professor & Head: Department of Orthodontics & Dentofacial Orthopaedics
Shree Bankey Bihari Dental College & Research Centre Ghaziabad.

^b Senior Lecturer: Department of Orthodontics & Dentofacial Orthopaedics
Shree Bankey Bihari Dental College & Research Centre Ghaziabad.



Fig.1a Pre – treatment extraoral photographs

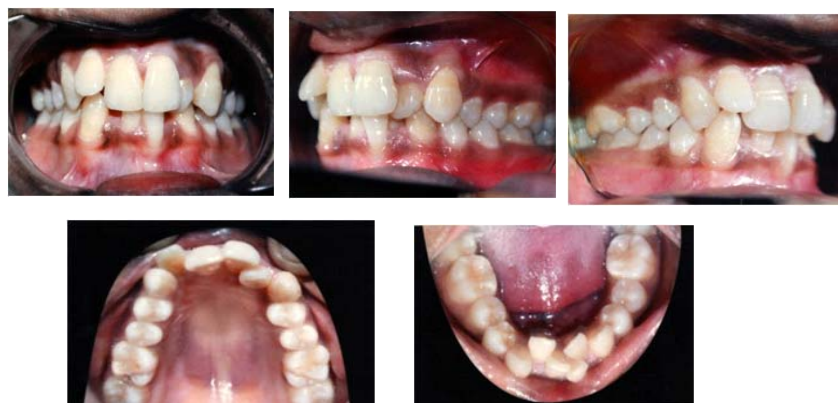

Fig.1b Pre – treatment intraoral photographs

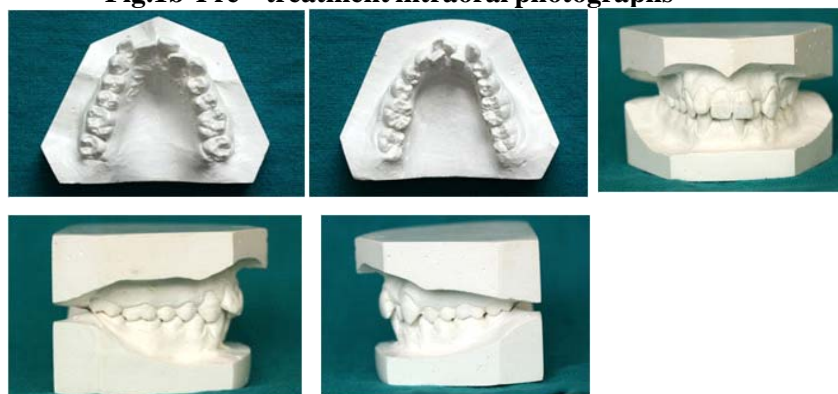

Fig.1c Pre – treatment models

Cephalometric analysis revealed skeletal class II pattern attributable to mildly retrognathic maxilla and retrognathic mandible, hypodivergent face and CVM stage 5 indicating completion of growth. **Figure 2**

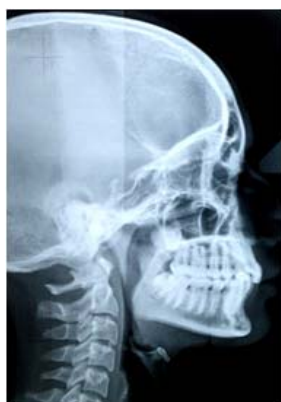

Fig.2 Pre - treatment lateral cephalogram

Orthopantomographic examination revealed no significant abnormality. **Figure 3**

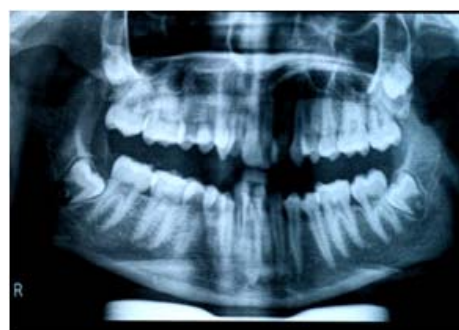

Fig.3 Pre – treatment OPG

Model analysis revealed overall mandibular tooth material excess of 5.3mm and mandibular anterior tooth material excess of 3.9 mm according to Bolton's analysis. Arch perimeter analysis revealed moderate crowding (4 mm) in maxillary arch while severe crowding (9 mm) in mandibular arch. Ashley – Howe analysis revealed need for expansion in maxillary arch while need for extraction in mandibular arch. Based on dental cast and cephalometric examination total arch discrepancy obtained in maxillary arch was 1 mm while that in mandibular arch was 6 mm .

Based on diagnostic revelations and as the nasolabial angle was 115 degrees it was planned that maxillary arch could be aligned by non extraction approach while for mandibular arch it was tentatively planned to extract single lower incisor. In order to visualize the final occlusion and confirm the treatment plan, a simplified method of diagnostic set up was done.

Simplified method of doing Diagnostic set-up : Step by Step procedure

Step 1 : Impression making **Figure 4**

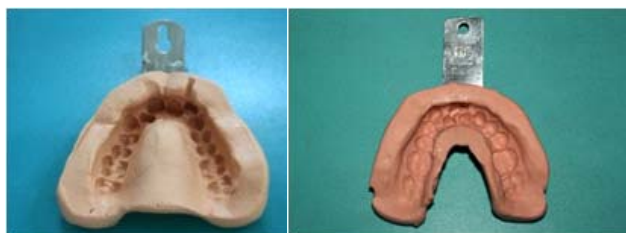


Fig.4 Impression making

- a) Maxillary impression
- b) Mandibular impression

Step 2 : Only the teeth portion of the impression was poured upto the gingival margins. Vaseline was applied for ease of separation of teeth part from alveolar bone part. **Figure 5**

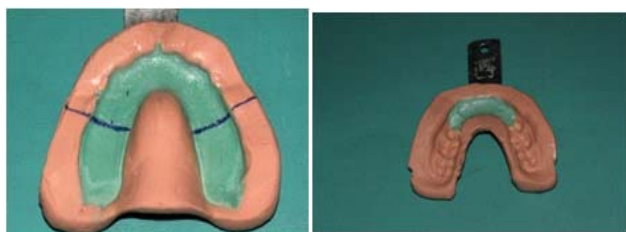


Fig.5 Impression poured and Vaseline applied

Step 3 : Final models after setting of stone and plaster were obtained. **Figure 6**

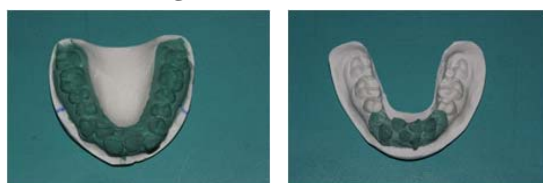

Fig.6 Final models

Step 4 : Models were articulated on a fixator. **Figure 7**

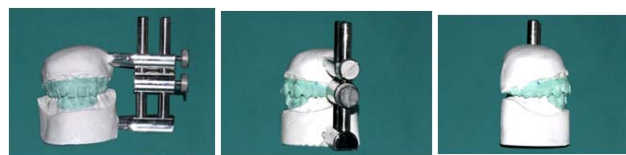

Fig.7 Models articulated on fixator

Step 5: Teeth were numbered on lingual aspect which were then plucked out from the base of the models by applying pressure at contact points. The teeth were then laid out on a wax sheet quadrant wise. **Figure 8**




Fig.8 Teeth numbered on lingual aspect, plucked out from the base of the models and arranged on wax sheet

Step 6: Wax rims were made on the models. **Figure 9**



Fig.9 Wax rims made on the models.

Step 7: Teeth setting was done according to treatment plan: expansion in maxillary arch, extraction of 31 in mandibular arch. **Figure 10**

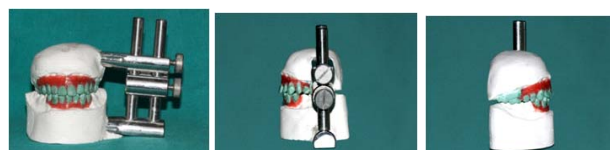

Fig.10 Teeth setting done according to treatment plan: expansion in maxillary arch, extraction of 31 in mandibular arch

The kesling's set-up simulated the contemplated result and hence the treatment plan was executed. Tooth #31 was extracted and fixed appliance treatment was started with MBT (0.022 slot) bracket prescription. Total treatment duration was 2 years and 3 months. Stable occlusion and balanced facial proportion were achieved. **Figure 11a, 11b, 11c and 11d**



Fig.11a Post- treatment extraoral photographs

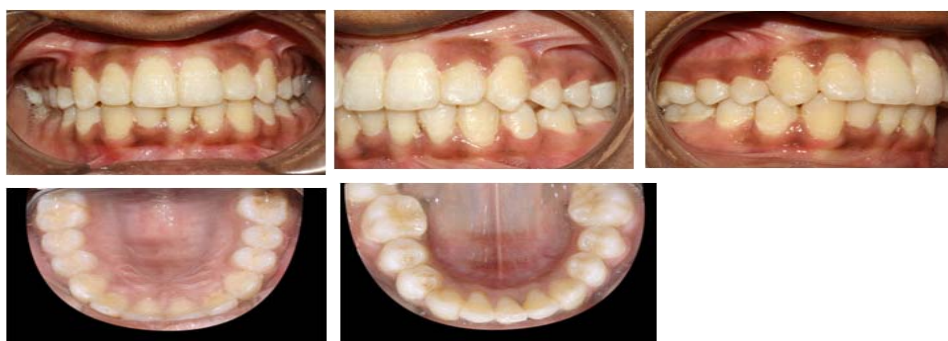


Fig.11b Post – treatment intraoral photographs

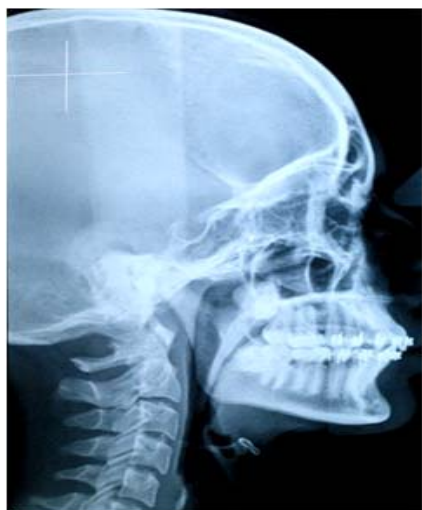

Fig.11c Post – treatment lateral cephalogram

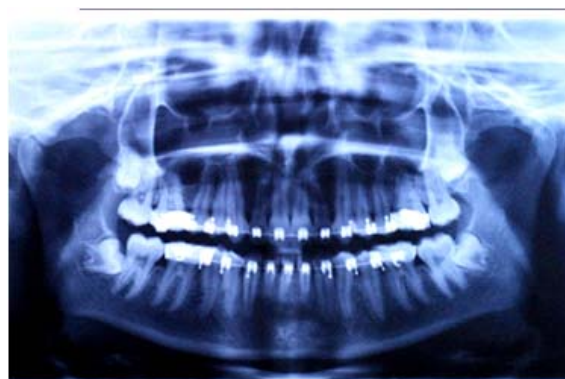

Fig.11d Post – treatment OPG

DISCUSSION

Plaster casts have long been in use for the analysis and treatment planning of all orthodontic cases. Although they have been considered study casts, much of the study has been merely speculation as to what might be accomplished orthodontically. Good orthodontic casts not only provide exact duplicates of every tooth in the mouth, but they also give a fairly accurate pattern of the apical base. Since neither apical base nor tooth size can be altered materially, intelligent rearrangement, of the plaster teeth on the model can replace the confusion of speculation with concrete objective manipulation.¹¹

The results of this study demonstrate that the use of Diagnostic set-up is reliable and an excellent method to

avoid confusion in borderline cases. It allows a three dimensional view of the patient's occlusion at the end of treatment. This enables greater confidence in the application of any orthodontic therapy. In using the setup, the main goal is to provide the orthodontist with a realistic view of how a case that is being planned will likely end. Thus, the setup should not be constructed artistically to help persuade the patient to accept treatment but very carefully, in line with the treatment goals and limitations of orthodontic mechanics.⁴

CONCLUSION

Based on the results obtained in this study it can be inferred that the accuracy of Diagnostic set-up in planning and simulating the desired results in three dimensional setting is unmatched. Fabrication of a manual setup involves a laborious technique. However, using slight modifications tactfully and when properly performed and analyzed, it

provides data that can facilitate treatment and reduce biological damage to the patient. More and more use of this diagnostic aid should be promoted.

Acknowledgement :

We thank Dr. Vijay Pal for his contribution to this case report.

REFERENCES

1. Treatment response as an aid in diagnosis and treatment planning - Ackerman and Proffit :AJODO , Volume 1970 May, 490 – 496.
2. Orthodontics current principles and techniques: Xubair, Graber, Vanarsdall and Vig, fifth edition, 2011, Elsevier mosby.
3. Kim SH, Park YG. Easy wax setup technique for orthodontic diagnosis. J Clin Orthod. 2000;34:140–144.
4. Araujo TM, Fonseca LM, Caldas LD, Costa-Pinto RA. Preparation and evaluation of orthodontic setup. Dental Press J Orthod. 2012;17:146–165.
5. Mattos CT, Gomes AC, Ribeiro AA, Nojima LI, Nojima M da C. The importance of the diagnostic setup in the orthodontic treatment plan. Int J Orthod. 2012;23:35–39.
6. Sousa MV, Vasconcelos EC, Janson G, Garib D, Pinzan A. Accuracy and reproducibility of 3-dimensional digital model measurements. Am J Orthod Dentofacial Orthop. 2012;142: 269–273.
7. Fleming PS, Marinho V, Johal A. Orthodontic measurements on digital study models compared with plaster models: a systematic review. Orthod Craniofac Res. 2011;14:1–16.
8. Marcel T. Three-dimensional on-screen virtual models. Am J Orthod Dentofacial Orthop. 2001;119:666–668.
9. Andrade BNG, Almeida RC, Carvalho FAR, Quintão CCA, Almeida MAO. Avaliação da confiabilidade do setup no diagnóstico e planejamento ortodôntico. Ortodontia. 2010;43(4):389-95.
10. Telma Martins de Araújo et al, Dental Press J Orthod. 2012 May June;17(3):146-65
11. The diagnostic setup with consideration of the third dimension. Harold D Kesling. Am J Orthodontics, October 1956; volume 42, number 10 (740-748).