

MU HOOK SIMPLIFYING PNAM

Ashith.M.V.^a, Poulomi Roy^b, Utkarsh Mangal^c, Mithwik^d, Nidhin Philip^e

ABSTRACT

Presurgical naso alveolar molding (PNAM) is a non-surgical method of reshaping the gums, lips and nostrils previous to CLP surgery, thus lessening the severity of the cleft. The purpose of this case series is to describe a novel and ingenious device, the MU Hook used in lieu of the conventional PNAM technique. Five cases which used the MU Hook have been described. This device offers multiple benefits over the conventional PNAM as it obviates the need of a plate, so it can be used in CVS infants, or patients with neonatal teeth. Appointments are reduced thus ensuring better compliance, comfort and wellbeing of the parents and the patient.

INTRODUCTION

Cleft lip and palate (CLP) is one of the most common congenital malformations of the head and neck. CLP is a multifactorial disorder with an incidence of 1 in 781 live births in India.¹ Presurgical Nasoalveolar Moulding (PNAM) is a non-surgical method of reshaping the gums, lips and nostrils done prior to CLP surgery, thus lessening the severity of the cleft. Grayson et al described the PNAM technique to presurgically mould the alveolus lip and nose in infants with CLP.² Before the introduction of PNAM, repair of a huge cleft involved several surgeries between birth and 18 years of age, setting the child at risk for emotional and social adjustment problems.³ The biological basis for PNAM is the presence of high level of estrogen at the time of birth to 6-8 weeks which correlates with the increased hyaluronic acid. Hyaluronic acid inhibits the linkage of the cartilage intercellular matrix leading to increased elasticity of tissues and cartilages, making moulding of tissues possible.⁴ According to Hamrik's chondral modeling hypothesis, NAM is thought to simulate immature nasal chondroblasts producing the interstitial expansion, which in turn improves nasal morphology.⁵ The primary goal of PNAM is depicted in the Table 1.

Region	Effect
Alveolar segments ^{6,7}	Reduction of severity of cleft of alveolar segments. Alignment of lesser and greater alveolar segments. Approximation of alveolar cleft without maxillary arch constriction.
Lips ^{8,9}	Nonsurgical columella lengthening. Approximation of lip segments prior to surgery To reduce tension in the lip tissues and hence minimize lip scar. Medialization of the premaxilla (in bilateral cleft lip [BCLP]) along the midsagittal plane and hence aide surgeon to form uniform cupid's bow.
Nose,	Reduction of nasal tip width. Improve nasal tip projection. Decrease nasal alar base width. Improve nostril shape.
Post surgery	Reduce post surgical scarring

Table 1: Primary Goal of PNAM

The Grayson's technique includes obtaining an impression within the first week of birth using a heavy body silicone impression material. A 2-3mm hard clear acrylic plate with a retention button^{40°} to the palate is fabricated on the cast and positioned anteriorly. A nasal stent is later fabricated when the alveolus defect is reduced to 5-6mm in width approximately. The appliance is secured extraorally to the cheeks and bilaterally too by surgical tapes (one quarter inch in width and 3/4th inch in length). The plate requires weekly adjustments. This article describes a novel device the MU hook, which does away with the acrylic plate and

^a- Reader, Department of Orthodontics, Manipal College of Dental Sciences.

^b- Junior Resident, Manipal College of Dental Sciences.

^c- Junior Resident, Manipal College of Dental Sciences.

^d- Assistant Professor, Manipal College of Dental Sciences.

^e- Reader, Department of Orthodontics, Manipal College of Dental Sciences.

has several advantages over the conventional PNAM technique.

MU HOOK

The clinical innovation of MU-Hook, truly simplifies PNAM. In the conventional PNAM custom-made moulding plate of acrylic is used gently to direct the growth of the alveolus to get the desired result later on. In spite of it being an excellent technique, it could not tender to the need of nasoalveolar moulding in some patients where neonatal teeth and ulceration of oral mucosa are present and insertion of plate would cause severe discomfort. It is also difficult to place the moulding plate where the Simonart's band- a soft tissue bridge located either at the base of the nostril or more internally, between the segmented alveolar ridges (Lip-alveolus or lip-palate) is present. Conventional PNAM is not indicated in patients with cardiovascular problems, where impression making has to be avoided and patients who are unable to report to the clinic for regular activations of the plate. Simplicity is the ultimate sophistication and this new device- the MU Hook based on the active upward pull of nasal cartilage with lip taping for nasoalveolar moulding is definitely ingenious.

DESIGN AND FABRICATION

The armamentarium includes a 0.7mm stainless steel wire, a protective sleeve, an acrylic bulb, a soft liner, Dynaplast and skin barrier tapes. Figure 1 A, B The steps in the fabrication and insertion of Mu hook in the patient are

1. A 0.7mm stainless steel wire frame bent in the form of 'T' shape.
2. The T-loop wire component is covered by a protective sleeve.
3. An acrylic bulb coated with soft liner is fabricated on the end of 'T' bent in form of a hook.
4. The nasal hook bulb is placed into the nostrils of the cleft side.
5. The hook is attached to forehead (with dynaplast) generating an upward pull.
6. The use of skin barrier tapes is advocated to reduce any skin irritation.

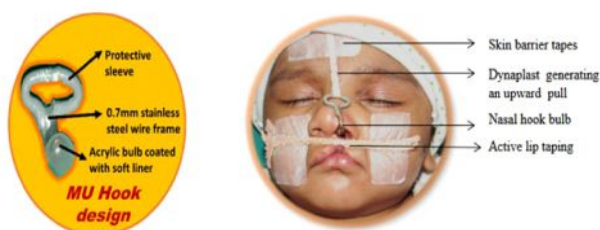

Figure 1 A:. MU Hook Design B. Insetion of MU Hook on patient

7. Active lip taping is done at the base of the nose (pulled from non-cleft side to cleft side)

Versatile design:

MU hook can be modified and used in both unilateral as well as bilateral cleft cases. For bilateral cases the design is modified such that it bifurcates and forms two hooks with acrylic bulbs which can be inserted into both the nostrils. The distance between the two arms is such that it is 2mm away on either side from the lateral wall of the nose and both the acrylic bulbs should be directed towards the midline. The advantages of MU hook are-

1. Simple fabrication-no moulding plate required.
2. Obviates the need for impression technique and its associated risks.
3. No airway obstruction.
4. Minimum lab work.
5. Versatile design-unilateral /bilateral CLP cases.
6. Reduced frequency of patient visit.
7. Easier appliance placement.
8. Greater compliance of patient and parents.

CASE REPORTS

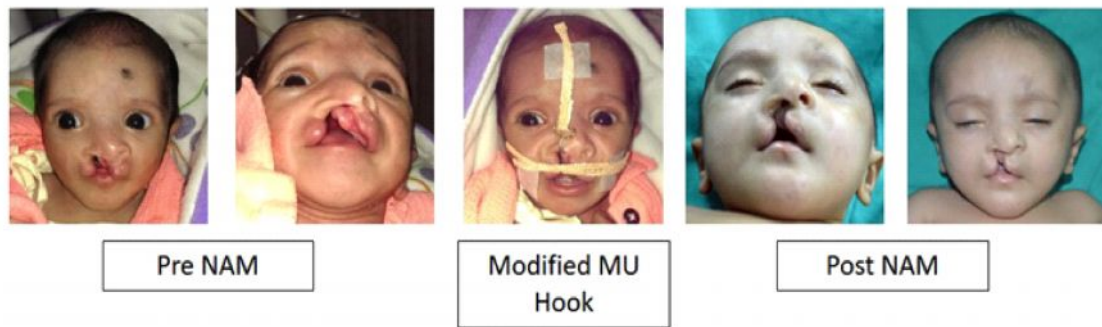Case 1

A 5 days old baby was referred to the Department of Orthodontics and Dentofacial Orthopaedics. On examination, the patient presented with unilateral cleft of lip and palate on the left side. Poor oral hygiene and ulceration on alveolar mucosa contraindicated the conventional acrylic moulding plate. The MU Hook was given to the patient. Parents were educated and trained about insertion and removal of the MU hook and the lip taping. Parents were instructed to change the taping every day. After 2 months favourable changes like approximation of lip segment, increased nostril height, increased alar inclination and reduced nostril imbalances were well appreciated. (Fig 2)

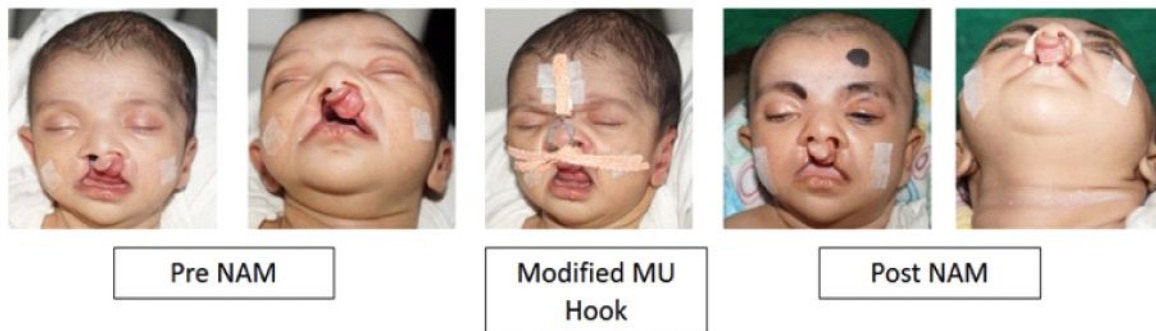
Case 2

A baby reported to the department of Orthodontics at age of 55 days. On examination, the palate was intact with a unilateral cleft lip and alveolus only on the left side. Nostrils were collapsed on the left side. Presence of Simonart band forming a bridge between the premaxilla and lateral nasal prominence demanded nasal moulding without an acrylic plate. Hence a MU Hook appeared as the best choice. Post NAM the nasal changes achieved were an increase in the nasal height, alar inclination, columella length and a decreased nostril imbalance. (Fig 3)

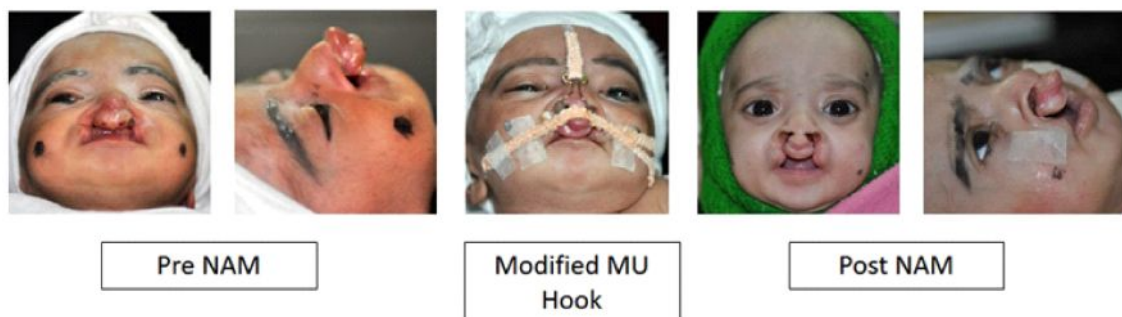Case 3



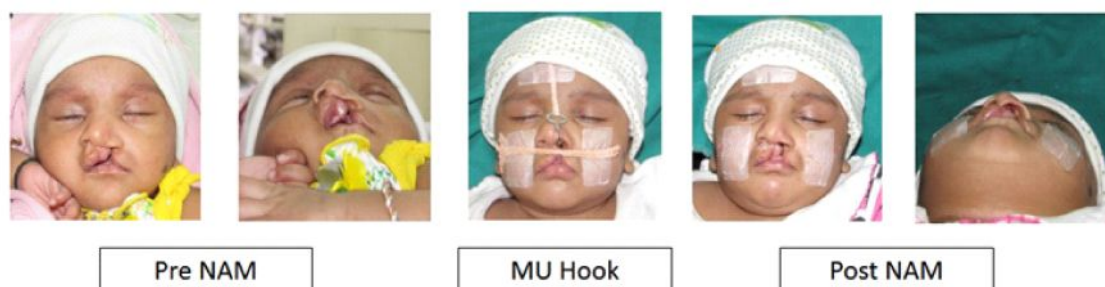Case 1: Unilateral cleft lip and palate on the left side



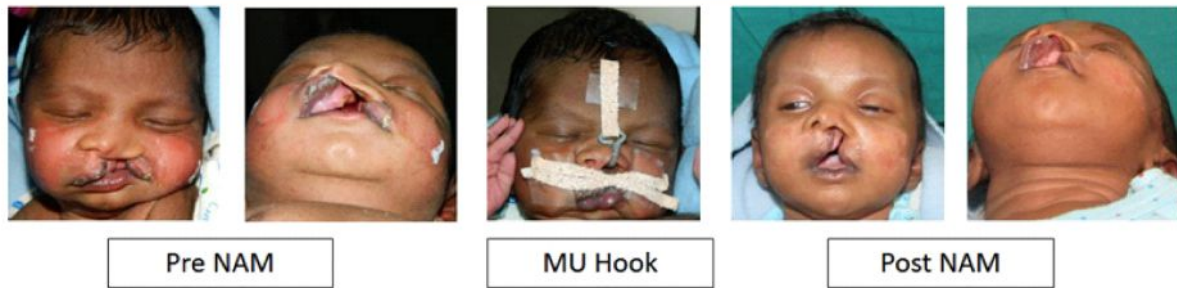Case 2: Unilateral cleft lip and palate on the left side



Case 3: Bilateral cleft lip and palate



Case 4: Bilateral cleft lip and palate



Case 5: Unilateral cleft lip and palate of the right side

One week old baby reported to the department. On Examination patient presented with a bilateral cleft lip and palate with collapsed nostril and insufficient columella. Patient's parents also reported a history of cardiac problems which necessitated the avoidance of any impression making procedures to elude the associated risks. Modified MU hook for bilateral cleft lip and palate with bifurcation was delivered to the patient without any need for impression. All nasal changes were appreciated post NAM with approximation of lip segments. (Fig 4)

Case 4

10 days old baby reported to the department presenting with bilateral cleft lip and palate. On examination, the premaxilla was seen to be rotated to the left due to the presence of Simonart band. This presentation would have made the NAM plate unstable hence commanding MU Hook treatment which was carefully delivered and an assymetric taping was done to correct the midline. The Post NAM lip segments were approximated, with proper orientation of premaxilla and lengthening of columella. (Fig 5)

Case 5

A 15 days old baby reported with unilateral cleft lip and palate of the right side with collapsed nostrils. Patient had to travel a very long distance to avail any kind of cleft related health services. Unlike a conventional NAM acrylic plate which would require reactivation every 2 weeks, a MU Hook would have a distant advantage of less frequent recall schedule. MU hook could easily be placed and removed by the parents themselves reducing the burden of care. Nasal changes with approximation of lip segments were appreciable post treatment. (Fig 6)

CONCLUSION

The MU hook offers myriad merits over the conventional PNAM such as greater compliance of infants, reduced frequency of visits and minimum laboratory work. In addition it obviates the need for impression making as no

moulding plate is used and therefore can be used in CVS patients. It is versatile and can be used in both unilateral and bilateral CLP cases. The MU Hook is hence a boon intreating CLP patients and increases their comfort and wellbeing.

REFERENCES

1. Elavenil P, Murugavel C, Kannadasan K, Krishnakumar Raja VB, Gnanam A, Kanimozhi G, *et al.* Folic acid in cleft lip, alveolus and palate prevention: Awareness among dental professionals. *Indian J Dent Res* 2010;21: 360-3
2. Grayson BH, Cutting C, Wood R. Preoperative columella lengthening in bilateral cleft-lip and palate. *PlastReconstr Surg*. 1993;92:1422-3
3. Dubey RK, Gupta DK, Chandraker NK. Presurgicalnasoalveolarmolding: A technical note with case report. *Indian J Dent Res Rev* 2011;2:66-8
4. Matsuo K, Hirose T. Nonsurgical correction of cleft lip nasal deformity in the early neonate. *Ann Acad Med Singapore* 1988;17:358-65
5. Ezzat CF, Chavarria C, Teichgraeber JF, Chen JW, Stratmann RG, Gateno J, *et al.* Presurgicalnasoalveolarmolding therapy for the treatment of unilateral cleft lip and palate: A preliminary study. *Cleft Palate Craniofac J* 2007;44:8-12.
6. Shetty V, Vyas HJ, Sharma SM, Sailer HF. A comparison of results using nasoalveolar moulding in cleft infants treated within 1 month of life versus those treated after this period: Development of a new protocol. *Int J Oral MaxillofacSurg* 2012;41:28-36.
7. Spengler AL, Chavarria C, Teichgraeber JF, Gateno J, Xia JJ. Presurgicalnasoalveolarmolding therapy for the treatment of bilateral cleft lip and palate: A preliminary study. *Cleft Palate Craniofac J* 2006;43:321-8
8. Yang S, Stelnicki EJ, Lee MN. Use of nasoalveolarmolding appliance to direct growth in newborn patient with complete unilateral cleft lip and palate. *Pediatr Dent* 2003;25:253-6
9. Grayson BH, Maull D. Nasoalveolarmolding for infants born with clefts of the lip, alveolus, and palate. *ClinPlastSurg* 2004;31: 149-58, vii.