

DISTRCTION OSTEOGENESIS FOR CORRECTION OF MANDIBULAR DEFORMITY ATTRIBUTABLE TO TMJ ANKYLOSIS A CASE REPORT

Neelesh Ganesh^a, Jayanti^b, Anand K Patil^c, Roopak D Naik^d

INTRODUCTION

TMJ ankylosis is the leading cause of acquired mandibular deficiency seen in the pediatric age group. Although acquired mandibular deficiency has a multifactorial etiology, it is usually caused by trauma and infection in the pediatric age group. TMJ ankylosis if left untreated for a long time damages the condyle and alters the growth of the mandible, often manifested as deficiency of the mandibular body and ramus.¹ For patients presenting with ankylosis of TMJ accompanied with micrognathia, the treatment modality is often carried out in two parts. Ankylosis of the TMJ which often leads to trismus, can be managed by gap arthroplasty or by reconstruction of the TMJ^{2,3,4}, while the subsequent micrognathia can be treated by autoplasmic bony transplantation or distraction osteogenesis.⁵

Distraction osteogenesis for treatment of micrognathia due to ankylosis of TMJ was first reported in 1999.^{6,7} In the recent times distraction osteogenesis (DO), has become an important alternative surgical technique for treatment craniofacial deformities. It is the process of inducing new bone formation between surgically divided bone segments. It utilizes the body's natural defense mechanism for bone formation by inducing callus formation which is gradually stretched at a certain interval and rate. Mandibular DO (MDO) is frequently performed in young children and adults with congenital craniofacial skeletal deformities including mandibular asymmetry corresponding to various syndromes as well as severe micrognathia seen due to with ankylosis of the temporomandibular joint (TMJ). Mandibular DO not only helps to elongate the mandible by gradual bone lengthening but also improves function, and enhances the soft tissue profile.

This case report presents the results of gap arthroplasty and mandibular distraction osteogenesis in a patient with facial asymmetry and unilateral TMJ bony ankylosis.

DIAGNOSIS AND ETIOLOGY

A 12 year old patient reported to the department of Orthodontics, SDM Dental College and Hospital, with chief complaint of facial asymmetry and backwardly placed jaw. The patient gave a medical history of TMJ ankylosis of left side for which she was operated a year ago. Surgical release of fibrous ankylosis with gap arthroplasty was carried out which improved the mouth opening. No family history of craniofacial deformities. The clinical and radiographic examination indicated right hemi facial microsomia with small temporomandibular joint and ramus.

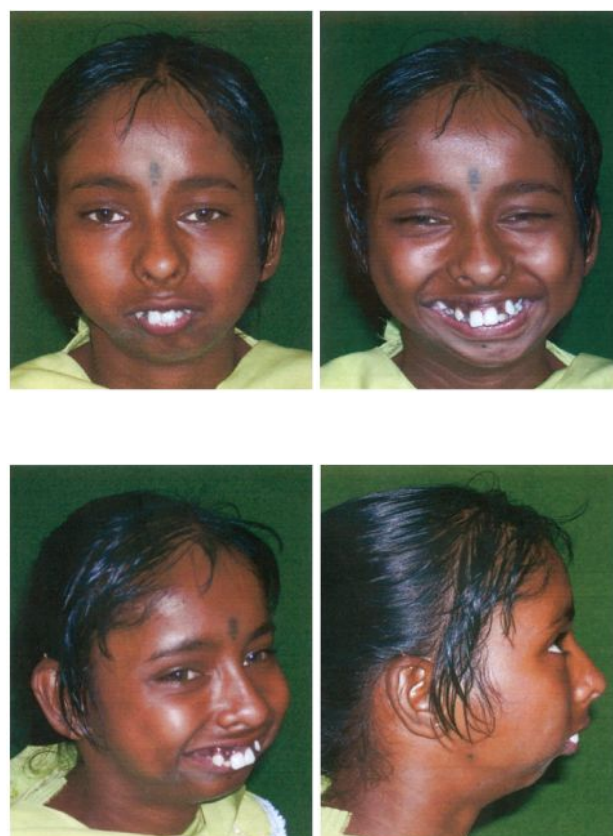

Fig A. Pre treatment Extraoral photographs

^aSpecialist Orthodontist, Al Reef Medical and Orthodontic Clinic Emirates Hospital Group, Ras al khaimah, United Arab Emirates

^bPost graduate student, Department of orthodontics, SDMCDSh, DHARWAD

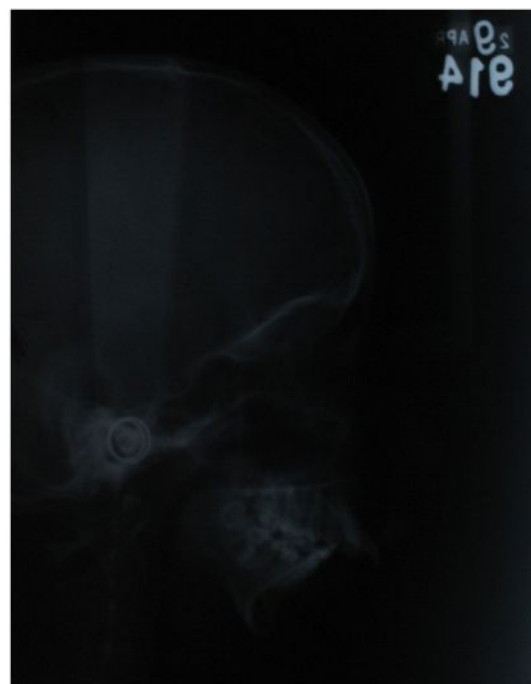
^cHOD, Professor M Orth RCS(Edinburgh) Department of orthodontics SDMCDSh, DHARWAD

^dAssociate Professor Department of orthodontics, SDMCDSh, DHARWAD Department of orthodontics, SDMCDSh, DHARWAD Department of orthodontics, SDMCDSh, DHARWAD

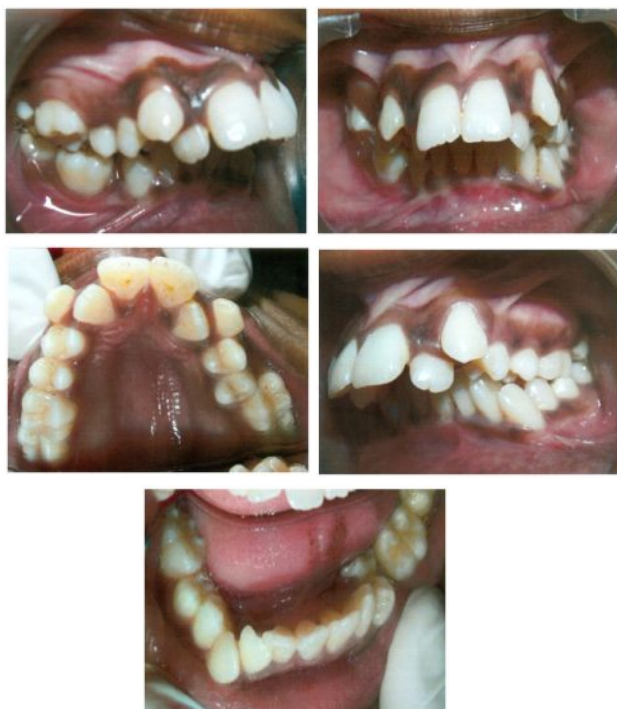

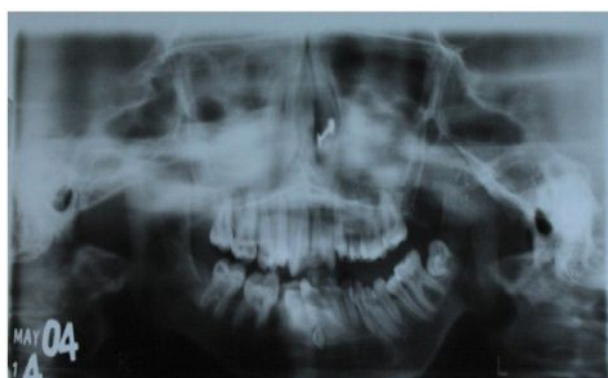Fig B. Pre treatment intraoral photographs

The pre treatment photographs showed that her face was asymmetrical with a mildly undeveloped chin which was shifted to the left. In addition the lower facial height was decreased with proclined upper anteriors and incompetent lips. In profile view, a convex profile with retrusive chin was seen. (Figure A) The intraoral examination showed a V-shaped maxillary arch with upper anterior crowding with a midline deviation of 7mm to the left, a severe Class II canine and molar relationships, with an overjet of 15mm and an overbite of 6mm. (Figure B).



Pre treatment radiographs

Cephalometric Readings (Table1)

	Pre treatment		Post treatment	
Skeletal				
SNA(°)	72		74	
SNB(°)	61		65	
ANB(°)	16		9	
Sn Go Gn(°)	48		65	
Wits(mm)	20		16	
Saddle Angle(°)	130		109	
Post cranial base	27		23	
Dental				
U1 to SN(°)	105		92	
U1 to NA(°)	35, 8mm		19, 3mm	
U1 to APog(°)	67, 20mm		40, 14mm	
L1 to MP(°)	107		77	
L1 to NB(°)	38, 12mm		26, 15mm	
L1 to APog(°)	22, 2mm		15, 9mm	
Interincisal(°)	91		126	
SOFT TISSUE				
E line	U +8	L+8	U 0	L+9
H line	L +3		L +3	
S line	U +8	L+8	U +5	L+12

(° referring to degrees)

The lateral cephalometric analysis indicated severe skeletal Class II sagittally with hyperdivergent jaw bases with an SNA angle of 72deg, an SNB angle of 61deg and an ANB angle of 16deg. The maxillary incisors were labially inclined at an angle of 105deg to the SN plane and an interincisal angle of 91deg. The upper and lower lips were protrusive with respect to the E line. (Table 1) The panoramic radiograph showed differences in the sizes of the ramus and mandibular body length with an obvious chin deviation to the left and underdeveloped angle of mandible.

TREATMENT OBJECTIVES

Because of the hemifacial microsomia on the right side, the patient expressed concern about her facial asymmetry. The treatment for this patient was intended to provide functional reconstruction of the ankylosed TMJ joint to restore the facial profile and to establish a functional occlusion. Thus, the treatment objectives were established as follows:

- (1) correct the patient's facial asymmetry by lengthening the affected ramus and coordinate the facial, maxillary and mandibular dental midlines
- (2) correct the skeletal Class II antero posterior jaw relationship
- (3) coordinate the widths of the dental arches
- (4) achieve dental Class I canine and molar relationships and
- (5) relieve the proclined incisor position and achieve an ideal overjet and overbite relationship.

TREATMENT ALTERNATIVES

Based on treatment objectives, the following treatment alternatives were considered

- (1) maxillary and mandibular orthognathic surgery with anteroposterior impaction, with or without segmental surgeries
- (2) maxillary orthognathic surgery with anteroposterior impaction, with or without segmental surgeries, and distraction osteogenesis to advance the mandibular body and lengthen the shorter ramus
- (3) combined orthodontic treatment, with or without extraction of the 4 first premolars, and distraction osteogenesis.

TREATMENT PLAN AND RATIONALE

Taking into consideration the patient's concern with facial asymmetry and the severe mandibular deficiency, it was decided to treat the patient with orthodontic treatment combined with distraction osteogenesis. Pre surgical orthodontics was planned to alleviate the severe crowding and co-ordinate upper and lower arches to facilitate distraction. It was decided to expand the narrow upper arch to alleviate the severe crowding and create adequate overjet to facilitate mandibular advancement. To begin with the maxillary arch was expanded by Hyrax appliance for a duration of 8 months. Post expansion the first premolars were extracted in both upper and lower arch to relieve crowding and create adequate overjet.

TREATMENT PROGRESS

Post expansion with Hyrax for 8 months, the patient was treated with a pre adjusted edgewise appliance, MBT(Ormco) 0.022" slot. The treatment followed a progression of widened archwires starting from 0.016" nickel titanium to 0.019"x0.025" stainless steel. Similar arch wire sequence was followed in the lower arch. After alleviation of crowding in both the arches and closure of spaces and creation of sufficient overjet, surgical phase of treatment was planned.

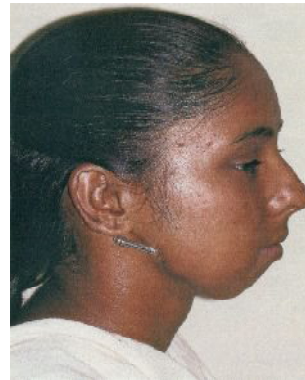

Figure C. Extraoral photograph showing internal distractor

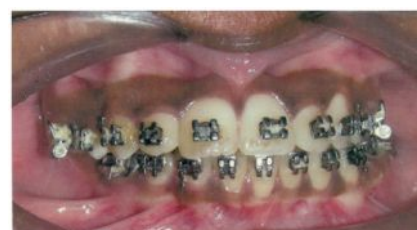
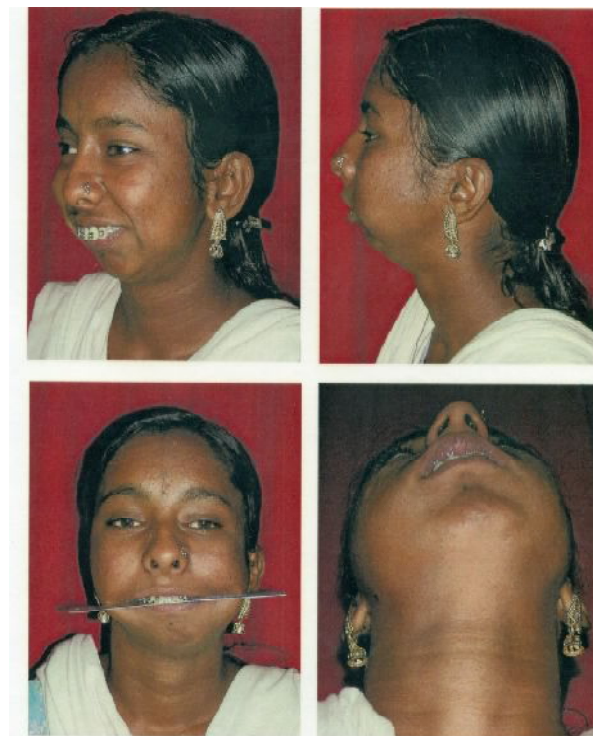
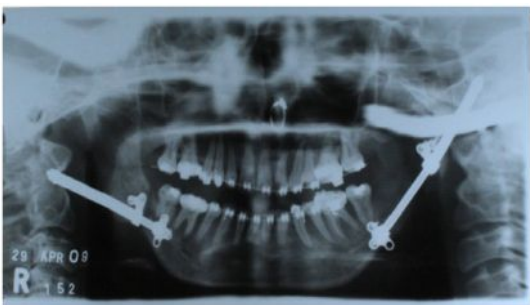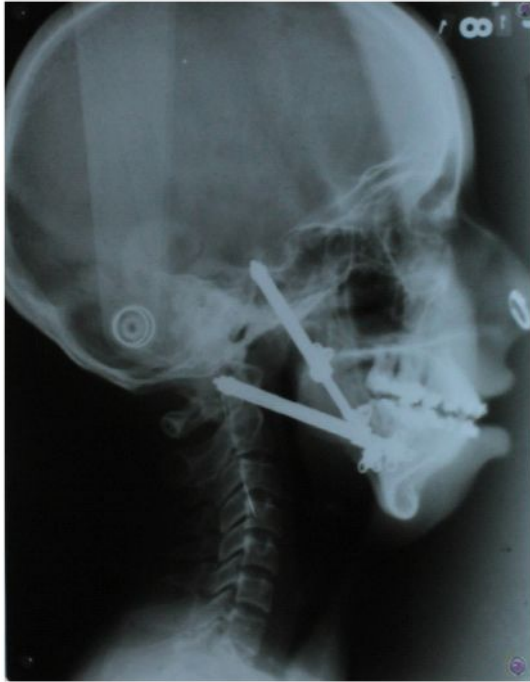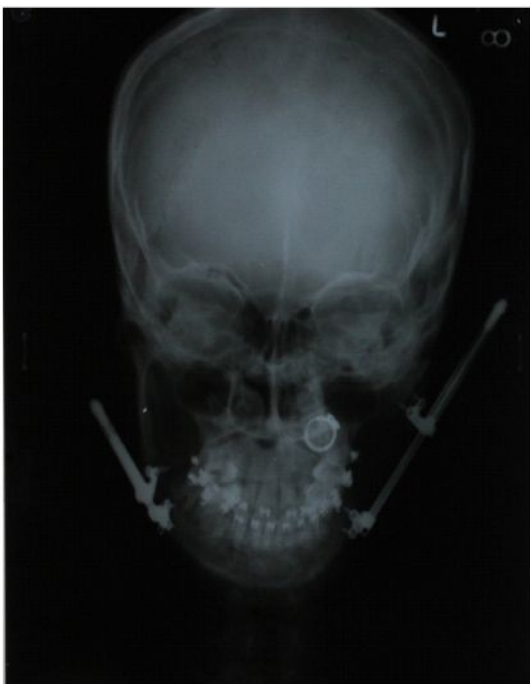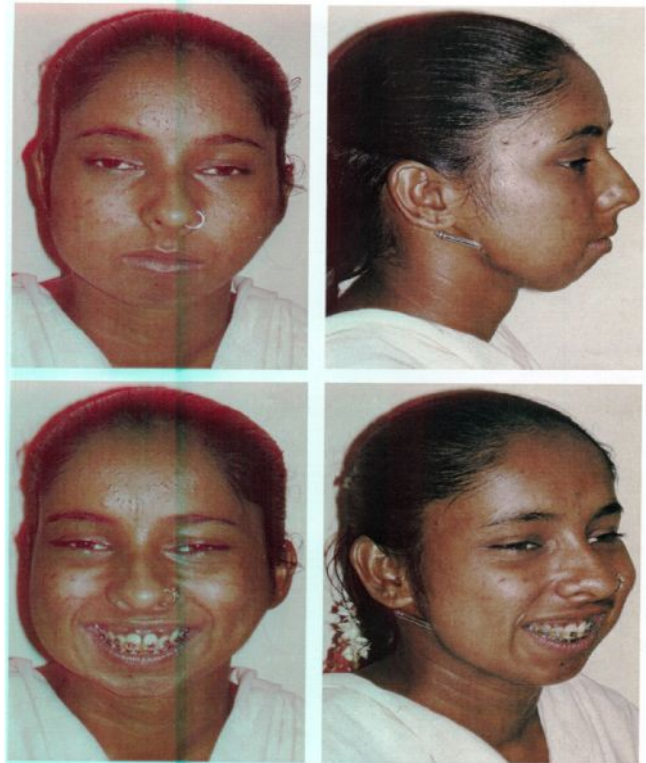Figure D. Pre Surgical photographs



Radiographs showing placement of distractors



Radiographs showing placement of distractors



Before removal of distractor

Extra oral photographs before removal of distractors

The duration of the pre surgical phase was for 12 months. The patient was hospitalized, and surgery for the distraction osteogenesis was performed under general nasotracheal anesthesia through an intraoral incision, a horizontal ramus osteotomy was performed on either side at the level of the occlusal plane. The distractor was placed with a vector parallel to the posterior border of the ramus. After 7 days of latency, the distraction device was activated by 1mm per day for 30 days, until the mandibular midline deviation was overcorrected and adequate mandibular lengthening was achieved. After the distraction phase of almost 4 weeks adequate time of 3 months was given for consolidation and remodeling. The status of the callus was evaluated during this period radiographically. The mandibular position appeared stable post surgically.

DISCUSSION AND CONCLUSION

Mandibular deformity in the pediatric age group due to temporo mandibular ankylosis is commonly caused due to trauma or infection, as the articular cartilage is highly susceptible to injury in this age group (Heggie, 1996). Ankylosis in children manifests as progressive trismus and mandibular deformity with retrognathia and lateral displacement of the chin. Reconstruction of temporo mandibular joint in an ankylosed TMJ has been routinely done by gap arthroplasty (Roychoudhury et al 1999), interposition arthroplasty (Sawhney, 1986) and costo

chondral graft interposition (Ko et al 1999). Costo chondral graft interposition has shown a potential for growth of the mandible (Lello, 1990).¹ Due to the biologic and anatomical consideration, bone graft appears to be a favourable treatment modality in cases of TMJ ankylosis. However bone grafting has its own disadvantages like the need for an additional operation, infection and pain at the donor site, danger of benefactor site and probability of resorption of the grafted bone. Furthermore, bone grafting for augmentation requires adequate volume of soft tissue to prevent surgical site infection by obtaining water tight tension free closure.⁸ In children, the use of gap arthroplasty in conjunction with distraction osteogenesis is favoured. This technique makes the correction of mandibular hypoplasia also possible while the other techniques do not address the problem of severe mandibular deformity.¹

Distraction Osteogenesis can be defined as a procedure of inducing new bone formation between the surgically fragmented bone segments. These bone segments respond biologically by inducing callus formation which is gradually differentiated in response to incremental traction.⁹

The first bone distraction procedure was reported by a British scientist Codivilla for the treatment of reduced/shortened femur bone.¹⁰ Ilizarov carried out extensive research on this technique for bone lengthening in the lower extremity. Thus it was only in 1954 that distraction osteogenesis drew attention due to its encouraging clinical results.¹¹ However for many years, distraction osteogenesis was restricted to treatment of long bones until Synder¹² introduced it in orthodontics to lengthen mandible with the help of an external fixator. Further major contribution was done by McCarthy in 1990s for his extensive work on distraction osteogenesis in the mandible of patients with one-sided craniofacial microsomia and related disorders.^{13,14,15}

Mandibular lengthening acquired by gradual distraction results in expansion of mandibular bony tissues as well as gradual accommodation of corresponding muscles and the surrounding soft tissues. The physiological forces produced and transformed by the distractor on the mandible thus help in coordinated and harmonic development of the muscle, the surrounding soft tissues while obtaining proper occlusion and esthetic.¹⁶

However, in case of conventional mandibular advancement using osteotomies and bone grafts in similar patients, the results are likely to be unstable as the muscle envelope assumes a role in relapse. Whereas using distraction osteogenesis, all the tissues from skeleton to skin are gradually stretched and lengthened at the same time along with the osteotomy site resulting optimum aesthetic and stable outcome.¹⁷ Most importantly, the direction, course and amount of bone lengthening might be controlled alongside lengthening of soft tissues, also the degree of

advancement achieved is better than conventional methods.¹⁸

Throughout distraction osteogenesis, physiological histogenesis happens in the surrounding tissues including the gingiva, blood vessels, ligaments, cartilage, muscle and nerve.^{19,20} Although the same degree of precision might not be possible as in orthognathic surgery, DO is more effective with larger movements because of the gradual stretching and adaptation of the soft tissues leading to an expansion of the soft tissue envelope (distraction histogenesis).²¹

However, the debate does not in any way undermine the integrity of conventional orthognathic procedures, but only highlights its limitation towards patient selection. Certain cases requiring mild to moderate skeletal corrections can be best managed using orthognathic surgical approaches that offer immediate correction with minimal hospitalization.

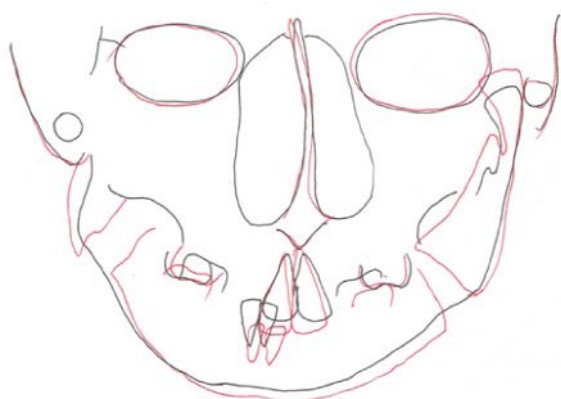
Distraction osteogenesis appeared to be the best treatment plan in this case after taking all factors into consideration. Post treatment results showed excellent esthetics with good facial symmetry, improvement in profile and good chin projection established. The patient's mouth opening was significantly improved as was her speech and other functions. Nose symmetry was established even though no rhinoplasty was performed. Patient was happy with the improvement in facial esthetics. (Figure E,F)

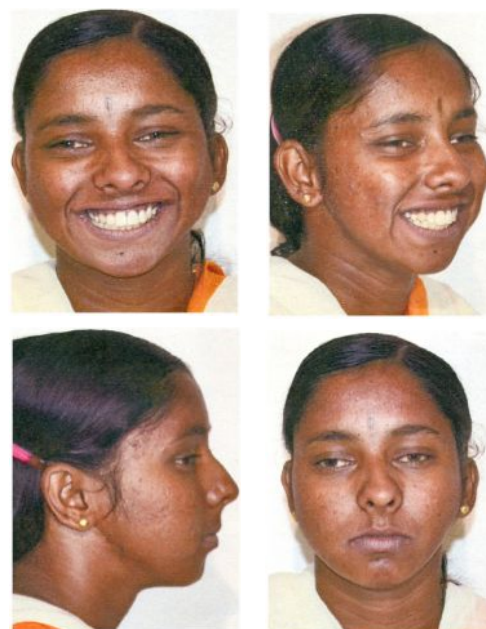

Figure E. Post treatment Extraoral photographs

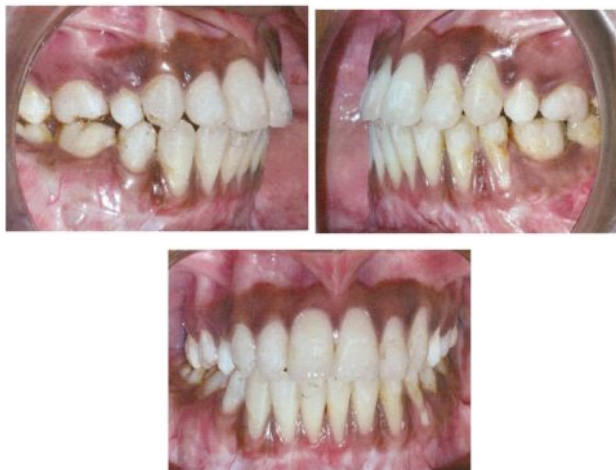

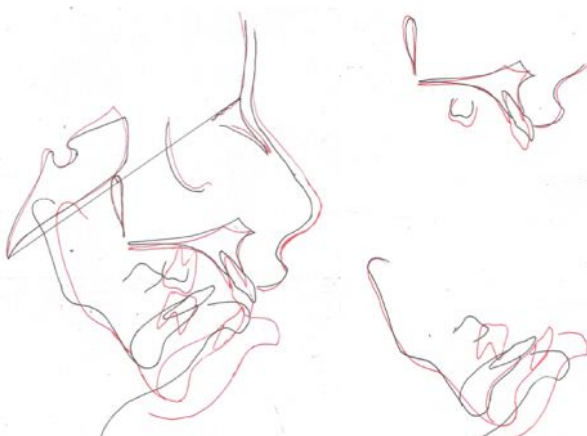Figure F. Post treatment intraoral photographs



- pre treatment superimposition

- post distraction superimposition

Cephalometric superimposition



Over all superimposition
on Basion-Nasion at CC
point.

Maxillary superimposition
on ANS-PNS at ANS.
Mandibular
superimposition on
symphysis

CONCLUSION

Distraction osteogenesis with gap arthroplasty appears to be an effective and useful technique for the management of mandibular deformity with temporomandibular joint ankylosis. Distraction osteogenesis is a judicious treatment option whenever a larger bony advancement is desired and it holds a special relevance in the pediatric age group. In this particular case extensive bone lengthening was achieved with proper occlusion and a coordinated soft tissue balance.¹

REFERENCES

1. Rao K, Kumar S, Kumar V, Singh A, Bhatnagar S. The role of simultaneous gap arthroplasty and distraction osteogenesis in the management of temporo-mandibular joint ankylosis with mandibular deformity in children. *Journal of CranioMaxillofacial Surgery* 2004;32(1):38-42.
2. Chidzonga MM. Temporomandibular joint ankylosis: review of thirtytwo cases. *Br J Oral Maxillofac Surg* 1999;37:123-6.
3. Medra AM. Follow up of mandibular costochondral grafts after release of ankylosis of the temporomandibular joints. *Brit J Oral Maxillofac Surg* 2005;43:118-22.
4. Donkor P, Acheampong AO. Intra-articular ramus osteotomy combined with costochondral grafting for the treatment of recurrent ankylosis of the mandible. *Br J Oral Maxillofac Surg* 2006;44:497-500.
5. Hongbo Yu, Guofang Shen, Shilei Zhang, Xudong Wang. Gap arthroplasty combined with distraction osteogenesis in the treatment of unilateral ankylosis of the temporomandibular joint and micrognathia. *Br J Oral Maxillofac Surg* 2009;47: 200-204.
6. Dean A, Alamillos F. Mandibular distraction in temporomandibular joint ankylosis. *Plast Reconstr Surg* 1999;104:2021-31.
7. Papageorge MB, Apostolidis C. Simultaneous mandibular distraction and arthroplasty in a patient with temporomandibular joint ankylosis and mandibular hypoplasia. *J Oral Maxillofac Surg* 1999;57:328-33.
8. Khan A, Fareed W, Tandon P, Zafar M. Distraction osteogenesis for correction of post ankylosis mandibular deformities. *Journal of Biomedical Research* 2015; 29(4):332-336.
9. Samchukov ML, Cope JB, Cherkashin AM. *Craniofacial distraction osteogenesis*. 1st ed. London: St.Louis, Mosby Inc. 2001.
10. Codivilla A. On the means of lengthening, in the lower limbs, the muscles and tissues which are shortened through deformity. *J Bone Joint Surg* 1905;2(4): 353-369.
11. Ilizarov G. A new principle of osteosynthesis, using cross wires and rings. *Sb Nauchn Rab Kurgan Obi Nauchn Med Ova* 1954:146-160.
12. Snyder CC, Levine GA, Swasson HM, et al. Mandibular lengthening by gradual distraction: preliminary report. *Plast Reconstr Surg* 1973;51(5):506-508.
13. McCarthy JG. The role of distraction osteogenesis in the reconstruction of the mandible in unilateral craniofacial microsomia. *Clin Plast Surg* 1994;21(4):625-631.
14. McCarthy JG, Schreiber J, Karp N et al. Lengthening the human mandible by gradual distraction. *Plast Reconstr Surg* 1992;89(1):1-10.
15. Lopez EN, Dogliotti PL. Treatment of temporomandibular joint ankylosis in children: is it necessary to perform mandibular distraction simultaneously?. *J Craniofac Surg* 2004;15(5):879-884.
16. Gonzalez M, Egbert M, Guerrero CA et al. Vertical and horizontal mandibular lengthening of the ramus and body. *Atlas Oral Maxillofac Surg Clin* 2008;16(2): 215-236
17. Sato M, Maruoka Y, Kunimori K et al. Morphological and immunohistochemical changes in muscle tissue in association with mandibular distraction osteogenesis. *J Oral Maxillofac Surg* 2007;65(8):1517-1525.
18. Yoon H, Kim H. Intraoral mandibular distraction osteogenesis in facial asymmetry patients with unilateral temporomandibular joint bony ankylosis. *Int J Oral Maxillofac Surg* 2002;31(5):544-548.
19. Hawkinson RT. Retrognathia correction by means of an arcing osteotomy in the ascending ramus. *J Prosthet Dent* 1968;20(1):77-86.
20. Liou EJ, Huang CS. Rapid canine retraction through distraction of the periodontal ligament. *Am J Orthodont Dentofac Orthoped* 1998;114(4):372-382.
21. Padmanabhan S, Juvvadi S, Chithranjan A, Ramkumar S, Kumar N. Orthodontic surgical management of a case of severe mandibular deficiency due to condylar ankylosis. *Indian Journal of Dental Research* 2014 ;25(5):667.