



Case Report

Pulmonary hydatid disease

Azmat Kaur Sandhu^{1,*}, Pavneet Kaur Selhi², Ruchita Tyagi²

¹Dept. of Pathology, Government Medical College And Hospital, Chandigarh, India

²Dept. of Pathology, Dayanand Medical College & Hospital, Ludhiana, Punjab, India



ARTICLE INFO

Article history:

Received 09-11-2019

Accepted 11-11-2019

Available online 12-12-2019

Keywords:

Hydatid

Echinococcus granulosus

Echinococcus

ABSTRACT

Hydatid cyst (echinococcosis) is caused by infestation by larval tapeworms of the genus *Echinococcus*. The disease is extensively distributed worldwide, and it has been rarely reported in Punjab, India. Although it is more commonly reported in liver, it is also seen in other organs as well. We describe the cyto - morphological features in a case of pulmonary hydatid cyst in a 22 year female. Computed tomography revealed a solitary nodule in the lower lobe of left lung. The smears showed tegument, hooklets, and laminated membrane.

© 2019 Published by Innovative Publication. This is an open access article under the CC BY-NC-ND license (<https://creativecommons.org/licenses/by/4.0/>)

1. Introduction

Hydatid disease is caused by *Echinococcus granulosus*, which is endemic in the cattle and sheep raising regions of the underdeveloped and developed countries.^{1,2} The prevalence of this disease is high in several countries of the Mediterranean region, mainly in the pastoral areas where the dog-sheep cycle of the parasite exists.³ It continues to remain a health problem in India, mainly in the rural areas of the eastern part of the country. Liver and lungs are the preferred sites of infection, however the other relatively rare anatomic locations include the central nervous system, muscles, subcutaneous tissue, kidneys, bones, and body cavities.¹

Though clinical suspicion coupled with radiological and serological findings are good pointers towards diagnosis; pathological diagnosis remains the gold standard. Long-standing infection presents as an organized, solid, atypical pulmonary nodule which is a mimicker of bronchogenic carcinoma.⁴ Image guided fine needle aspiration cytology (FNAC) is a useful tool for diagnosis.⁵

2. Case Report

We report the case of a 22 year old immunocompetent non-smoker female who presented with cough and with no other co-morbidity or past history of tuberculosis.

The provisional clinical diagnosis was tuberculosis while the radiological diagnosis was suspicious of malignancy.

Computed tomography revealed a solitary nodule in the left lower lung lobe which was suspicious of malignancy (Figure 1).

A CT guided FNAC was performed from the lung nodule under aseptic precautions. Direct air-dried smears from the aspirated clear fluid material were stained with May-Grünwald-Giemsa (MGG), and alcohol-fixed smears were stained with the Papanicolaou stain and hematoxylin and eosin.

The aspirate showed scolices with rendered laminated membrane fragments and plenty of pathognomonic hooklets in the background of the inflammatory cell reaction seen as neutrophils, eosinophils, lymphocytes, histiocytes, plasma cells, necrotic debris, erythrocytes, foamy macrophages, and reactive bronchiolar epithelial cells. The cell block preparation showed the laminated membrane. A cytological diagnosis of Pulmonary hydatid cyst was made. Positive echinococcal serology supported the diagnosis. The patient

* Corresponding author.

E-mail address: azmatsandhu13@gmail.com (A. K. Sandhu).

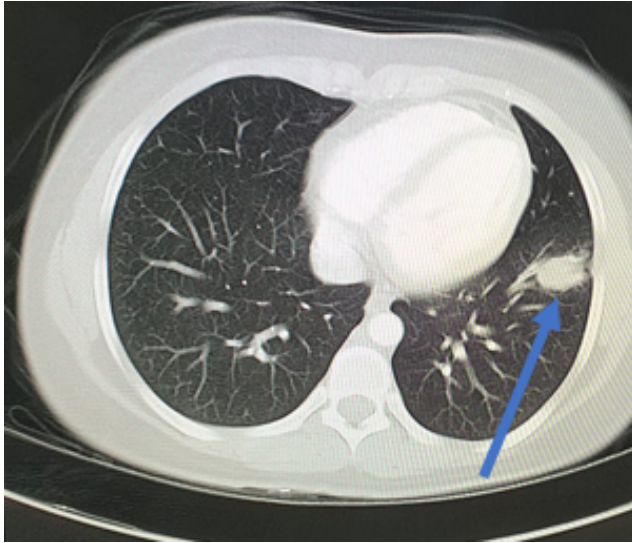


Fig. 1: CT image showing solitary nodule in left lung

showed remarkable clinical and radiological improvement after three cycles of albendazole and did not require a surgical procedure.

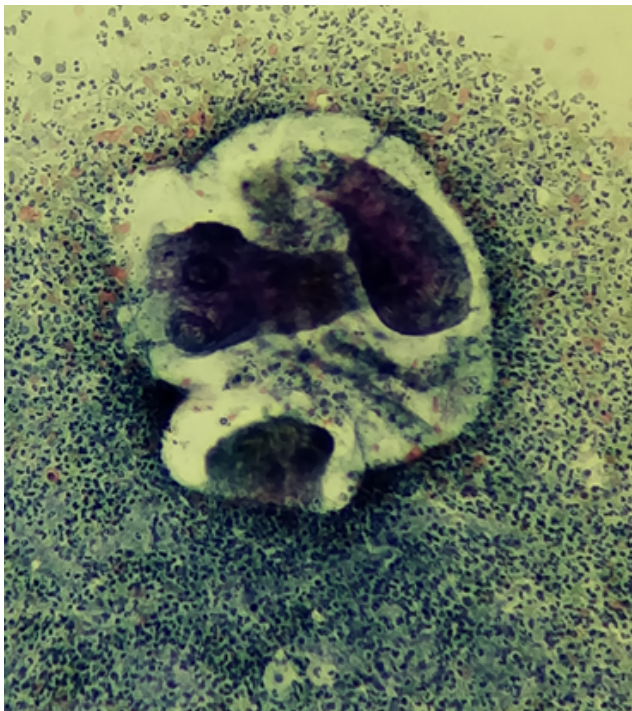


Fig. 2: Intact protoscolices of *Echinococcus granulosus* (PAP stain, 100X)

3. Discussion

Hydatid disease is a chronic parasitic zoonotic infection in humans, which is transmitted between dogs and domestic

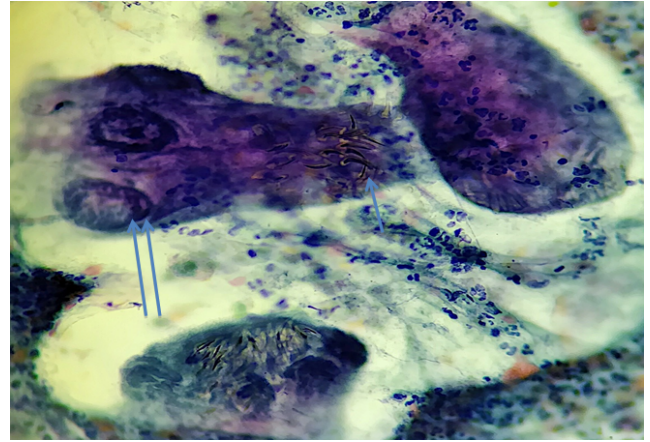


Fig. 3: Intact protoscolices containing radially arranged hooklets (arrow) and suckers (double arrow). Hooklets display characteristic scimitar (curved single edged sword) shaped. (PAP stain, 400X)

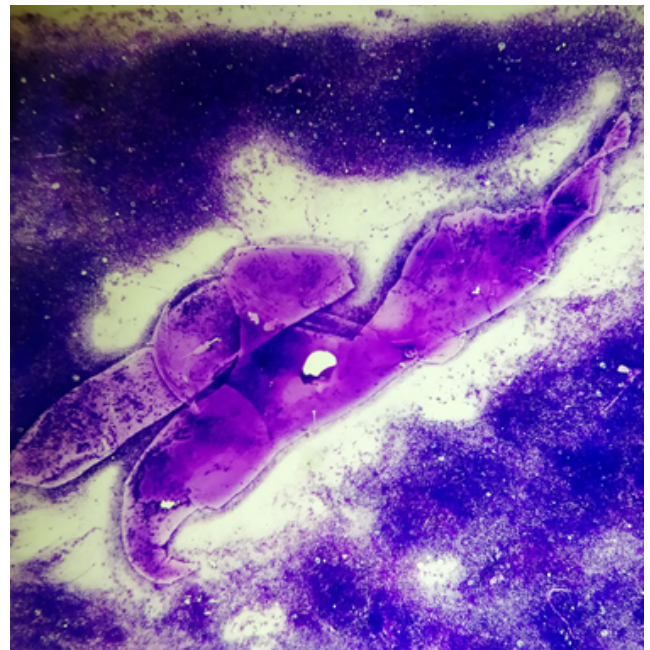


Fig. 4: Laminated membrane structures (MGG stain, 100X)

livestock, particularly sheep.² It is an important health problem not only in developing and agricultural reliant countries, but also in industrialized countries due to influx of immigrants.¹

Most of the patients are asymptomatic, but it can produce non-specific symptoms, like, cough, chest pain, and hemoptysis depending on the localization and the size of the focus.⁶ The complicated and ruptured cysts present with systemic manifestations like fever, fatigue, and weight loss.

The lungs are the second most common site of involvement next to liver. The diagnosis of pulmonary

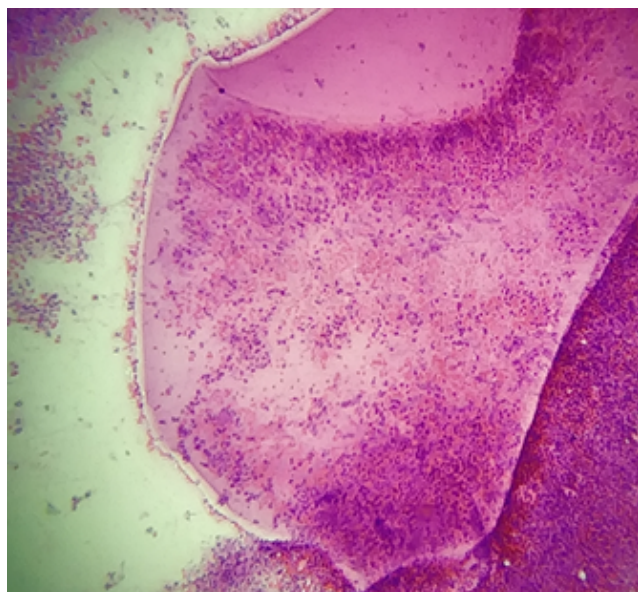


Fig. 5: Germinal membrane with surrounding inflammatory cells seen as neutrophils, lymphocytes and foamy macrophages. (H&E stain, 100X)

hydatid cyst is based on the clinical and radiological findings, as well as serological analysis (echinococcosis Eliza IgG test). FNAC is generally not preferred, and generally contraindicated due to fear of an untoward allergic reaction and dissemination following the procedure unless the presentation of the disease is atypical.⁷⁻¹⁰

Longstanding pulmonary infection may present with a solid and solitary nodule, which may clinically and radiologically mimic malignancy like in our case. In this situation, FNAC can be considered to reach the diagnosis.

Diagnostic cyto- morphological features of hydatid cyst include presence of laminated cyst wall fragments (also called cuticula), scolices, and hooklets. Identification of hooklets is pathognomonic, but observation of laminated membranes by itself is a presumptive finding in the cytodiagnosis of hydatid cyst.¹¹

A background of inflammatory cell reaction with necrotic debris, foreign body giant cells, hemosiderin-laden alveolar macrophages is also seen. But this infiltrate by itself is not diagnostic.⁹ These findings were present in our case.

Hydatid disease is endemic mainly in the rural areas of the eastern part of India. In the western parts of the country, including Punjab, the disease is rare.

Fine needle aspiration cytology is a useful, rapid, and diagnostic technique for the diagnosis of an organized form of pulmonary hydatid cyst, which clinically mimicks a malignancy. No post aspiration adverse reactions were reported in the FNAC of such cases.⁸⁻¹²

One should keep in mind the possibility that carcinoma may rarely have clinical, radiological, and serological

features, similar to those of hydatid cyst. Singh N, et al. reported a case of a large cell type lung carcinoma mimicking pulmonary HD, with a positive serological test for *Echinococcus granulosus*.¹³ FNAC was not done in this case, and the histopathological diagnosis of carcinoma was made on the surgical specimen. The possible antigenic similarity between lung carcinoma and hydatid cyst was also reported.¹⁴

In conclusion, our primary aim is to emphasize the importance of considering hydatid disease of the lung in the definite diagnosis of atypical lung lesions such as bronchogenic carcinoma in endemic areas. A high index of suspicion and vigilant scrutiny of slides for parasitic components will allow for correct diagnosis and avert unnecessary surgery and related morbidity.

4. Source of Funding

None.

5. Conflict of Interest

None.

References

1. Raether W, Hanel H. Epidemiology, clinical manifestations and diagnosis of zoonotic cestode infections: an update. *Parasitol Res.* 2003;91:412–438.
2. Craig PS, Larrieu E. Control of cystic echinococcosis / hydatidosis. *Adv Parasitol.* 2006;61:443–508.
3. Sismek S, Balkaya Y, lu EK. Epidemiological survey and molecular characterization of *Echinococcus granulosus* in cattle in an endemic area of eastern Turkey. *Vet Parasitol.* 2010;172:347–349.
4. Kılınc O, Döğkaya M, Sakar A, Yorgancıoğlu A, Halilolar H, et al. Three atypical pulmonary hydatidosis lesions mimicking bronchial cancer from Turkey. *New Microbiol.* 2009;32:229–233.
5. Handa U, Mohan H, Ahal S, Mukherjee KK, Dabra A, et al. Cytodiagnosis of hydatid disease with Horner's syndrome: a case report. *Acta Cytol.* 2001;45:784–788.
6. Tekinbağ C, Turedi S, Gündüz A, Erol MM. Hydatid cyst disease of the lung as an unusual cause of massive hemoptysis: a case report. *J Med Case Rep.* 2009;3:21.
7. Handa U, Mohan H, Ahal S, Mukherjee KK, Dabra A, et al. Cytodiagnosis of hydatid disease with Horner's syndrome: a case report. *Acta Cytol.* 2001;45(6):784–788.
8. Ingram EA, Helikson MA. Echinococcosis (hydatid disease) in Missouri: diagnosis by fine-needle aspiration of a lung cyst. *Diagn Cytopathol.* 1991;7(7):527–531.
9. Das DK, Bhambhani S, Pant CS. Ultrasound guided fine-needle aspiration cytology: diagnosis of hydatid disease of the abdomen and thorax. *Diagn Cytopathol.* 1995;12(8):173–176.
10. Singh A, Singh Y, Sharma VK, Agarwal AK, Bist D. Diagnosis of hydatid disease of abdomen and thorax by ultrasound guided fine needle aspiration cytology. *Indian J Pathol Microbiol.* 1999;42:155–156.
11. Saenz-Santamaria J, Moreno-Casado J, Nunez C, et al. Role of fine-needle biopsy in the diagnosis of hydatid cyst. *Diagn Cytopathol.* 1995;13:229–232.
12. Grkan OU, Topuz Z, Zdemir N, Ekinci C, Numanolu N. Repeated unintentional transthoracic needle aspiration of a pulmonary hydatid cyst. *Scand J Infect Dis.* 2001;33:941–942.
13. Singh N, Srinivas R, Bal A, Aggarwal AN. Lung carcinoma mimicking hydatid cyst: A case report and review of the literature.

Med Oncol. 2009;26:424–428.

14. Yonk WK, Heath DD, Savage T. Possible antigenic similarity between pulmonary carcinoma and cysts of *Echinococcus granulosus*. *Br Med J.* 1979;1:1463–1464.

Pavneet Kaur Selhi Professor

Ruchita Tyagi Assistant Professor

Author biography

Azmat Kaur Sandhu Senior Resident

Cite this article: Sandhu AK, Selhi PK, Tyagi R. Pulmonary hydatid disease. *J Diagn Pathol Oncol* 2019;4(4):338-341.