



Case Report

Ca breast with bell's palsy: a rare presentation

Shabnum Thakur^{1,*}, Manish Gupta¹, Aarti Dhatwalia²¹Dept. of Radiotherapy, Indira Gandhi Medical College, Shimla, Himachal Pradesh, India²Dept. of Pathology, Indira Gandhi Medical College, Shimla, Himachal Pradesh, India

ARTICLE INFO

Article history:

Received 08-11-2019

Accepted 18-11-2019

Available online 12-12-2019

Keywords:

Metastasis

Modified radical mastectomy

Duct cell carcinoma

ABSTRACT

Parotid and cervical lymph nodes are subtle sites for metastasis from breast carcinoma. A 55-year-old female patient of carcinoma breast previously radically treated with chemo-radiotherapy and was on regular follow up conferred to our department with left sided bell's palsy and a swelling in her left parotid region. Through this case, we present the expedient management of advanced breast cancer usher with the parotid gland and cervical lymph node metastasis. As we found this an intriguing case and outlandish and exceptional presentation, oncologists should be aware of the prodigious clinical course for early diagnosis and transcend treatment.

© 2019 Published by Innovative Publication. This is an open access article under the CC BY-NC-ND license (<https://creativecommons.org/licenses/by/4.0/>)

1. Introduction

In the head and neck malignancies, salivary gland tumours, especially metastatic, are unwonted clinical events. Salivary glands itself are deviant for primary malignancies, while secondary metastatic deposits are farther profoundly rare with description of only petty case reports in the literature. Among all Parotid tumours there is 9-14% of metastatic deposited to parotid.¹ Metastasis to the parotid gland from breast cancer is vastly rare, and to our knowledge give an account of only 14 cases between 1982 and 2010.²⁻¹⁰ Squamous cell malignancies of head and neck are the most common site of metastatic deposits to parotid gland, while secondary deposits from primary in infra-clavicular region are barely described. We are reporting a case of invasive duct cell carcinoma of the breast which spread to the parotid gland and cervical lymph nodes with left sided bell's palsy.

2. Case Report

A 55 years old patient presented with lump of size 4x5 cm in left breast with left axillary lymph node of size 3x1cm matted fixed lymph node, staged as IIIB(T_{4a} N_{2a} M_X),

histopathological examination (HPE): duct cell carcinoma, grade II, ER/PR and HER2neu was negative. Patient received CAF based chemotherapy 4 cycles and subjected for surgery (modified MRM), HPE (histopathological examination) s/o invasive duct cell carcinoma, NST Grade II, with all resections margins were negative, LVSI negative. Patient received 4 more cycles of same chemotherapy followed by EBRT to chest wall, axilla and supraclavicular region @ 40 Gy /15#/3weeks. After completion of treatment patient was kept on follow up. After 11 months' patient presented with swelling left parotid region, which was hard and was of size 4x3 cm along with left sided bell's palsy. USG neck was done s/o swelling in left parotid, multiple enlarged Para glandular lymph nodes along with level IB, II, III cervical lymph-nodes largest of size 2x1cm, many lymph nodes showed loss of fatty hilum and they were round. FNAC was done which was suggested of meta static duct cell carcinoma (figure 1). ENT examination was done which was normal. Metastatic workup was done CECT shows only metastatic disease in parotid and cervical region with no local recurrence. Left parotidectomy was done which also shows histopathological proof of metastatic duct cell carcinoma. Patient was started on paclitaxel and cisplatin based chemotherapy thereafter.

* Corresponding author.

E-mail address: thakurshabnum7@gmail.com (S. Thakur).

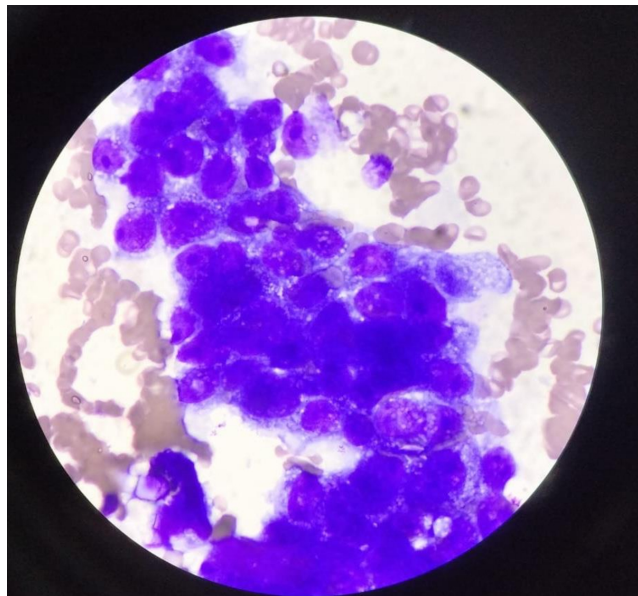


Fig. 1: High power microscopic image; FNAC from cervical lymphnode showing tumour cells in loose cohesive clusters having moderately pleomorphic vesicular nuclei with high N/C ratio, variable prominent nucleoli and abundant vacuolated basophilic cytoplasm

3. Discussion

Invasive ductal carcinoma is the most common histological archetype in carcinoma breast. Predominantly, the obscure loci for lymphatic spread are mediastinal and supraclavicular lymph nodes. Haematogenous spread betides and metastasized to the sites like lung, liver, bone, adrenals, and brain.¹⁰ However, metastasis to the cervical lymph nodes and parotid gland is very unusual finding seen in a course of breast carcinoma. Total number of 167 cases of ca breast were included in an autopsy study review, out of these only 1 case had parotid gland metastatic deposits.¹¹ Also, when we explore literature we found MEDLINE database (1982–2010) who divulged merely 14 cases.^{2–10} Anatomical location may be the one of the reason for the oddity. Also, we know that the parotid is not a principle site for metastasis from infra-clavicular primaries, however it can be a site of spread from head and neck primary neoplasms. Para-glandular lymph nodes, intraglandular lymphatics, and parenchyma are the partite of parotid gland and sites for spread. The para-glandular and intra-glandular lymphatics are trivial sites for metastasis from squamous cell carcinoma and melanoma of the scalp, ear, and the forehead via direct lymphatics. Contrarily, parenchymal metastasis is considered to ponders via haematogenous rather than lymphatic spread.^{11,12} Howbeit, meagre reports documents which domain of the parotid gland is afflicted by metastasis most commonly, however the metastatic process remains to be explicated. According to an article,¹³ 11 of the 14 patients had left parotid gland metastasis (5 primary

breast carcinomas in the left and 5 in the right breast; 1 case unknown), and 3 case metastasized to right parotid gland (1 primary in the left and 2 in the right breast). On account of, 5 (45.5%) of the 11 patients with left parotid involvement had a primary carcinoma in the right breast, it is most likely that the spread accrued via haematogenous as opposed to direct lymphatic metastasis.^{2–10} In spite of definitive treatment, in our case, the patient experienced relapse 11 months after chemotherapy, radiotherapy and surgery. For the treatment of this metastasis, parotidectomy, radiation, chemotherapy was administered. Regardless of the metastatic pathway, generalized treatment such as chemotherapy and hormone therapy is needed. Because immunohistochemical analysis in our case had revealed the tumour to be negative for estrogen and progesterone and HER2 receptors, we continued to administer cisplatin and paclitaxel based chemotherapy postoperatively. The case presented here had presented with swelling in parotid region with VIIth cranial nerve palsy, which was an atypical presentation. Oncologists should keep in mind that the clinical course or imaging findings are not always in line with common patterns. Rare presentations such as in our case are possible, and we should always strive for a histopathologic diagnosis.

4. Source of funding

None.

5. Conflict of interest

None.

References

1. Batsakis JG. Pathology consultation: parotid gland and its lymph nodes as metastatic sites. *Ann Otol Rhinol Laryngol.* 1983;92:209–210.
2. Wiesel JM, Weshler Z, Sherman Y, Gay I. Parotid gland metastatic carcinoma of breast origin. *J Surg Oncol.* 1982;20:227–230.
3. Bissett D, Bessell EM, Bradley PJ, Morgan D, Mckenzie CG. Parotid gland from metastasis of the breast. *Clin Radiol.* 1989;40:309–310.
4. Boizas EC, Gutierrez AR, Herrera AM, Carreras PS. Metastasis of breast carcinoma in parotid. A case report and review of the literature. 1995;46:391–393.
5. Joyce MR, Awad ZT, Saleem T, Salmo EN, Gorm-Ley M, Given HF. The parotid gland: an unusual site of metastasis from carcinoma of breast. *Ir J Med Sci.* 2000;169:230.
6. Szymanski M, Siwiec H, Olszanski W, Golabek W. Parotid metastases from breast cancer. *Wiad Lek.* 2002;55:494–497.
7. Zhang JZ, Gu M. Malignant phyllodes tumor of the breast metastatic to the parotid gland diagnosed by fine needle aspiration biopsy. A case report. *Acta Cytol.* 2003;47:253–258.
8. Perez-Fidalgo JA, Chirivella I, Laforga J, Colio JM, Blanes MD, et al. Parotid gland metastasis of a breast cancer. *Clin Transl Oncol.* 2007;9:264–265.
9. Laforga JB, Gasent JM. Mammary invasive duct carcinoma metastatic to parotid gland: report of a case diagnosed by fine-needle aspiration. *Diagn Cytopathol.* 2009;37:154–158.
10. Dangore-Khasbage SB, Degwekar SS, Bhowate RR, Bhake A. Metastatic involvement of parotid from carcinoma of the breast: a case

report. *Oral Maxillofac Surg.* 2009;13:49–53.

11. Graham JW. Metastatic cancer in the parotid lymph nodes. *Med J Aust.* 1965;2:8–12.
12. Coulthard SW. Metastatic cancer in the parotid gland. *Otolaryngol Clin North Am.* 1977;10:437–442.
13. Ando K, Masumoto N, Sakamoto M, Teraoka K, Suzuki T, et al. Parotid Gland Metastasis of Breast Cancer: Case Report and Review of the Literature. *Breast Care*;6(6):471–473.

Manish Gupta Professor

Aarti Dhatwalia Junior Resident

Cite this article: Thakur S, Gupta M, Dhatwalia A. Ca breast with bell's palsy: a rare presentation. *J Diagn Pathol Oncol* 2019;4(4):335-337.

Author biography

Shabnum Thakur Senior Resident