



Case Report

Isolated primary endometrioid carcinoma of the ovary an unusual case of malignancy

Kafil Akhtar^{1,*}, Mohd. Talha¹, Mohd. Saquib¹, Shahid A Siddiqui²¹Dept. of Pathology, Search Results Web results J. N. Medical College - Aligarh Muslim University, Aligarh, Uttar Pradesh, India²Dept. of Radio Theology, J. N. Medical College - Aligarh Muslim University, Aligarh, Uttar Pradesh, India

ARTICLE INFO

Article history:

Received 19-10-2019

Accepted 11-11-2019

Available online 12-12-2019

Keywords:

Endometrioid carcinoma

Ovary

Histopathology

Immunohistochemistry

ABSTRACT

Endometrioid tumors tend to be malignant in most cases and accounts for roughly 20.0% of all cases of ovarian cancer. This form of ovarian epithelial carcinoma tends to simulate atypical endometrial glands. As the tumor grows, it infiltrates into the surrounding tissues and organs, allowing the tumor to feed with greater ease and become more solid. Survival after the appearance of an endometrioid tumor of the ovary depends upon the stage and grade of the tumor at the time of diagnosis and the treatment modality followed. Because of the high possibility of malignancy, aggressive chemotherapeutic regimen and possibly extensive surgery should commence as soon as possible. If the tumor is diagnosed early and successfully treated, patients have a five-year survival rate of 75.0%. We report an unusual case of isolated primary endometrioid carcinoma of the ovary in a 55-year-old woman, who presented with dull aching pain and lump in the right lower abdomen for the last 3 months.

© 2019 Published by Innovative Publication. This is an open access article under the CC BY-NC-ND license (<https://creativecommons.org/licenses/by/4.0/>)

1. Introduction

Epithelial ovarian carcinoma remains the most lethal of gynecologic malignancies. Numerous studies have revealed the various histological subtypes of ovarian cancers might have distinguishing origination and mechanism of development, and divergent clinical and pathological characters and different prognosis as well.¹

Ovarian endometrioid carcinoma (OEC) accounts for 16 – 25% of all epithelial ovarian cancers.² Compared with patients with high-grade serous carcinoma, a higher percentage of patients who are diagnosed with OEC are at the early stage, and the prognosis of this series of patients is relatively better. It is currently believed that patients with International Federation of Gynecology and Obstetrics (FIGO) stage I ovarian endometrioid carcinoma have a good overall prognosis and low rates of cancer recurrence.³

Most ovarian tumors are adenocarcinomas of different histological subtypes, derived from the surface epithelium

of the ovary.⁴ They manifest in various morphological forms as adenocarcinomas with serous, mucinous, clear cell or endometrioid differentiations. Also it is well known that primary endometrial neoplasms include the same subtypes.⁵

2. Case Summary

A 55-year-old woman presented with dull aching pain and lump in the right lower abdomen for the last 3 months. Ultrasonography of the lower abdomen revealed a well defined mass in the right ovary. CT Scan confirmed the mass with hypoechoic shadows in the right ovary with no noticeable ascitis. Hematological and biochemical parameters were within normal limits, except a raised CA-125 levels of 154μg.

Hysterectomy with right oophorectomy was performed. Grossly, there was no evident intrauterine tumor with only foci of adenomyotic patches in the myometrium of the uterus and the endometrium was unremarkable with no involvement of the omentum. The right ovary was enlarged with smooth external surface, 10x 9.2 cms in size.

* Corresponding author.

E-mail address: kafilakhtar@gmail.com (K. Akhtar).

Cut section showed solid to cystic growth with papillary configurations (Figure 1). There was no evidence of disease elsewhere in the abdomen with no lymphadenopathy, although there was a significant amount of fibrosis. The patient was staged as FIGO-IIA by Ovarian International Federation of Gynecology and Obstetrics classification.

Microscopically, tissue sections showed closely packed glands lined by columnar epithelium with hyperchromatic basal nuclei, with minimal intervening stroma with foci of papillary configuration of tumor cells. Extensive areas of haemorrhage and necrosis was also noted with no lymphovascular invasion. (Figure 2). Immunohistochemical analysis showed the tumour cells reactive strongly with epithelial membrane antigen (Figure 3) and pancytokeratin and focally reactive with vimentin. A final diagnosis of endometrioid-type ovarian adenocarcinoma was given. Our patient was administered combination adjuvant chemotherapy of 6 cycles of 50 mg/m² of carboplatin and 50 mg/m² of paclitaxel. Our patient is doing well after 12 months of follow up.

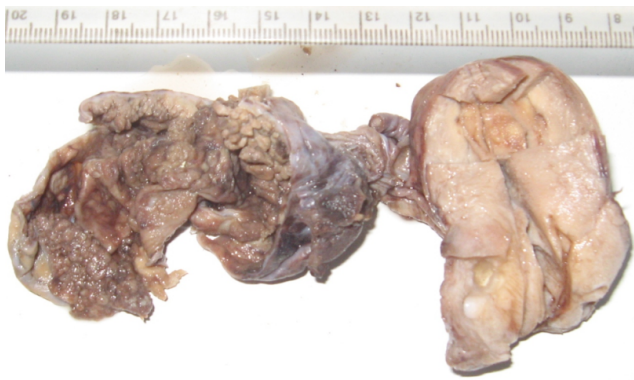

Fig. 1: Grossly, no evident intrauterine tumor with only foci of adenomyotic patches in the myometrium of the uterus, with unremarkable endometrium is seen. The right ovary is enlarged, 10x 9.2 cms in size, with solid to cystic growth with papillary configurations.

3. Discussion

The mean age at diagnosis of all patients with ovarian cancer is 59.6 years.² Endometrioid carcinoma of the ovary is found to be more frequent in the younger age-group (<50 years), while mucinous and serous cancer occur a decade later.^{3,4} It has been suggested that endometrioid carcinomas have a better prognosis than do serous carcinomas, and present with lower histologic grade and FIGO staging.⁴

Some recent studies suggested that endometrioid adenocarcinoma admixed with serous, clear cell features may behave more aggressively than endometrioid adenocarcinoma without these features.^{6,7} Silva et al speculated that the endometrioid type EOC may become dedifferentiated into undifferentiated carcinoma in which

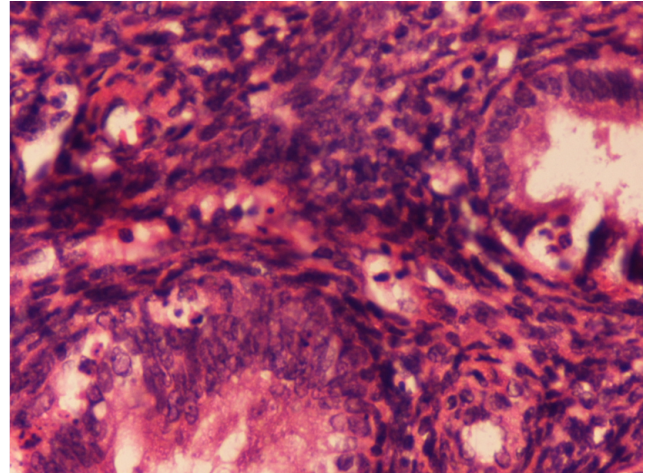


Fig. 2: Microscopically tissue sections shows closely packed glands lined by columnar epithelium with hyperchromatic basal nuclei, with minimal intervening stroma with foci of haemorrhage and necrosis. Haematoxylin and Eosin x40X.

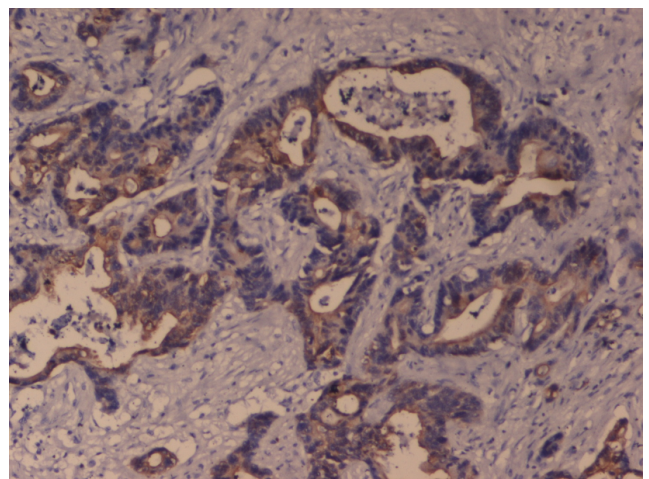


Fig. 3: Immunohistochemical analysis showed the tumour cells reactive strongly with epithelial membrane antigen. EMA x 10X.

the solid component of the tumour includes neoplastic cells with variable histological appearance, without developing glandular differentiation.⁸

EOCs are classified as serous, endometrioid, mucinous, clear cell, transitional, mixed and undifferentiated subtypes.^{9,10} The histological grade of EOC is decided by the cell architecture, nuclear pleomorphism and mitotic activity. Immunohistochemically EOCs react positively with epithelial membrane antigen (EMA), inhibin, pancytokeratin (panCK), and calretinin and in this way differ from sex-cord stromal tumours.¹¹ The endometrioid subtype reacts strongly with EMA and panCK as compared to the other types.^{12,13} Endometrioid adenocarcinomas developing in the endometrium and ovary most often stain strongly for vimentin, which greatly aids in distinguishing them from

endometrioid or pseudoendometrioid tumours arising from the endocervix, colon or lung.¹³ Our patient's tumour cells strongly reacted with epithelial membrane antigen (EMA) and pancytokeratin (panCK), and focally reacted with vimentin, so we could clearly say that the tumour originated from the ovary.

Molecular markers emerging as mutation from PTEN and LOH analysis as described by Ricci et al may be more suitable to establish a correct final diagnosis in distinguishing between metastasis from primary synchronous carcinomas of the endometrioid subtype of the ovary and endometrium.¹⁴ The potential of these molecular markers has to be evaluated in larger series, because so far this has been done in only few patients.^{15,16}

The 2016 National Comprehensive Cancer Network (NCCN) guidelines listed hormone therapy as a postoperative adjuvant treatment option for histologic grade 1 OEC and low- grade serous carcinoma; like aromatase inhibitors, leuprolide acetate, and tamoxifen.¹⁷ But our patient of stage I OEC has responded well to platinum-based drugs and is doing well after 12 months of follow up period. Kumar et al in their study on 68 patients who received postoperative platinum- based combination chemotherapy have reported resistance to platinum-based chemotherapy drugs in only 3 patients (4.3%).¹⁸ And there was no difference found for the DFS of patients with less than 4 cycles of platinum-based chemotherapy and more than 4 cycles.¹⁹ It needs more efforts to investigate the optimal cycles of postoperative chemotherapy for Stage I OEC patients with variable prognostic risk factors.

The survival rate of patients with stage I OEC was higher than the survival rates of patients with stage I serous carcinoma and clear cell carcinoma.¹⁹ In the present study, our patient was well after 12 months of follow up period.

4. Source of Funding

None.

5. Conflict of Interest

None.

References

- Dabbs DJ, Sturtz K, Zaino RJ. The immunohistochemical discrimination of endometrioid adenocarcinomas. *Hum Pathol*. 2016;27:172–177.
- Köbel M, Kalloger SE, Baker PM. Diagnosis of ovarian carcinoma cell type is highly reproducible: a transcanadian study. *Am J Surg Pathol*. 2014;34:984–993.
- Kurman RJ, Shih IM. Pathogenesis of ovarian cancer: lessons from morphology and molecular biology and their clinical implications. *Int J Gynecol Pathol*. 2012;27:151–160.
- Köbel M, Kalloger SE, Huntsman DG. Differences in tumor type in low-stage versus high-stage ovarian carcinomas. *Int J Gynecol Pathol*. 2010;29:203–211.
- Storey DJ, Rush R, Stewart M, Rye T, Al-Nafussi A, et al. Endometrioid epithelial ovarian cancer: 20 years of prospectively collected data from a single center. *Cancer*. 2013;112:2211–2220.
- Kobel M, Kalloger SE, Boyd N. Ovarian carcinoma subtypes are different diseases: implications for biomarker studies. *PLoS Med*. 2018;5:232–235.
- Gilks CB. Subclassification of ovarian surface epithelial tumors based on correlation of histologic and molecular pathologic data. *Int J Gynecol Pathol*. 2014;23:200–205.
- Silva S, Prat J, Stewart M, Rye T, Al-Nafussi A, et al. Ovarian carcinomas, including secondary tumors: diagnostically challenging areas. *Mod Pathol*. 2015;18:99–111.
- Young RH and Scully RE. Metastatic tumors of the ovary, in Blaustein's Pathology of the Female Genital Tract, R. J. Kurman, Ed., Springer, New York, NY, USA, 2002;1063-1101. . Springer ;. .
- Niekerk CC, Vooijs GP, Bulten J, Dijk VA, Verbeek AL. Increased risk of concurrent primary malignancies in patients diagnosed with a primary malignant epithelial ovarian tumor. *Mod Pathol*. 2017;20(3):384–388.
- McCluggage WG, Young RH. Immunohistochemistry as a diagnostic aid in the evaluation of ovarian tumors. *Semin Diagn Pathol*. 2015;22:3–32.
- Ramalingam P, Malpica A, Silva EG, Gershenson DM, Liu JL, et al. The use of cytokeratin 7 and EMA in differentiating ovarian yolk sac tumors from endometrioid and clear cell carcinomas. *Am J Surg Pathol*. 2014;28:499–505.
- Kobel M, Bak J, Bertelsen BI. Ovarian carcinoma histotype determination is highly reproducible, and is improved through the use of immunohistochemistry. *Histopathol*. 2014;64:1004–1013.
- Ricci R, Komminoth P, Bannwart F, Torhorst J, Wight E, et al. PTEN as a molecular marker to distinguish metastatic from primary synchronous endometrioid carcinomas of the ovary and uterus. *Diagn Mol Pathol*. 2013;12(2):71–78.
- Seidman JD, Russell PR, Kurman RJ. Surface epithelial tumors of the ovary," in Blaustein's Pathology of the Female Genital Tract, R. J. Kurman, Ed., , Springer, New York, USA, 2012;791-904. ;.
- Morgan RJ, Armstrong DK, Alvarez RD, Bakkum-Gamez JN, Behbakht K, Chen LM. Ovarian Cancer, Version 1.2016, NCCN Clinical Practice Guidelines in Oncology. *J Natl Compr Cancer Netw*. 2016;14(9):1134–1163.
- Sieh W, Kbel M, Longacre TA, Bowtell DD, Fazio AD. Hormone receptor expression and ovarian cancer survival: an Ovarian Tumor Tissue Analysis consortium study. *Lancet Oncol*. 2013;14(9):853–862.
- Kumar A, Le N, Tinker AV, Santos JL, Parsons C, et al. Early-Stage Endometrioid Ovarian Carcinoma Population-Based Outcomes in British Columbia. *Int J Gynecol Cancer*. 2014;24:1401–1405.
- Vernooij F, Heintz AP, Witteveen PO, Heiden MV, Coebergh KW, et al. Specialized care and survival of ovarian cancer patients in The Netherlands: nationwide cohort study. *J Nat Cancer Inst*. 2008;100(6):399–406.

Author biography

Kafil Akhtar Professor

Mohd. Talha Senior Resident

Mohd. Saquib Junior Resident

Shahid A Siddiqui Professor

Cite this article: Akhtar K, Talha M, Saquib M, A Siddiqui S. Isolated primary endometrioid carcinoma of the ovary an unusual case of malignancy. *J Diagn Pathol Oncol* 2019;4(4):332-334.