



Case Report

Isolated eosinophilic myometritis –A rare histological finding

Girish Nandan^{1,*}, Manjit Singh Bal¹, Anuj Sharma¹, Neelam Gupta¹¹Dept. of pathology, MMMC Kumarhatti, Solan, Himachal Pradesh, India

ARTICLE INFO

Article history:

Received 07-07-2019

Accepted 21-08-2019

Available online 20-09-2019

Keywords:

Eosinophilic myometritis

Hysterectomy

Leiomyoma.

ABSTRACT

Introduction: A wide variety of benign diseases, occur in the uterus.¹ Tissue eosinophilia has been demonstrated under physiological conditions in different organs and loose connective tissues of mammals. Such an eosinophilia although slight, has been demonstrated in human uterus.² If a patient has tissue eosinophilia, the number of eosinophils in blood likely be normal.

Aim: The incidental finding of eosinophilic infiltration only in myometrium, needs to be highlighted.

Case Report & Conclusion: Histopathological diagnosis of Isolated Eosinophilic Myometritis, a rare incidental finding in a 50 year female without involvement of endometrium, leiomyoma and cervix, is being presented. The literature is being reviewed for this rare entity.

Objective: To highlight rare incidental histological finding of eosinophilic infiltration only in the myometrium when there is no involvement of endometrium, leiomyoma, cervix, fallopian tubes and ovaries.

© 2019 Published by Innovative Publication.

1. Introduction

Eosinophilic infiltration in to myometrium is very rare. If present, it is usually accompanied by involvement of endometrium, cervix and/or fallopian tubes.

The case under study, had incidental histopathological finding with isolated eosinophilic myometritis, without any kind of allergic manifestation or systemic disorder.

2. Case Report

A 48 year old Himachali patient presented to Gynaecology & Obstetrics Department with mild to moderate pain in the lower back, radiating to back of leg, which increased on walking along with mass in lower abdomen. It was of five months duration. She had a lower segment caesarean section (LSCS) scar. She was P2G2. LMP was 18.9.2018 after one year of amenorrhoea. Her caesarean section was done 24 years back. Age of menarche was 15 years.

Per vaginum, she had anteverted uterus and per speculum, there was evidence of chronic cervicitis.

Ultrasound findings showed a posterior wall fibroid projecting into the cavity (Figure 1)

After routine investigations she was subjected to pan-hysterectomy.

The specimen was received in Department of Pathology for histopathological examination on 29/10/2018.

2.1. Pre-Operative Investigations

Haemoglobin: 10.8 gm %, Total Leucocyte count: 7800 per cub mm

2.2. Differential Leukocyte count

Polymorphs: 72%, Lymphocytes: 21%,
Monocytes: 02%, Eosinophils: 05%, Basophils: 0%.
Absolute Eosinophilic Count: 400/cub mm.

2.3. Biochemical Investigations

Blood Glucose: 85 mg/dl, B. Urea: 20 mg/dl, S. Creatinine: 0.9 mg/dl, T3-1.35 ng/dl T4-8.6 µg/dl, TSH-4.39 mIU /ml. S. Bilirubin T – 0.6 mg/dl, SGOT-16 U/L, SGPT-28 U/L, Alkaline Phosphate-68 IU/L.

* Corresponding author.

E-mail address: girishnandan90@gmail.com (G. Nandan).

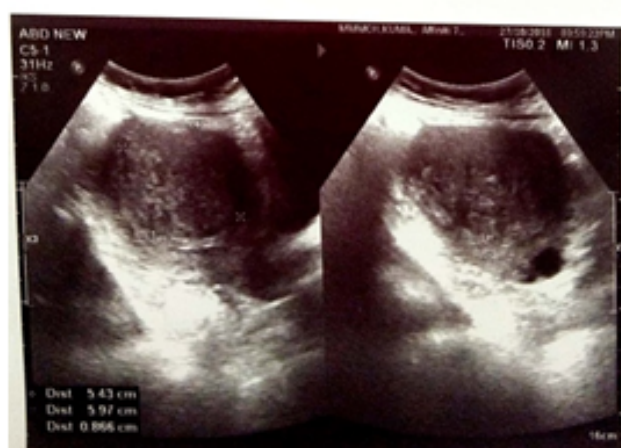
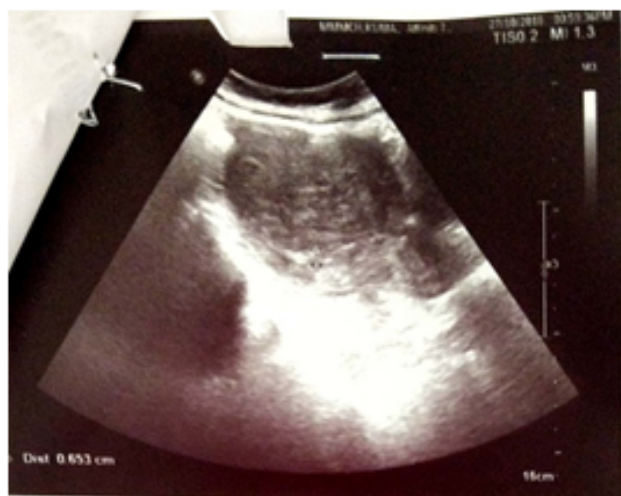
Fig. 1: Ultrasound findings showing posterior wall fibroid projecting into the cavity.

2.4. Pathological examination

Gross: Specimen of uterus with cervix, both fallopian tubes and both ovaries, together measuring 10 X 7.5 X 4.2 cms. Cervix measured 3.5 cms.

Uterine cavity was obliterated by a large fibroid measuring 6 X 5 X 4.7 cms.

Cut surface showed whorled appearance.

On Cutting, myometrium and endometrium showed no remarkable gross findings.

Ovaries and fallopian tubes were also unremarkable.

2.5. Microscopic examination

Multiple pieces taken from myometrium revealed numerous eosinophils present in clusters as well as scattered discretely in the substance of myometrium.

These were specially gathered around the blood vessels (Figure 2).

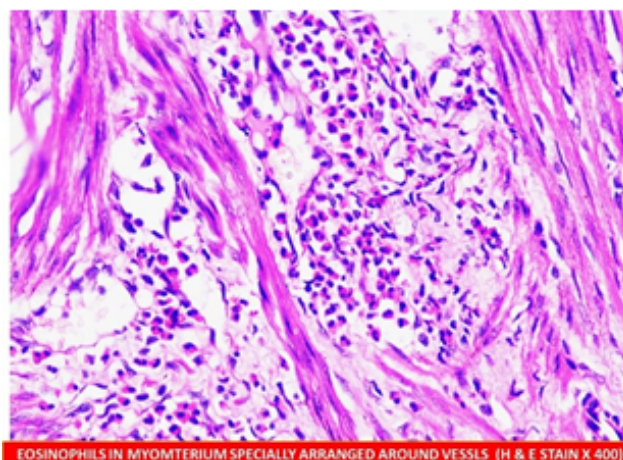


Fig. 2: Eosinophils in the myometrium specially around the blood vessel (H & E STAIN X400).

Pieces from leiomyoma, cervix, endometrium and fallopian tubes showed no eosinophilic infiltration.

Ovaries were unremarkable with no eosinophilic infiltration.

Even repeated sampling and more serial sections from different sites of leiomyoma, fallopian tubes and cervix showed no eosinophils.

The whole endometrial tissue was thoroughly sampled and examined but no eosinophils could be formed.

Diagnosis of Isolated Eosinophilic Myometritis was given. The literature is being reviewed for this rare entity of isolated eosinophilic myometritis without involvement of endometrium, leiomyoma and cervix.

3. Discussion

Tissue eosinophilia may be found in samples taken during an exploratory procedure or in samples of certain fluids, such as mucus released from nasal tissues. In 2,542 obstetric and gynaecologic pathologic specimens examined at the pathology laboratory of the Sloane Hospital for Women, 25 showed moderate to severe degrees of tissue eosinophilia.³

Eosinophils are bone marrow-derived cells of the granulocyte lineage. They have an approximate half-life of 8 to 18 hours in the bloodstream, and mostly reside in tissues⁴ where they can persist for at least several weeks. Their functional roles are multifaceted and include antigen presentation; release of lipid-derived, peptide and cytokine mediators for acute and chronic inflammation; responses to helminths and parasite clearance through degranulation; and ongoing homeostatic immune responses. They can be part of the overall cellular milieu in malignant neoplasms and autoimmune conditions, and connective tissue disorders, and are also found in less well characterized entities.⁵ As in

this case, eosinophils were found around the blood vessels, it could be a eosinophilic vasculitis. However, in that case it may involve the heart, kidneys, gastrointestinal tract, skin, or nervous system,⁶ but the patient does not have any kind of symptom / complaint related to any other system.

The literature was reviewed and the degree of eosinophilia correlated to clinical data. The possibility is that the eosinophilia in tissues represents a local allergic response, although highly selective, to breakdown of tissue because of some bacterial inflammation or previous surgical procedure was taken into consideration.

But on inquiring from the patient and reviewing all the previous laboratory findings, the patient was not suffering from any allergic condition.⁶

Eosinophil infiltration and degranulation occur in many diseased tissues in humans. Among normal tissues studied as controls, only the gut showed striking eosinophil infiltration and degranulation. Spleen, lymph node, and thymus tissues showed eosinophil infiltration with scant evidence of degranulation, but the only organ showing both eosinophil infiltration and remarkable degranulation was the gastrointestinal tract.⁷

Also, there was no evidence of any parasitic condition, or any evidence of vasculitis. So it was an isolated tissue eosinophilia in the myometrium as, even the endometrium was spared of eosinophils.

In the absence of any known cause of tissue eosinophilia, this case could be treated as that of Isolated Eosinophilic Myometritis or Eosinophilic Myometropathy.

For patients in whom no underlying disease or hypereosinophilic syndrome is found, the term hypereosinophilia of undetermined significance is introduced.⁸

On follow up of the case for about four months, the patient has no post-operative complication/complaint, allergic or any other manifestation related to tissue eosinophilic infiltration.

4. Conclusion

More studies are required to be undertaken for such incidental finding as not much literature is available regarding eosinophilic infiltration only in to the myometrium.

4.1. Consent

Consent was obtained from the patient.

She was explained in detail, the diagnosis and this research paper, in her own language.

5. Source of Funding

None.

6. Conflict of Interest

None.

References

1. Miko TL, Lampé LG, Thomázy VA, Molnár P, Endes P. Eosinophilic endomyometritis associated with diagnostic curettage. *Int J Gynecol Pathol.* 1988;7(2):162–72.
2. Bjersing, Borglin NE. Eosinophil in the myometrium of human uterus. *Acta Pathol.* 1962;54(4):1699–0463.
3. Divack DM, Janovski NA. D Eosinophilia encountered in female genital organs. *Amer Jr Obst Gynaec*;84(6):761–3.
4. Kovalszki A, Sheikh J, Weller PF. Eosinophils and Eosinophilia. In: Rich RR, editor. *Clinical immunology principles and practice.* 4th. Elsevier Saunders ; 2013., p. 298–309.
5. Kovalszki A, Weller PF, Eosinophilia M. Eosinophilia, PMCUS National Library of Medicine National Institutes of Health ; 2016.,
6. Wechsler ME. Churg-Strauss Syndrome. *Clinical Asthma.* 2008;.
7. Kato M, Kephart GM, Talley NJ, Wagner JM. Eosinophil infiltration and degranulation in normal human tissue. *The Anatomical Record* ; 1998.,
8. Valent P, Klion AD, Horny HP, Roufosse F. Contemporary consensus proposal on criteria and classification of eosinophilic disorders and related syndromes. *J Allergy Clin Immunol.* 2012;130(3):607–12.

Author biography

Girish Nandan Post Graduate Student

Manjit Singh Bal Professor

Anuj Sharma Associate Professor

Neelam Gupta HOD

Cite this article: Nandan G, Bal MS, Sharma A, Gupta N. Isolated eosinophilic myometritis –A rare histological finding. *J Diagn Pathol Oncol* 2019;4(3):230-232.