

Persistent pain and swelling after tooth extraction: A masquerade of adenoid cystic carcinoma

Madhumita Srivastava^{1,*}, Gaurav Vishal², Priyanka Jain³, Prakash Pandey⁴, Sanjoy Chowdhary⁵

^{1,3}Specialist, ²Junior Resident, ^{4,5}Joint Director, ¹Dept. of Oral & Maxillofacial Surgery, Bokaro General Hospital, Jharkhand, India

***Corresponding Author:**

Email: dr.madhumitasri.20@gmail.com

Abstract

Adenoid cystic carcinoma is the second most common malignancy of the major and minor salivary gland and palate being the most common intraoral location. This tumor generally has a slow growth rate, and it is often present for several years before the patient seeks treatment. By judicious examination and proper investigation one can rule out the pathology at an earlier stage. Here we report a case of extensive adenoid cystic carcinoma involving the left hard palate, which reported to us after extraction of teeth.

Keywords: Adenoid Cystic Carcinoma, Early diagnosis.

Introduction

Oral carcinomas are among the most prevalent cancers in the world and one of the 10 most common causes of death. In India, oral cancer ranks first among all cancer cases in males, and third among females in many regions. In a 10-year follow-up study, over 30,000 individuals in 3 distinct geographic regions of India were selected and was found that the annual incidence rates of development of potentially malignant disorders were found to be 1.1-2.4/1000 in males and 0.2-1.3/1000 in females.¹

Adenoid cystic carcinoma is most frequent pathology occurring in the minor salivary glands. In addition to the salivary glands, it affects the lacrimal glands, ceruminous glands and occasionally the excretory glands of the female genital tract. It is known for its long clinical course and plodding growth.²

There are instances when carcinoma is overlooked by a clinician in its early stage involving dentition. If healing following dental treatment does not progress as expected, suspicion for other lesions such as an oral SCC should be considered. Oral carcinomas can be insidious in onset and progression and many times mistaken for periodontal disease or abscess. If not properly focused on such masquerades, extractions of teeth are done without thorough examination and investigations. Occasionally, cases of carcinoma of the alveolus and palate appear to arise following extraction of a tooth. However, if such cases are carefully examined, it can usually be ascertained that the tooth was extracted because of pain or disease or mobility which in fact was a tumor, which at the time of treatment (surgery) went unrecognized or undiagnosed. In addition, this group of patients and their families due to laxity of dental and medical professionals may feel frustration and loss of confidence in the healthcare system.

Case Report

A 54 year old female was evaluated for a swelling on left side of face since 3 months duration. She reported a noticeable change in her face appearance during this time. There was associated history of tooth extraction of left maxillary second molar under local anesthesia 3 months back. A detailed case history revealed that she got her tooth extracted due to mobility and pain while chewing. The tooth was extracted on first visit only, due to the same reason. A thorough examination was not conducted prior to extraction, also no investigations, neither hemogram nor radiographs were done prior to extraction. Post extraction pain did not subside. The pain was localized and continuous in nature. She experienced difficulty during mastication and while brushing. The pain also disturbed her sleep. The pain was only transiently relieved on taking analgesics. The patient complained of bleeding on and off from the extraction site. The patient also complained of halitosis. This problem continued for next two months for which patient used to take medicine until she noticed a swelling on her left side of face. On receiving no permanent relief, despite repeated visits to her dentist for her problem she reported to our OPD with the chief complaint of swelling and pain. Her past medical history didn't reveal anything of significance.

General examination revealed that the patient was of moderate height and built, and her vital signs were within the normal range. She, however, had pallor.

Extra-oral examination revealed a diffuse swelling along the left side of upper half of face extending from lower eyelid superiorly to 4 cm above body of mandible inferiorly. Laterally the swelling extended 4cm anterior to tragus of ear to lateral wall of left side of nose medially. Also left side nasolabial fold was obliterated. Her inter orbital opening was reduced. Enlargement of left nostril was well appreciated. The

overlying skin appeared normal with no sinus or colour changes or temperature changes. The swelling overall was hard and tender on palpation; the swelling didn't exhibit any bruit or egg-shell crackling. Mouth opening was not restricted. Bilateral TMJ had normal movement with no significant findings. Left Submandibular lymph node was palpable, which was soft in consistency and non tender. No associated paresthesia, rhinorrhea, was there but nasal congestion was present. At the time of presentation her visual activity was intact with no restriction in eye movement but mild infraorbital tenderness was there. [Fig. 1]

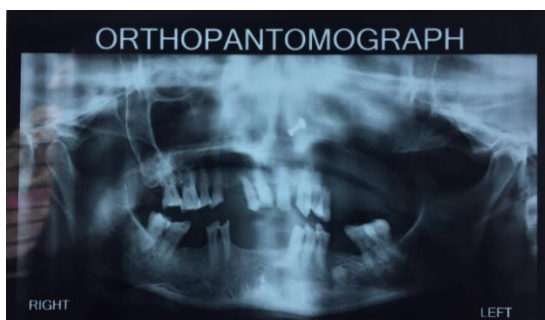


Fig. 1: Orthopantomograph

Intra-oral examination revealed an ulceroproliferative reddish pink colored mass measuring 4 × 3 cm extending from mid palatal suture to left buccal sulcus with an intrasocket depression of 1 × 1 cm in 27 extraction region. Anteriorly the mass started just posterior to left rugae region extending up to maxillary tuberosity region. The gingiva in relation to 25, 26, and 27 appeared reddish-pink, edematous, and swollen. 24 & 25 were grade I mobile. Margin of the mass were distinct with smooth surface except indurated in the socket region. Mass was obliterating the occlusion with patient having right side open bite. Patient's oral hygiene was poor. [Fig. 2 & 3]

A provisional diagnosis of Adenoid cystic carcinoma was arrived at with the differential diagnosis including: Carcinoma of alveolus, low grade malignancy involving maxillary sinus and mucoepidermoid carcinoma.

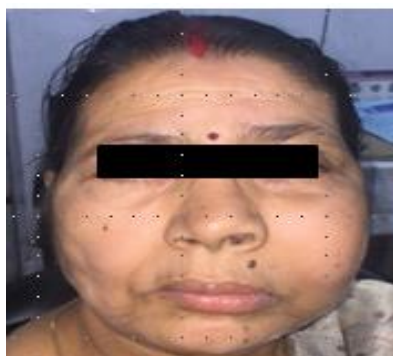

Fig. 2: Facial profile picture showing extension of swelling

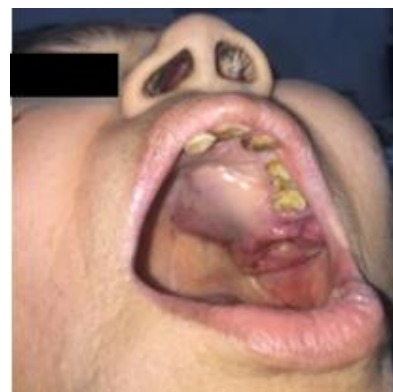

Fig. 3: Intra-oral picture showing swelling extending from left central incisor to hard palate not crossing midline

Investigations

A complete hemogram, blood glucose estimation, orthopantomograph (OPG) [Fig. 4], chest x-ray and CECT (Contrast Enhanced Computed Tomography) scan [Fig. 5, 6 & 7] were advised. All the parameters of the hemogram and blood glucose estimation were within the normal range. OPG showed destructive lesion causing resorption of upper premolar root and the surrounding bone also involving the walls of left maxillary sinus. Chest x-ray showed no pleural or parenchymal abnormalities.

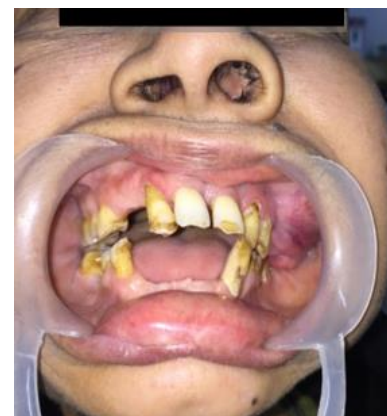

Fig. 4: Intra-oral picture showing swelling hindering occlusion

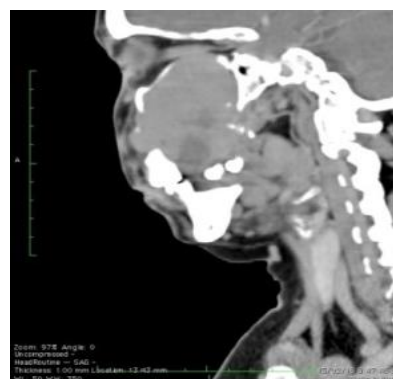

Fig. 5: Sagittal section

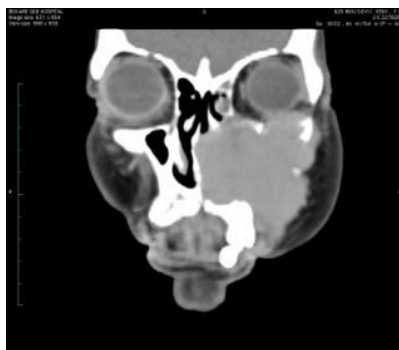

Fig. 6: Coronal section

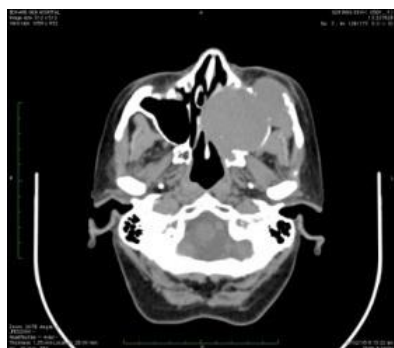

Fig. 7: Axial section of contrast enhanced computed tomography scan showing extent of swelling

4.6x5.68x 6.1 cm sized well defined, expansile, solid infiltrative mass lesion, centred in left maxillary sinus was noted. Medially mass was eroding/destroying right lateral nasal wall (medial wall of left maxillary sinus), extending into left nasal cavity and displacing the nasal septum towards right. The mass showed intragenous enhancement with central hypodense. Posteriorly and posterolaterally mass was eroding sinus wall and left pterygoid plate. It was extending into left pterygopalatine fossa and masticator space. Anteriorly and anterolaterally mass causing, sinus wall and left zygomatic bone erosion. Superiorly mass was eroding left orbital floor, with infraorbital extension. It was also showing close area of contact with left medial and inferior rectus muscle with loss of fat planes. Inferiorly mass was eroding left half of palate and lateral aspect of left superior alveolar ridge. Enlarged level I, bilaterally level II nodes were noted (nodes measuring <6 cm in greatest dimension). Nasopharyngeal and oropharyngeal air column appeared normal. No intracranial extension of mass was noted. These findings were suggestive of neoplastic malignant etiology lesion (carcinoma maxilla) likely T_{4a} N₂. Stage IV_A. Histo pathological correlation was suggested.

Biopsy

Incisional biopsy was done, after taking written informed consent of patient. Histological examination confirmed the diagnosis of Adenoid cystic carcinoma cribriform pattern type of hard palate. [Fig. 8]

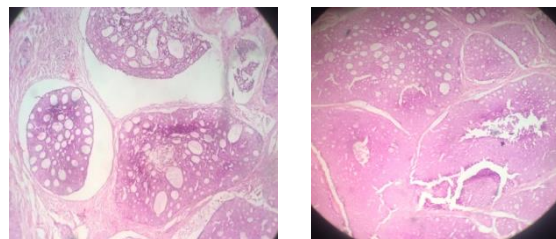


Fig. 8: H & E view showing isomorphic basoloid tumor cells in cribriform pattern with eosinophilic material

The subtotal maxillectomy was done under general anesthesia (GA). In the final histopathological examination, the margins were clear and radiotherapy was advised as per schedule. Patient is on continuous follow up from past one year, without any evidence of recurrence. For functional and aesthetic rehabilitation of the patient, an obturator was given. Reconstructive surgery is planned in near future.

Discussion

Adenoid cystic carcinoma is a part of the malignant epithelial tumors of the salivary glands and has been recognized as a specific variant of adenocarcinoma of the salivary and mucous glands.^{3,4} Adenoid cystic carcinoma is a rare tumor constitutes for less than 1% of head and neck malignancies and 10% of all salivary gland tumors. It is a slow-growing malignant tumour, more commonly seen in minor salivary glands, and hard palate is one of the most frequent sites of the disease followed by tongue, floor of mouth and lip. Other rare locations include the aero digestive tract, minor salivary glands, lachrymal glands and adnexal skin glands. Rarely occurs as primary intra osseous tumors of the maxilla and mandible.⁵⁻⁷

It was first described by three Frenchmen (Robin, Lorain, and Laboulbène) in two articles published in 1853 and 1854. It was they who described the cylindrical appearance of this tumor. Billroth, in 1859, first described AdCC under the name "cylindroma", for its cribriform appearance formed by tumor cells with cylindrical pseudolumina or pseudo spaces and described that ACC had a "great tendency to recur".⁸ Tumor is graded according to Szanto et al. Cribriform or tubular (grade I), less than 30% solid (grade II), or greater than 30% solid (grade III). It was described by Conley and Dingman as "one of the most biologically destructive and unpredictable tumors of the head and neck".⁹

It is slow growing; however, multiple local recurrence and perineural spread is common. Haematogenous metastasis is more common than lymphatogenous metastasis. The common sites of metastasis are lung and bones; however, involvement of other organs such as liver is not common.^{10, 11}

AdCC arising from the minor salivary glands are often advanced at the time of diagnosis, and complete excision is limited by their large size (with perineural extension involving the cranial base) and the proximity of the tumor to important neural and vascular structures.¹⁰

A 1:1 sex ratio is commonly noted with slight more inclination towards female population.¹² Adenoid cystic carcinoma is more common in 5th to 6th decade of life. Same was seen in our case. The etiology of AdCC is not very clear, but it appears to develop from non-inherited, genetic changes that occur during life time. These genetic changes are present only in cancer cells, not in cells with the genetic material that is passed on to offspring's, but the changes may be due to environment. However, in literatures no strong environmental risk factors are identified. Also it is not associated with tobacco use.¹³ Some evidence of AdCC tumor is associated with too much presence of 'myb' protein and p53 tumor suppressor gene. Well researches are going on to identify the cause. In our study patient reported to us after tooth extraction.

Adenoid cystic carcinoma is known to have aggressive tumor behaviour by its ability to invade and metastasize. Distant metastases and infiltration into the regional lymph nodes is noted in <10% of cases. Even though lungs are recognized as the organs of propensity for distant metastases, spread to bone, brain, and hepatic tissues have been also been noted in few cases.^{10, 14} In our case no such distant metastasis was seen.

The prognosis of Adenoid cystic carcinoma is dependent on multiple factors, and the overall 5-year survival rate is 47%. Advanced imaging modalities such as computed tomography and magnetic resonance imaging are considered beneficial in the diagnosis of this tumor. This modality helps to assess the actual location and extension and to plan the surgical treatment. Chemotherapy was proven to be ineffective in the management of AdCC. Long term follow up is necessary in these cases because of the high rate of local recurrence and regional metastasis¹⁵. In this present case CECT scan was done which revealed the vast extension of the carcinoma, which was very useful at the time of surgery. Also radiotherapy was done after surgical excision.

Literatures show association of Adenoid cystic carcinoma (AdCC) and oral squamous cell carcinoma are with history of extraction\ minor surgical procedure.^{2,3,5,7,9,10,12,16-22} There are instances when after tooth extraction carcinoma appears to develop rapidly and it proliferate up out of the socket, which could probably be due to the unobstructed growth of the neoplastic tissue along the periodontal ligament and sudden proliferation after extraction. Standard treatment AdCC so far consists of complete surgical resection preferably, followed by adjuvant irradiation in case of close margins, perineural invasion,

extensive primary tumor (T3, T4) or high-grade histology.^{3,22} In this present case report we did the same, i.e. complete surgical extraction followed by radiotherapy. We also gave an obturator for functional rehabilitation.

Conclusion

As adenoid cystic carcinoma is a slow growing rare malignant tumor, its early detection by the dental specialist aids in favourable prognosis in almost all cases. This case report strongly reflects that early diagnosis is an important factor affecting the prognosis of patients with oral pathology. All the necessary investigations should be done prior to any surgical procedure and keenly observed. Delays in diagnosis have been variously reported as being linked to the patient, the clinician or both and hence the prognosis.

References

1. A case of well-differentiated squamous cell carcinoma in an extraction socket. *J Indian Soc Periodontol* 2012;16(4):602-5.
2. Unusual presentation of adenoid cystic carcinoma: A case report. *Int J Case Rep Images* 2017;8(5):309-12.
3. Adenoid cystic carcinoma of the hard palate: A case report with a review of the literature on therapeutic and prognostic aspects. Kanaram Choudhary, *Ind J Oral Sci* 2012; 3(2)
4. Bradley JP. Adenoid cystic carcinoma of the head and neck: a review. *Curr Opin Otolaryngol Head Neck Surg* 2004;12:127-32.
5. Adenoid cystic carcinoma of the palate: case report and review of literature. *Pan Afr Med J* 2016;24:106
6. Maciel Santos MES, Ibrahim D, Neto JC, Da Silva JC, Da Silva UH, Sobral APV. Carcinoma adenóide cístico: relato de caso. *Rev Cir Traumatol Buco-Maxilo-Fac* 2005;5:49-54.
7. Stell PM. Adenoid cystic carcinoma. *Clin Otolaryngol* 1986;11(4):267-91.
8. Ellis GL, Auclair PL, Gnepp DR. Adenoid cystic carcinoma, Surgical Pathology of Salivary glands, Philadelphia. WB Saunders. 1991;333-46.
9. Szanto PA, Luna MA, Tortoledo ME, White RA. Histologic grading of adenoid cystic carcinoma of the salivary glands. *Cancer* 1984;54(6):1062-9
10. Adenoid cystic carcinoma of hard palate with coincidental metastases to lung and liver. Ali Akhavan, *BMJ Case Reports* 2013; doi:10.1136/bcr-01-2012-5658
11. Mehta DN, Parikh SJ. Adenoid cystic carcinoma of palate. *J Nat Sci Biol Med* 2013;4:249-52.
12. Aggressive adenoid cystic carcinoma involving palate extending to maxillary sinus in a young female. *J Oral Res Rev* 2016;8(1)
13. Mehta DN, Parikh SJ. Adenoid cystic carcinoma of palate. *J Nat Sci Biol Med* 2013;4:249-52.
14. Shamim T, Varghese VI, Shameena PM, Sudha S. Primary intraosseous adenoid cystic carcinoma of the mandible with lung metastasis: A case report. *J Oral Sci* 2008;50:95-8.
15. Conley J, Baker DG. Cancer of the salivary glands. In: Suen JY, Meyer EN, editors. *Cancer of the Head and Neck*. New York: Churchill Livingstone 1981:524-56.
16. A case of well-differentiated squamous cell carcinoma in an extraction socket. *J Indian Soc Periodontol* 2012;16(4):602-5.

17. Metastatic pattern in squamous cell carcinoma of the hard palate and maxillary alveolar ridge: clinical experience and review of the literature Johannes Buller et.al.
18. Mader C, Gay WD. Intraoraladenoid cystic carcinoma. *J Am Dent Assoc* 1979;99(2):212-4. Pub Med
19. Prognosis of Gingival Squamous Cell Carcinoma Diagnosed after Invasive Procedures Eun-Joo Choi, Xianglan Zhang, Hyung-Jun Kim, Woong Nam, and In-Ho Cha. *Asian Pacific J Cancer Prev* 12,2649-52.
20. T Singh, M Schenberg. Delayed diagnosis of oral squamous cell carcinoma following dental treatment. *Ann R Coll Surg Engl* 2013; 95:369-73.
21. Adenoid cystic carcinoma of palate. *J Nat Sci Biol Med* 2013;4(1):249-52.
22. Adenoid cystic carcinoma of palate: A case report and review of literature. *Dent Res J (Isfahan)* 2013;10(2):274-8.