

## Fibroadenoma arising in accessory breast tissue of the axilla: A rare case report

Monal Trisal<sup>1</sup>, Mohammad Jaseem Hassan<sup>2\*</sup>, Safia Rana<sup>3</sup>, Rubeena Naz Mohroo<sup>4</sup>, Sujata Jetley<sup>5</sup>

<sup>1,4</sup>Demonstrator, <sup>2</sup>Associate Professor, <sup>3</sup>Assistant Professor, <sup>5</sup>Professor, <sup>1-5</sup>Dept. of Pathology, Hamdard Institute of Medical Sciences and research (HIMSR), New Delhi, India

**\*Corresponding Author:**

Email: jaseemamu@gmail.com

### Abstract

Axilla is the most common site for accessory breast tissue. Fibroadenoma is a very common benign lesion of breast but is not commonly found in accessory breast tissue. We report a case of fibroadenoma in a 19-year-old young unmarried girl who presented with a mobile swelling in left axilla since five months. The ipsilateral breast was normal. No FNAC was performed and excision biopsy was done and sent for histopathological examination which showed features of fibroadenoma. The most important clinical significance is that number of inflammatory, cystic and neoplastic diseases similar to those of a normal breast have also been reported in accessory breasts. For early detection of malignancy in the axilla, a vigilant self-examination and clinical assessment is required.

**Keywords:** Fibroadenoma, Accessory breast, Ectopic breast tissue.

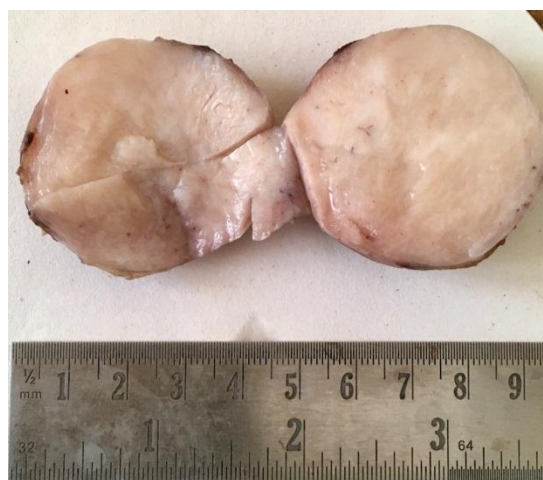### Introduction

Accessory breast tissue is a residual breast tissue that persists from normal embryologic development.<sup>1</sup> It may occur anywhere along the milk line, from the axilla to the groin. Also called as ectopic breast tissue, occurs in about 6% of the population. The term 'Aberrant breast tissue' is the breast tissue located near to the proximity of the breast and has accessory fragments of breast tissue outside the periphery of the gland.<sup>2</sup> Fibroadenoma is a very common benign lesion of breast. Fibroadenoma of an accessory breast however is a very rare finding and only few cases have been reported in the literature.

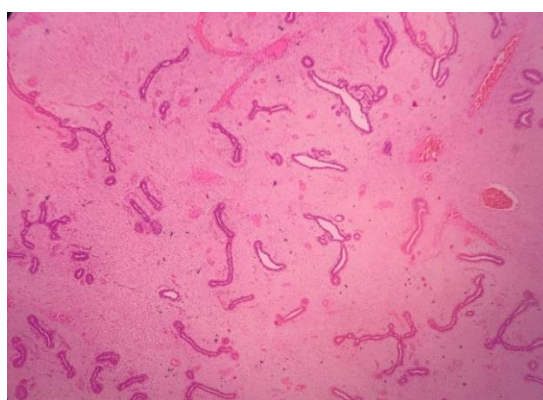
### Case Presentation

A 19-year-old young unmarried girl noticed a mobile left axillary swelling since five months. On physical examination, the swelling was freely mobile, soft to firm in consistency measuring approximately 4x3.5cm, had smooth surface with regular margins. Overlying skin appeared normal. No ulcer or discharge was present. The breasts were bilaterally symmetrical with no lump or nipple discharge. A clinical diagnosis of accessory breast was made. No fine needle aspiration cytology and other relevant investigations were performed and excision biopsy was done and sent for histopathology. Grossly, a single grey brown to grey white globular partially encapsulated tissue piece measuring 4.5x4x3cm was received. Externally, focally congested areas were identified. On cut surface, homogenous grey white areas with slit-like areas were seen. (Fig. 1) On microscopy, sections taken showed a well circumscribed lesion composed of biphasic growth of variably cellular to myxoid spindle cells stroma with cleft like (intracanalicular) glandular growth pattern. (Fig. 2,3). The glandular component was composed of two cell layers, inner epithelial layer and outer

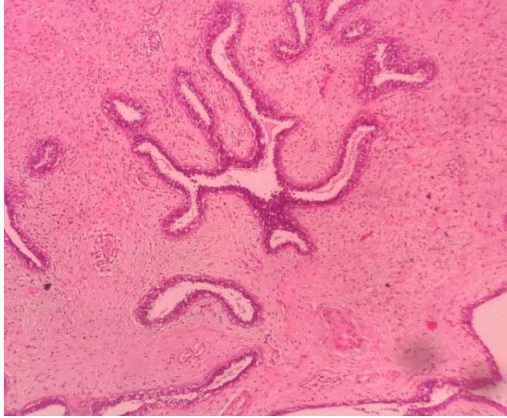
myoepithelial layer. Histopathological features were compatible with fibroadenoma.



**Fig. 1: Gross appearance showing a partially encapsulated grey white to grey brown tumor. Cut surface is homogenous with slit like areas**



**Fig. 2: Photomicrograph showing predominantly intracanalicular pattern of fibroadenoma. (H&E x 100)**



**Fig. 3: Photomicrograph showing predominantly intracanalicular pattern of fibroadenoma. (H&E x 400)**

### Discussion

The incidence of accessory breast tissue is overall 0.4–6% in the general population.<sup>3</sup> During fifth week of embryogenesis, mammary ridges develop by thickening of ectoderm, that runs from axilla to groin.<sup>4</sup> Except for two segments in pectoral region that develops into normal breasts, rest involutes. This failure of involution results in formation of accessory breasts.

Second hypothesis is that accessory breasts develops from modified apocrine sweat glands.<sup>5</sup> Axilla is the most common site of accessory breast occurring in nearly 2–5% of females.<sup>3</sup> It is twice as common in females than in males. Rare accessory breast tissues have also been reported in perineum, back of neck, vulva, flank, back, upper arm, midline of shoulders.<sup>6</sup> In most patients, accessory breast presents with no symptoms only a visible swelling. But in some of the females, it causes pain and discomfort in reproductive age related with menstrual cycle, pregnancy and lactation. Apart from cosmetic reasons, it develops the similar pathological changes as the normally located breast tissue such as fibroadenoma, cystosarcoma phylloides, inflammation, fibrosis and even carcinoma.<sup>7</sup> Fibroadenomas of accessory breast tissue has been very rarely described in literature and the exact incidence is unknown. Sawa et al. described about a fibroadenoma in accessory breast tissue in axilla in a 41-year-old lady presenting with a right axillary lump along with five small nodules in the ipsilateral breast.<sup>8</sup> Coras et al. reported one case of fibroadenoma in axillary accessory breast in a 23-year-old young female.<sup>9</sup> Supreethi et al. reported a case of bilateral fibroadenoma in a 34-year-old patient who presented with axillary lumps bilaterally.<sup>10</sup> Carcinoma arising from the accessory breast presents very late and has poorer prognosis due to delay in diagnosing. There is a vast differential diagnosis for any axillary lesion, which includes sebaceous cyst, vascular lesions, lipoma, suppurative hidradenitis, lymphadenopathy, metastasis in lymph nodes, tuberculosis, axillary tail of Spence, and

malignancy.<sup>11</sup> The axillary accessory breast tissue connected to outer part of normal breast tissue is called the axillary tail of Spence.<sup>12</sup> The accessory breast tissue of axilla should be isolated tissue in axilla as in our case. In our case, the fibroadenoma was present in the left accessory breast tissue in axilla rather than in any extension of breast tissue into the axilla. Thus thorough self-examination and investigations is important as accessory breast tissue presents same spectrum of pathological lesions from cystic, inflammatory, benign to malignant as that in normal breast tissue.

### Conclusion

1. Fibroadenoma is an extremely common cause of young females presenting with breast lump, with increased incidence between the age of 20 and 30 years. It is very rarely been described in axillary breast tissue.
2. Fibroadenoma of accessory breast tissue should always be considered when a differential diagnosis of any axillary swelling is made.
3. Tumors in accessory breast tissue should be diagnosed with the same investigations as normal breast tissue. An extensive study is required to know the exact incidence of fibroadenoma arising in accessory breast tissue.

### References

1. Laor T, Collins M, Emery K, Donnelly L, Bove K, Ballard E. MRI appearance of Accessory breast tissue: a diagnostic consideration for an axillary mass in a peripubertal or pubertal girl. *AJR* 2004;183:1779-81.
2. Goyal S, Puri T, Gupta R, Julka P et al. Accessory breast tissue in axilla masquerading as breast cancer recurrence. *J Cancer Res Ther* 2008;4:95-6.
3. Coras B, Landthaler M, Hofstaedter F, Meisel C et al. Fibroadenoma of the axilla. *Dermatol Surg* 2005;31:1152-4.
4. Yaghoobi R, Bagherani N, Mohammadpour F. Bilateral aberrant axillary breast tissue. *Indian J Dermatol Venereol Leprol* 2009;75:639.
5. Craigmyle M. The Apocrine Glands and the Breast. 1984;49-55.
6. Lilaia C, Capela E, Cadilla J. Ectopic Breast Fibroadenoma. *Internet J Gynecol Obstet.* 2007;6:2.
7. Aughsteeen AA, Almasad JK, Al-Muhtaseb MH. Fibroadenoma of the supernumerary breast of the axilla. *Saudi Med J.* 2000;21:587-9.
8. Sawa M, Kawai N, Sato M, Takeuchi T et al. Fibroadenoma of the axillary accessory breast: Diagnostic value of dynamic magnetic resonance imaging. *Japanese J of Radiol.* 2010;28:613-17.
9. Coras B, Landthaler M, Hofstaedter F, Meisel C et al. Fibroadenoma of the axilla. *Derm Surg.* 2005;31:1152-4.
10. Supreethi K, Pragya G, Suman K, Anand K. Rare clinical entity- Fibroadenoma of ectopic breast tissue. *Indian J Basic App Med Res.* 2015;5(1):575-8.
11. Silverberg M, Rahman M. Axillary Breast tissue mistaken for Suppurative hidradenitis. An avoidable error. *J Emerg Med* 2003;25:51-5.
12. Mukhopadhyay M, Saha A, Sarkar A. Fibroadenoma of the ectopic breast of the axilla. *Indian J Surg* 2010;72:143-5.