

**Case Report****Localized pigmented villonodular synovitis of talocalcaneal joint: A rare case report****Girish Nathani^{1,*}, Ajit Swamy¹, D.S Bhamare¹**¹Dept. of Orthopaedics, Dr. D. Y. Patil Medical College, Hospital & Research Centre, Maharashtra, India**ARTICLE INFO***Article history:*

Received 23-03-2019

Accepted 31-10-2019

Available online 06-01-2020

Keywords:

Arthroscopic debridement with Radio frequency ablation

ABSTRACT

Pigmented villonodular synovitis is a relatively rare condition. This is caused due to increased proliferation of synovium causing villous or nodular changes of synovial lined joints. In this study we have successfully excised the tumour with help of arthroscopic radio frequency ablation after open excision.

© 2019 Published by Innovative Publication. This is an open access article under the CC BY-NC-ND license (<https://creativecommons.org/licenses/by/4.0/>)

1. Introduction

Pigmented Villonodular Cynovitis (PVNS) is a rare disease affecting the joints which are lined by synovium. It was described by Jaffe and colleagues, in 1941 as a benign inflammatory state of the synovium unclear etiology and as a tumor like aggression of synovial tissue involving joints.¹ It can be either diffuse or localized either intra articular or extra articular.² Diffuse PVNS involves the entire joint synovium whereas localized PVNS is a discrete nodular, lobulated mass.³ PVNS mainly occurs in the knee joint, PVNS of the foot and ankle is rare⁴ (incidence, is approximately 1.8/million.⁵ Severity of bony involvement in PVNS of the ankle is high, because the pressure erosion easily occurs in the narrow joint space of the ankle joint.⁶ The diffuse type has high recurrence rate as high as 50%, whereas the rate for the localized type is considered low.^{[2,5,7] 2,5,7} To prevent, complete excision and careful tissue handling is necessary. We operated a case of ankle(talo calcaneal) PVNS with bone erosion of adjoining articular cartilage of talus and calcaneus which was treated with radical excision. The authors have obtained the patient's written informed consent for print and electronic publication of the case report.

2. Case Report

38 year old male patient was referred to us with complains of pain, gradually increasing swelling and ulcerating wound on lateral aspect of right ankle since 10yrs with history of excision done in past. On examination swelling was present on lateral aspect of right ankle range of motion and stability of joint appeared to be normal. USG of local area was done which showed approximately 7*3.5*8 cm sized well defined heterogeneous isoechoic lesion. A true cut biopsy was taken which showed loosely cellular fibro vascular tissue with diffusely infiltrating lymphocytes and many brown pigmented laden cells and vascular proliferation. Diagnosis of pigmented villonodular synovitis was done. Surgical resection of mass was planned with diagnostic arthroscopy to see for extent of the tumor with standard J-Shaped incision. The challenges which we faced in surgery was wound closure, risk of infection, Paraesthesia involving the distribution of superficial peroneal nerve.

* Corresponding author.

E-mail address: girishnathani786@gmail.com (G. Nathani).

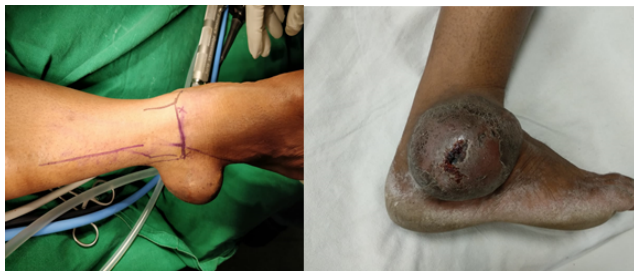

Fig. 1: Local area photo showing swelling

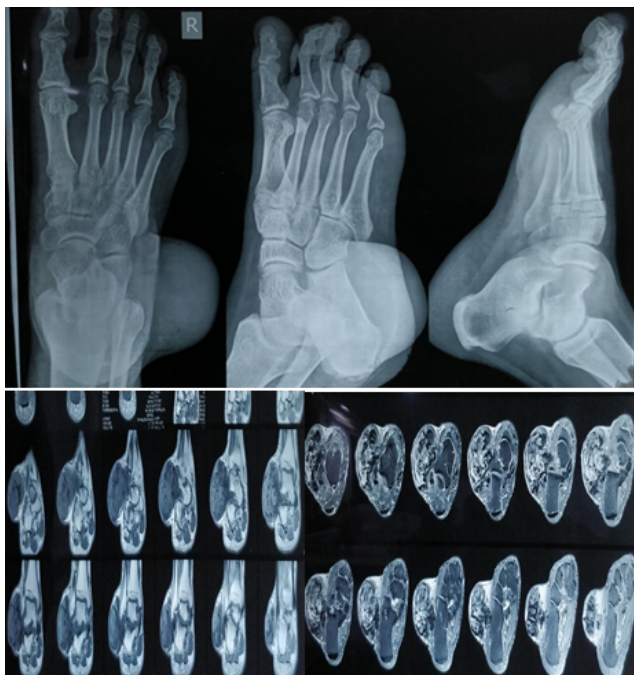

Fig. 2: Plain radiograph of ankle showed shadow of the swelling and confirmed that the swelling was not bony

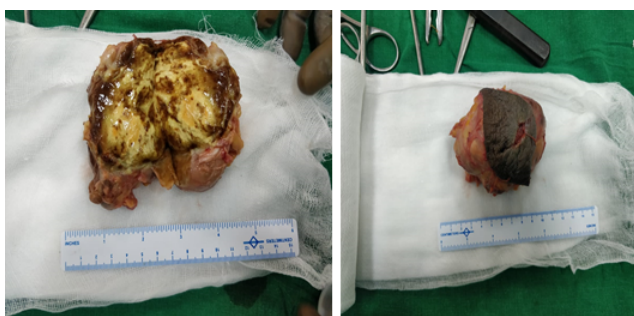


Fig. 3: Histopathological sample revealed grossly a greyish brown with few white areas (? Pigmentation) soft to firm in consistency and encapsulated tissue of size 3.5*2.8*1.2 cm

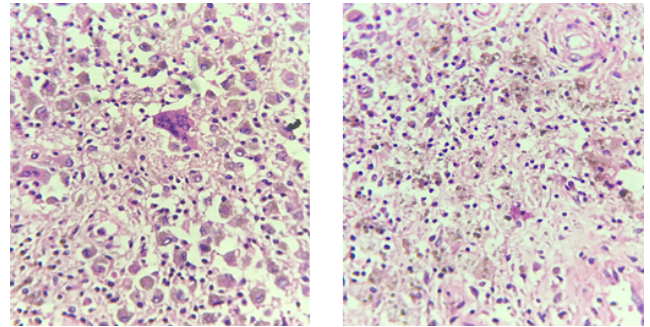


Fig. 4: Microscopic examination showed an benign tumor consisting of sheath of plump round consisting of plump round to oval epithelised cellular with few scattered multinucleated giant cells and hemosiderin laden macrophages.

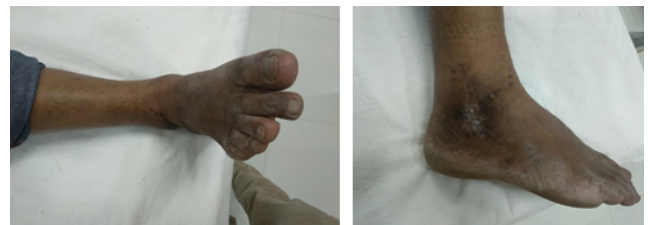

Fig. 5: Post-operative clinical picture

3. Discussion

PVNS is mainly affects of synovial joints. PVNS rarely occurs around ankle joint <10% as compared to other joint and no standard treatment has been defined. Arthroscopic or open arthotomy can be performed. Treatment of choice is synovectomy for diffuse PVNS, because of high recurrence trails for use of adjuvant focused external radiotherapy with intra articular injection with radioactive colloids.

Total synovectomy and complete excision is necessary to prevent joint erosion and degenerative changes. Because of anatomic characteristic of ankle joint it is technically difficult to exfoliate massive tissue without disturbing integrated ligaments. In our case the patient had massive mass extending to talocalcaneal joints with involvement of articular cartilage. Thus to summarize the localised PVNS involving the ankle joint needs complete mass excission

4. Conclusion

Surgical excision was done with arthroscopic debridement of remanant tissue. There is no recurrence as of 6month follow up. Pt is planned for futher MRI to see for recurrence.

5. Source of Funding

None.

6. Conflict of Interest

None.

References

1. Jaffe HL, Lichtenstein L, Sutro CJ. Pigmented villonodular synovitis, bursitis and tenosynovitis. *Arch Pathol.* 1941;31:731–765.
2. Granowitz SP, D'Antonio J, Mankin HL. The pathogenesis and long-term end results of pigmented villonodular synovitis. *Clin Orthop.* 1976;(114):335–351.
3. Villani C, Tucci G, Mille DM, Gennaro SD, Corsi A. Extra-articular localized nodular synovitis (giant cell tumor of tendon sheath origin) attached to the subtalar joint. *Foot Ankle Int.* 1996;17(7):413–416.
4. Rao AS, Vigorita VJ. Pigmented villonodular synovitis (giant-cell tumor of the tendon sheath and synovial membrane). A review of eighty-one cases. *J Bone Joint Surg Am.* 1984;66(1):76–94.
5. Myers BW, Masi AT. Pigmented villonodular synovitis and tenosynovitis: a clinical epidemiologic study of 166 cases and literature review. *Med.* 1980;59(3):223–238.
6. Goldman AB, Dicarlo EF. Pigmented villonodular synovitis. Diagnosis and differential diagnosis. *Radiol Clin North Am.* 1988;26(6):1327–1347.
7. Flandry F, Hughston JC. Pigmented villonodular synovitis. *J Bone Joint Surg Am.* 1987;69(6):942–949.

Author biography

Girish Nathani Resident

Ajit Swamy Professor and Head Unit

D.S Bhamare Professor and Head Unit

Cite this article: Nathani G, Swamy A, Bhamare DS. Localized pigmented villonodular synovitis of talocalcaneal joint: A rare case report. *Indian J Orthop Surg* 2019;5(4):275-277.