



## Original Research Article

## Proximal fibular osteotomy for medial compartment osteoarthritis of knee

Venugopala Reddy<sup>1</sup>, T. S. Raghav<sup>1</sup>, Siva Reddy Panapana<sup>1</sup>, Sai Saranya Burma<sup>1</sup>,  
Sai Madhavi Burma<sup>1</sup>, Satya Kumar Koduru<sup>1,\*</sup>

<sup>1</sup>Dept. of Orthopaedics, NRI General Hospital, Mangalagiri, Andhra Pradesh, India



## ARTICLE INFO

## Article history:

Received 28-08-2019

Accepted 31-10-2019

Available online 06-01-2020

## Keywords:

PFO

OA knee

Medial compartment OA

## ABSTRACT

Osteoarthritis of knee is the most common cause of disability in the older. Pain and limitation in the mobility of knee are the major causes of disability. Total knee arthroplasty, which aims to relieve pain, improve joint function and mobility, is the main surgical treatment in this patient population. Proximal fibular osteotomy is the new alternative in the young patients with arthritis of medial compartment. From July 2016 to July 2017, 60 consecutive patients who underwent PFO at our hospital were followed prospectively (n = 37; age range, 48 – 72 years; 40 female, 20 male) with follow-up at 3, 6, 9 weeks, 3 months, 6 months, 9 months, 12 months, and 24 months post-operative. Out of 60 patients who underwent PFO medial pain relief was observed in 54 patients after PFO with in one or two days post operatively remaining 6 had no change in pain. Results showed an increase in mean visual analog score (from 8.02 +/- 0.50 to 2.74 +/- 2.34) and an improvement in knee and function subscore of american knee society scores (pre operative 44.41 +/- 8.90 and 41.24 +/- 13.48 post operative 69.02 +/- 11.12 and 67.63 +/- 13.65) and an increase in ratio of medial/lateral joint space ratio (pre operative 0.20 +/- 0.28 post operative 0.48 +/- 0.30). Postoperative complications like paresthesias on dorsum of foot were observed in 6 patients, which recovered by 6 to 12 weeks. Thus we conclude that proximal fibular osteotomy is a safe, simple and affordable day care surgery that doesn't require insertion of implants.

© 2019 Published by Innovative Publication. This is an open access article under the CC BY-NC-ND license (<https://creativecommons.org/licenses/by/4.0/>)

## 1. Introduction

Osteoarthritis of knee is the most common cause of disability in the older.<sup>1</sup> Pain and limitation in the mobility of knee are the major causes of disability.<sup>1</sup> Total knee arthroplasty, which aims to relieve pain, improve joint function and mobility, is the main surgical treatment in this patient population.<sup>1</sup> The First choice of treatment in the young patients with medial compartment osteoarthritis is high tibial osteotomy even though this is associated with some disadvantages like non-union.<sup>2-5</sup> Proximal fibular osteotomy is the new alternative in the young patients which is safe, simple and affordable.<sup>1</sup> It relieves pain immediately and delays or avoids the need for total knee replacement.<sup>1</sup> The procedure is to remove 1.5 to 2.0 cms piece of fibula

Seven to 10 cms below the head of fibula to relieve medial compartment pressure, and consequently realign the knee.

It was proposed that the medial part of the knee has only single cortex support in an otherwise fully cancellous bone which is insufficient over a period of decades with mild collapse with ageing while the lateral part of the knee however is supported by three cortices (one by tibia and two from fibula) making it rigid and less collapsible. This leads to increasing varus with ageing and causes medial compartment osteoarthritis of knee.<sup>6</sup> It was also believed that load is distributed medial to centre of knee along mechanical axis.<sup>7</sup>

## 1.1. Aim of the study

To evaluate the long-term (24 months) results of PFO regarding pain relief, and improvement of joint function in a series of patients from our hospital.

\* Corresponding author.

E-mail address: [koduruskg@gmail.com](mailto:koduruskg@gmail.com) (S. K. Koduru).

## 2. Materials and Methods

Institutional Ethics Committee (IEC) approval obtained for this study (No.ECR/1160/Inst/ap/2018). All patients were given informed consent and agreed to participate in the study.

From July 2016 to July 2017, 60 consecutive patients who underwent PFO at our hospital were followed prospectively (n = 37; age range, 48–72 years; 40 female, 20 male) with follow-up at 3, 6, 9 weeks, 3 months, 6 months, 9 months, 12 months, and 24 months post-operative. Outcome measured by femorotibial angle using Wang et al method<sup>8</sup> and pain using visual analog scale.<sup>9</sup> The diagnosis of osteoarthritis was made by the clinician according to the American College of Rheumatology criteria.<sup>10</sup>

### 2.1. Inclusion Criteria

1. Isolated medial compartment arthritis of the knee with a varus deformity not exceeding 12 degrees.
2. Normal lateral compartment
3. Near normal Patellofemoral joint and
4. At least 2 mm joint space in the medial compartment, on weight bearing X-rays.
5. (Patients suitable for uni-compartmental arthroplasty or HTO)

### 2.2. Exclusion criteria

1. Tri compartmental osteoarthritis.
2. Varus deformity greater than 15 degrees
3. Fixed flexion deformity of knee more than 15 degrees.
4. Acute major trauma,
5. Inflammatory joint disease,
6. Skin diseases around knee
7. Medically unfit for surgery.

### 2.3. Details of procedure

With patient under spinal anesthesia and in supine position a longitudinal incision of about Five cms made over skin of the proximal fibula. Periosteum over the fibula is exposed between the peroneal and soleus muscles. Proximal fibular osteotomy was made about Seven to Ten cms from head of the fibula by removing about One to Two cms length of fibula.

With in few hours after the surgery patient is allowed full weight bearing and mobilisation of the knee. Weight bearing radiographs of the knee taken post operatively and compared with pre operative radiographs. Medial and lateral joint spaces analyzed and amount of correction achieved is determined. Knee pain was assessed using VAS (visual analogue scale).

Ambulation activities of knee were recorded using the knee and function subscores of the American Knee Society score<sup>11</sup> preoperatively and a mean of months

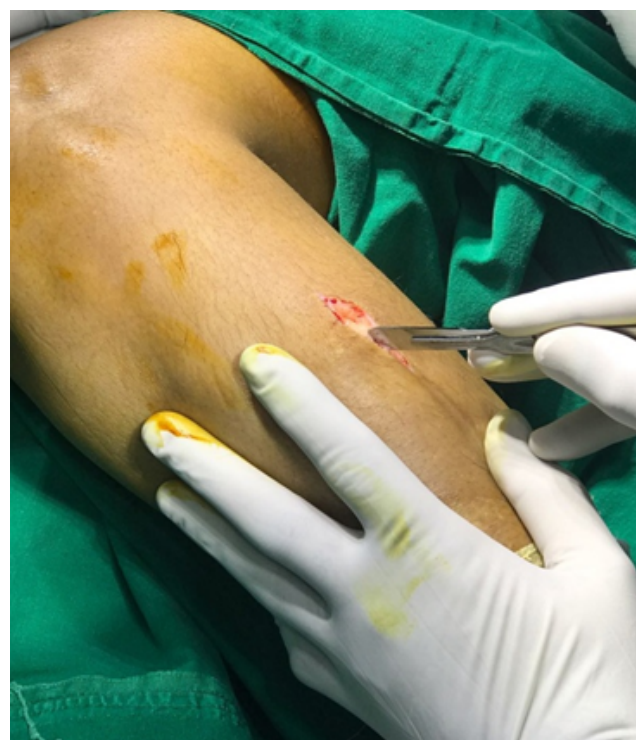postoperatively. Statistical analysis performed with mean +SD for continuous variables.

## 3. Results

Out of 60 patients who underwent PFO medial pain relief was observed in 54 patients after PFO with in one or two days post operatively remaining 6 had no change in pain. The mean duration of follow-up was 2 years (range, 12 months). The average duration for unilateral PFO was 32.23+/- 9.13 minutes. Postoperative complications like paresthesias on dorsum of foot were observed in 6 patients, which recovered by 6 weeks to 12 weeks and no other complications including wound infection, delayed healing or nerve damage.

**Table 1:**

Mean VAS score	
Pre op	8.02+/-0.50
Post op	2.74+/- 2.34

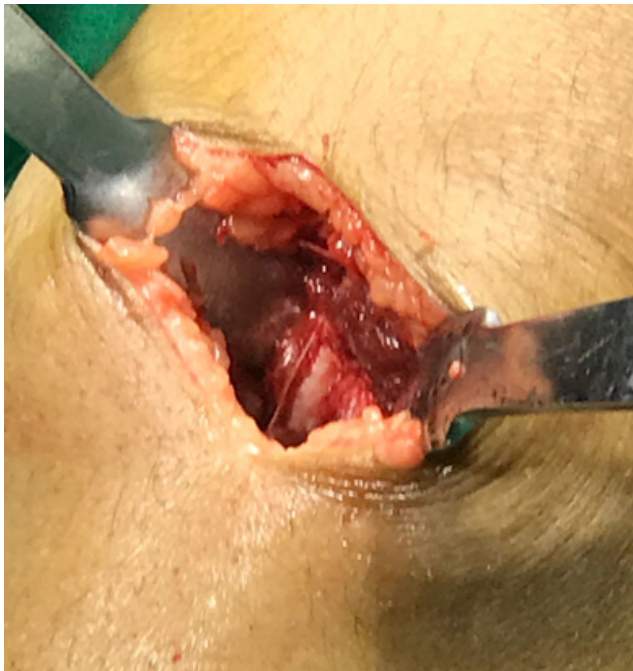

**Fig. 1:** Showing incision

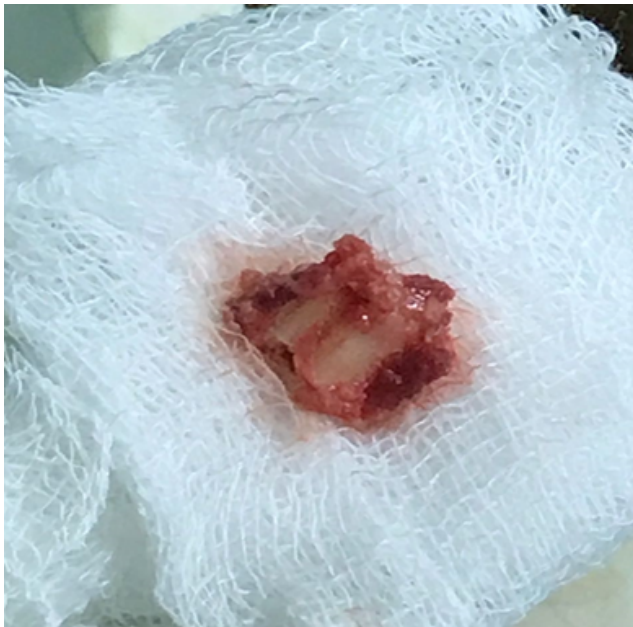The mean knee and function subscores were (American Knee Society score) .

**Table 2:**

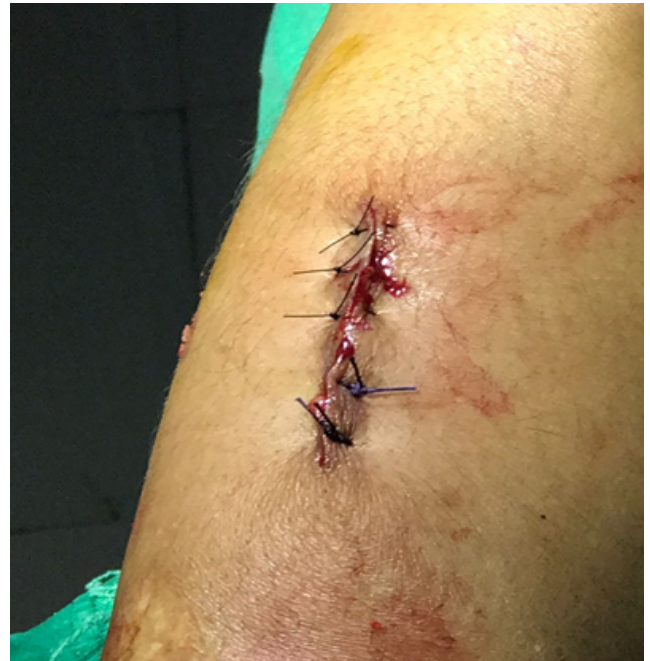Pre operative	44.41 +/-8.90 and 41.24 +/-13.48
Post operative	69.02+/- 11.12 and 67.63 +/-13.65



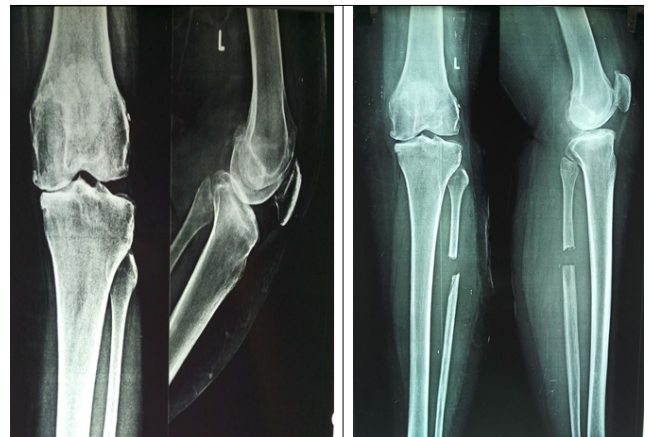
**Fig. 2:** Showing exposure of fibula



**Fig. 3:** Showing excised piece of fibula



**Fig. 4:** After closure of wound



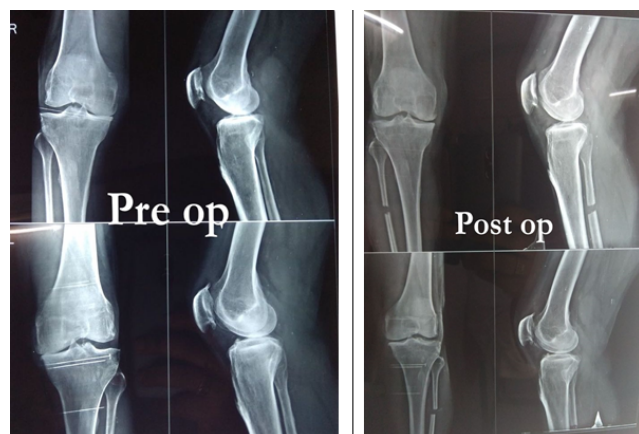
**Fig. 5:** Showing increase in medial joint space after surgery compared to pre operative

Radiographs of the weight-bearing lower extremity showed average increase in the medial knee joint space postoperatively compared with preoperatively. The ratio of the knee joint space in cms (medial/lateral compartment).

**Table 3:**

Pre operative	Post operative
0.20 +/-0.28	0.48+/- 0.30





**Fig. 6:** 2 more patients xrays showing improvement in alignment and increase in medial joint space post operative

#### 4. Discussion

Proximal fibular osteotomy is a safe, simple and affordable day care surgery that doesn't require insertion of implants. PFO is thus one of the best alternative for osteoarthritis of medial compartment of knee especially for patients with medical comorbidities who cannot undergo arthroplasty.

In our study 54 cases were successful (out of which 6 patients got nerve complaints (tingling and numbness) who were treated with Pregabalin 150 mg and vitamin B12 for 6 weeks to 12 weeks for these nerve complaints to settle) and 6 patients had no significant relief of pain in the followup period.

As the procedure leaves the knee virgin and is performed away from the knee joint, it scores over H.T.O in not violating the joint for a subsequent TKA if needed.

##### 4.1. Limitations of this study

This study is only a case series and further studies with higher level of evidence needed for confirmation of findings.

#### 5. Conclusion

Thus we conclude that proximal fibular osteotomy is a safe, simple and affordable day care surgery emerging as an alternative for high tibial osteotomy for patients with arthritis of medial compartment. Also further studies with higher level of evidence needed for confirmation of findings.

#### 6. Source of Funding

None.

#### 7. Conflict of Interest

None.

#### References

1. Wang L, Wei Z, Lv. Proximal fibular osteotomy: a new surgery for pain relief and improvement of joint function in patients with knee osteoarthritis. *J Int Med Res*;2017(1):282–289.
2. Duivenvoorden T, Brouwer RW, Baan A. Comparison of closing-wedge and opening-wedge high tibial osteotomy for medial compartment osteoarthritis of the knee: a randomized controlled trial with a six-year follow-up. *J Bone Joint Surg Am*. 2014;96:1425–1432.
3. Laprade RF, Spiridonov SI, Nystrom LM. Prospective outcomes of young and middle-aged adults with medial compartment osteoarthritis treated with a proximal tibial opening wedge osteotomy. *Arthroscopy*. 2012;28:354–364.
4. Sprenger TR, Doerzbacher JF. Tibial osteotomy for the treatment of varus gonarthrosis. Survival and failure analysis to twenty-two years. *J Bone Joint Surg Am*. 2003;85:469–474.
5. W-Dahl A, Robertsson O, Lidgren V. Surgery for knee osteoarthritis in younger patients. *Acta Orthop*. 2010;81:161–164.
6. Prakash L. PFO - Proximal Fibular Osteotomy For Medial Compartment Arthritis of The Knee With Varus Deformity. *EC Orthopaedics*. 2019;10.
7. Yang ZY, Chen W, Li CX, Wang J, Shao DC, et al. Compartment Decompression by Fibular Osteotomy To Treat Medial Compartment Knee Osteoarthritis: A Pilot Study. *Orthopedics*. 2015;38(12). Available from: [10.3928/01477447-20151120-08](https://doi.org/10.3928/01477447-20151120-08).
8. Wang F, Chen BC, Gao S. Influence of knee lateral thrust gait to femorotibial angle and lateral joint space in the knee varus patients. *Chinese J Orthop*. 2005;25(9):517–519.
9. Huskisson E. Measurement of pain. *Lancet*. 1974;304:1127–1131.
10. Altman R, Asch E, Bloch D. Development of criteria for the classification and reporting of osteoarthritis. Classification of osteoarthritis of the knee. Diagnostic and therapeutic criteria committee of the American rheumatism association. *Arthritis Rheum*. 1986;29:1039–1049.
11. Insall JN, Dorr LD, Scott RD, Scott WN. Rationale of the knee society clinical rating system. *Clin Orthop Relat Res*. 1989;248(248):13–14.

#### Author biography

**Venugopala Reddy** Assistant Professor

**T. S. Raghav** Senior Resident

**Siva Reddy Panapana** Junior Resident

**Sai Saranya Burma** Junior Resident

**Sai Madhavi Burma** Junior Resident

**Satya Kumar Koduru** Professor and Head

**Cite this article:** Reddy V, Raghav TS, Panapana SR, Burma SS, Burma SM, Koduru SK. Proximal fibular osteotomy for medial compartment osteoarthritis of knee. *Indian J Orthop Surg* 2019;5(4):263-266.