

Injection site abscess in an immunocompromised patient caused by non-pigmented strain of *Serratia marcescens*

Sunayana M. Jangla^{1*}, Bhupesh S. Machhi²

¹Microbiologist, ²Scientific Assistant, Dept. of Pathology, Bhabha Atomic Research Centre (BARC) Hospital, Maharashtra, India

***Corresponding Author: Sunayana M. Jangla**

Email: sunayanajangla79@gmail.com

Abstract

Serratia marcescens commonly causes infections of the respiratory tract, urinary tract, septicaemia and wound infections. It is an opportunistic Gram-negative pathogen causing infections commonly in the immunocompromised patients. However, skin and soft tissue infections caused by *Serratia marcescens* are unusual. Moreover, infection by non-pigmented strains are less common as compared to those by pigmented strains. We describe a case of an elderly immunocompromised female presenting with abscess formation at the site of insulin injection caused by non-pigment producing *Serratia marcescens*. She responded to treatment with antibiotics.

Keywords: Abscess, immunocompromised, non-pigmented, *Serratia marcescens*.

Introduction

Serratia marcescens is a Gram-negative bacillus which belongs to the family Enterobacteriaceae. It is present in water, soil and food as a saprophyte. It generally produces a red coloured pigment called prodigiosin and is an opportunistic organism usually causing nosocomial infections.¹ Skin and soft tissue infections caused by this organism are rare as normally it does not colonise human skin.^{2,3} Severe soft tissue infection in immunocompromised and diabetic patients caused by *Serratia marcescens* is uncommon but important.³ We present a case of abscess at injection site caused by non-pigmented strain of *Serratia marcescens* in a patient with long standing history of diabetes mellitus and who had undergone renal transplant.

Case Report

77 years old female patient presented with complaints of pain and redness in left thigh at the site of insulin injection. There was no history of fever. She is a known case of hypertension, ischaemic heart disease and long-standing diabetes mellitus. She had undergone renal transplant two decades back and is on steroid treatment for the same. On examination, there was localised tenderness and redness of affected area. Pus was received from that site which showed pus cells and Gram negative bacilli on primary Gram stain. It was inoculated on 5% Sheep Blood agar, MacConkey agar and Nutrient agar and incubated at 37°C for 24 hours and at 28°C for 72 hours. Post incubation there were non-lactose fermenting colonies on MacConkey agar (Fig. 1) but no pigment at 37°C or at 28°C at the end of 72 hours (Fig. 2). Sheep Blood agar showed grey mucoid non-haemolytic colonies. Gram stain from the growth showed Gram negative bacilli. The biochemical test showed negative reactions for indole, methyl red and urease test. Citrate utilisation test was positive. Triple sugar iron agar showed acid butt and alkaline slant without gas and hydrogen sulphide production. It was identified as *Serratia marcescens* which was confirmed using Vitek 2 compact GN ID card and antibiotic sensitivity test was done using GN 280 cards. It was susceptible to cefotaxime, ceftriaxone, cefepime, amikacin, gentamicin,

levofloxacin, ofloxacin, trimethoprim-sulfamethoxazole and cefoperazone-sulbactam. It showed intermediate susceptibility to piperacillin-tazobactam and was resistant to ampicillin, amoxycillin-clavulanic acid and second generation cephalosporin. No other pathological investigations were done. Patient was treated with one gram cefotaxime twice a day for five days intravenously and dressing of the site was done. She responded to this treatment.

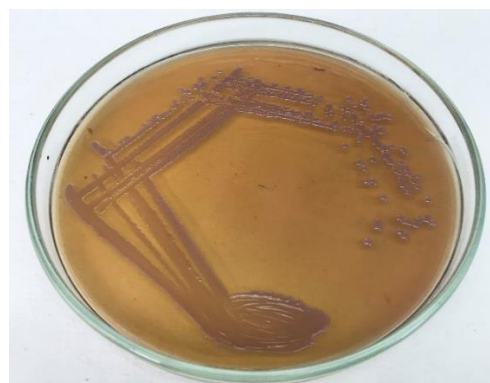

Fig. 1: Colonies of *Serratia marcescens* on MacConkey agar




Fig. 2: Colonies showing absence of pigment on Nutrient agar

Discussion

The clinical significance of *Serratia marcescens* as an opportunistic pathogen has gained significance only in the past few years. It has evolved as an important cause of health-care associated infection rather than as a cause of community-acquired pathogen.³ Some of the risk factors which enhance the chances of gaining infection with this organism are diabetes mellitus, history of trauma, alcoholism, immunosuppression, steroid use, injections and stay in intensive care unit.³⁻⁵ As it is not a part of normal flora of the skin, some pre-disposing factor like trauma or damage at the concerned site is a prerequisite which facilitates its entry inside.⁵ Our patient is a known case of long-standing diabetes mellitus and is regularly taking insulin injections. She cleans the local site of injection with spirit before taking it. Besides, she also had undergone renal transplant and is on steroids. These facts probably facilitated the abscess formation. Few cases of skin and soft tissue infection have been reported in literature and the commonest risk factor amongst these patients was diabetes mellitus.²⁻⁶ For detecting pigment production, isolate was incubated at 28°C as maximum pigment production is found at 28°C-30°C^{1,7} but no pigment was formed. Red pigment production on colonies is a characteristic of this organism.^{1,8} Pigmented as well as non-pigmented biotypes of *Serratia marcescens* are pathogenic but non-pigmented biotypes are more virulent.^{8,9} In India, infections caused by non-pigmented strains are highly unusual.⁸ Pigment production is a product which is tightly gene regulated. The immune system of the body is triggered by prodigiosin. Hence, to escape detection by the host's immune system this isolate when present in the human body itself limits pigment synthesis. Thus, strains which have lost the ability to produce pigment are found.¹⁰ This probably explains the absence of pigment in our isolate. For treatment, third generation cephalosporins, fluoroquinolones and imipenem/silastatin are antibiotics of choice.¹¹ Our isolate was sensitive to cefotaxime. She was given one gram cefotaxime twice a day for five days intravenously and she responded to it. Thus, skin and soft tissue infections by *Serratia marcescens* in immunocompromised patients, especially infection with non-pigmented strains are noteworthy.

Conclusion

The importance of non-pigmented *Serratia marcescens* as a cause of soft tissue infection especially in the immunocompromised is rising as this is not a part of the regular spectrum of diseases that it causes and the possibility of such cases needs to be kept in mind.

Conflict of Interest: None.

References

1. Ananthnarayan R, Panicker Jayram C K. Ananthnarayan and Paniker's textbook of Microbiology. 9th ed. Hyderabad 500 029(A.P), India: Universities Press (India) Private Limited;2013:273-84.

2. Jung K C, Kim S Y, Lee Y K, Han K, Kang S C, Shim I S et al. *Serratia marcescens* Skin Abscess. *Korean J Pathol* 1998;32(11):1032-4.
3. Biscode L A, Hakeem L. Severe soft tissue infection in a patient with type 2 diabetes mellitus caused by *Serratia marcescens* as a single pathogen. *Br J Diabetes* 2016;16(4):202-5.
4. Sharma V, Angrup A, Verma S, Singh D, Kanga A. Community-acquired cutaneous ulcer in a child caused by *Serratia marcescens*. *JMM Case Reports* 2014. DOI 10.1099/jmmcr.0.003228
5. Ray U, Soma D, Chakravarty C, Sutradhar A. A case of multiple cutaneous lesions due to *Serratia marcescens* in an immunocompromised patient. *JMM Case Reports* 2015. DOI 10.1099/jmmcr.0.000059
6. Veraldi S, Nazzaro G. Skin ulcers caused by *Serratia marcescens*: three cases and a review of the literature. *Eur J Dermatol* 2016;26(4):373-6.
7. Phatake Y B, Dharmadhikari S M. Physical Parameters optimization for enhancement of prodigiosin production by using *Serratia spp.* *World J Pharm Med Res* 2016;2(6):40-8.
8. Roy P, Ahmed H N, Grover R K. Non-pigmented Strain of *Serratia Marcescens*: An Unusual Pathogen Causing Pulmonary Infection in A Patient with Malignancy. *JCDR* 2014;8(6):DD05-DD06.
9. Carbonell G.V, Colleta D M H H , Yano T, Darini A LC, Levy C E, Fonseca B A L. *FEMS Immunol Med Microbiol* 2000;28:143-9.
10. Salnke G, Kamat S, Sangle S N, Namshikar V. Non-pigment producing *Serratia marcescens* causing discitis following lumbar endoscopic discectomy. *J Acad Clin Microbiol* 2015;17(1):52-4.
11. Lakhani A N, Narsinghani U, Kumar R. Necrotising fasciitis of the Abdominal Wall Caused by *Serratia Marcescens*. *Infect Dis Rep* 2015;7(2):5774.

How to cite this article: Jangla SM, Machhi BS. Injection site abscess in an immunocompromised patient caused by non-pigmented strain of *Serratia marcescens*. *Indian J Microbiol Res* 2019;6(2):184-5.