

**Case Series****Seeing the unseen: Endodontic management of middle mesial canal****Simran Gupta<sup>1</sup>, Vanshish Sankhyan<sup>1\*</sup>, Shabnam Negi<sup>1</sup>, Tanvi Ohri<sup>1</sup>**<sup>1</sup>Dept. of Conservative Dentistry and Endodontics, Bhojia Dental College and Hospital, Budh Baddi, Himachal Pradesh, India**Abstract**

Molars often have complex root structures with multiple canals, and if one or more of these canals is missed during treatment, bacteria can remain trapped, leading to infection and pain. One of the most frequent causes of root canal treatment failure is difficulty in finding extra canals, especially in molar teeth. This case series exemplifies the importance of radiographs and magnification techniques in the detection and effective endodontic therapy of a mid-mesial canal in the mandibular first molar tooth.

**Keywords:** Obturation, Anatomic variation, Mid mesial canal variation, Mandibular molars**Received:** 09-10-2024; **Accepted:** 01-02-2025; **Available Online:**

This is an Open Access (OA) journal, and articles are distributed under the terms of the [Creative Commons Attribution-NonCommercial 4.0 International](https://creativecommons.org/licenses/by-nc/4.0/), which allows others to remix, and build upon the work noncommercially, as long as appropriate credit is given and the new creations are licensed under the identical terms.

For reprints contact: [reprint@ipinnovative.com](mailto:reprint@ipinnovative.com)**1. Introduction**

Complete decrease of the microbial burden in the root canal system is essential for the efficacy of root canal therapy. Uninstrumented or empty root canals might impede this process by harbouring infected pulp tissue, resulting in the development or perpetuation of peri-apical disease.<sup>1</sup>

Vertucci and Williams<sup>2</sup> first reported the presence of a middle mesial canal in a mandibular molar. The incidence of having an extra canal in the mesial root is 1-15%.<sup>3</sup> The MMC can be described as a bleeding spot existing within the grooves, between the mesiobuccal (MB) canal and mesiolingual (ML) canal. The orifice size is smaller when compared to the other canals. Pomeranz et al., in 1981,<sup>4</sup> classified the MMC into three types, namely: A fin, A confluent, and an independent type. The MMC can also merge with the MB or ML canals, at the middle third of the root canal system.

Middle mesial canals (MMCs) are found in 1% to 23% of the global population, with an estimated incidence of 7%.<sup>5</sup> Failure to recognize such canal aberrations might lead to failure of endodontic therapy. Hence thorough knowledge of root canal anatomy is important for successful endodontic therapy. This case report enlightens successful endodontic

management of two cases in which first mandibular molar had three canals in mesial root.

**2. Case Series**

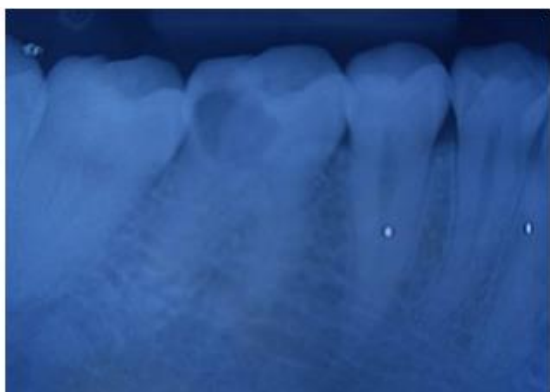A 47-year-old female patient was referred to department of conservative dentistry and endodontics with a chief complaint of severe pain in the right lower back tooth region from the past seven days. Clinical examination revealed caries on distal side approaching pulp and tenderness on percussion. The preoperative IOPA w.r.t 46 confirmed carious lesion involving pulpal space with periodontal space widening. (**Figure 1, Figure 7**) The patient was diagnosed with symptomatic irreversible pulpitis with symptomatic apical periodontitis due to dental caries w.r.t 46.

The patient's consent was obtained before administering local anesthesia. The tooth was isolated using rubber dam. The access opening was done under a microscope and a third mesial canal was detected between the two mesial canals. (**Figure 2, Figure 8**) All canals were negotiated using #10 K file. The working length was determined using electronic apex locator and confirmed using radiograph. (**Figure 3, Figure 9**) The root canals were cleaned and shaped using stainless steel hand K-files, and Pro Taper

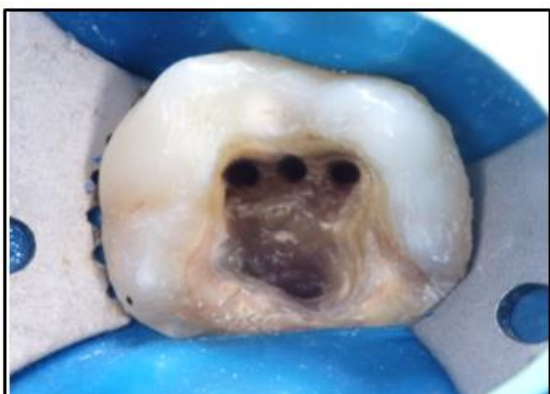
Corresponding author: Vanshish Sankhyan  
Email: [vanshishsankhyan96@gmail.com](mailto:vanshishsankhyan96@gmail.com)

(NiTi) rotary instruments under copious irrigation with 3% Sodium hypochlorite and 17% EDTA. The canals were cleaned with saline followed by drying with paper points and calcium hydroxide dressing was placed as an intra-canal medicament for 1 week. On the subsequent appointment, master cone radiograph was taken (**Figure 4, Figure 10**) and obturation was done using resin based sealer and cold lateral condensation technique. (**Figure 5,**

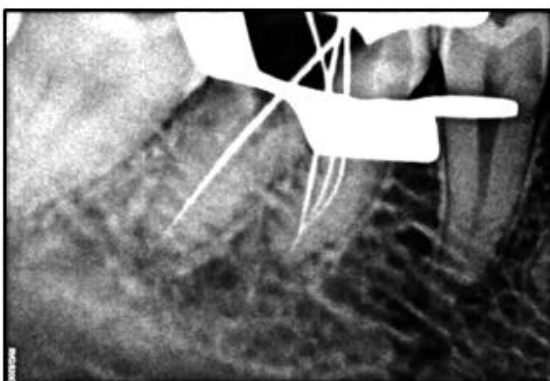
**Figure 11**) Thereafter, composite restoration was done. (**Figure 6, Figure 12**)



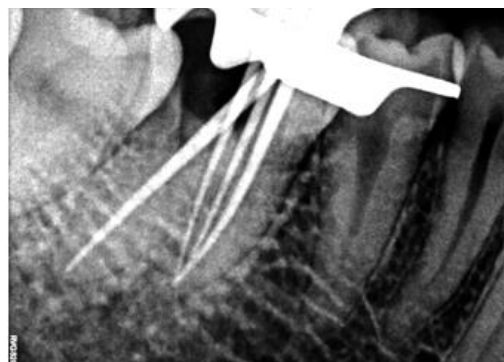
**Figure 1:** Preoperative radiograph mid mesial canal



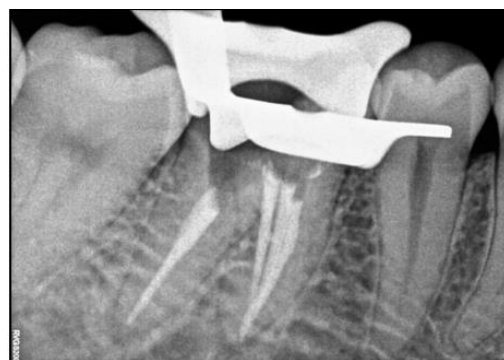**Figure 2:** Mid mesial canal



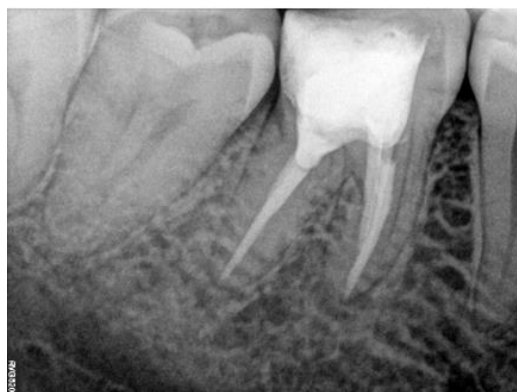**Figure 3:** Working length



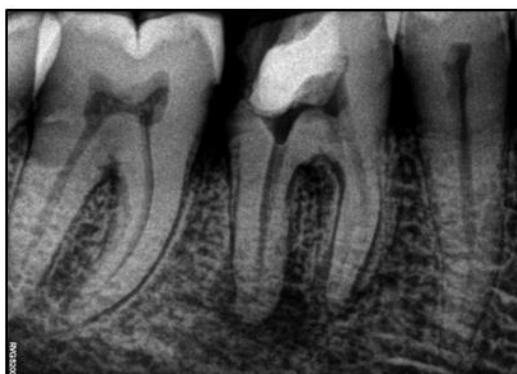**Figure 4:** Master cone



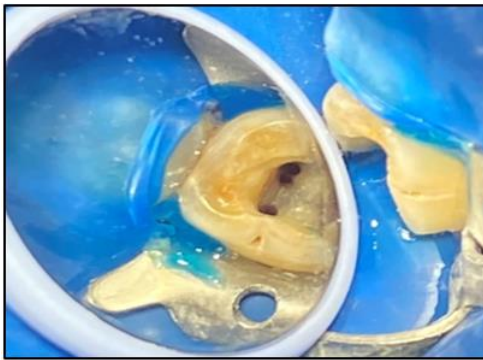
**Figure 5:** Obturation



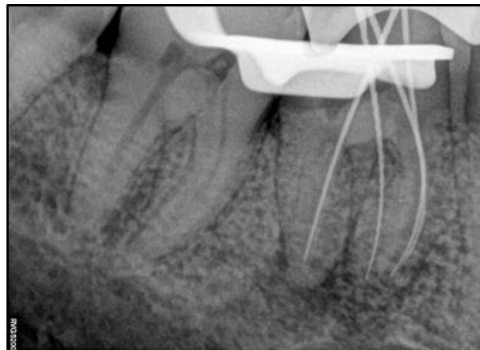
**Figure 6:** Post-obturation



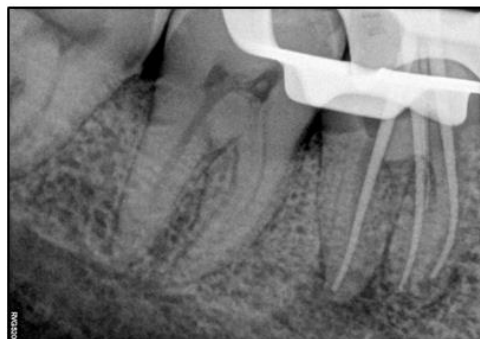**Figure 7:** Pre-operative radiograph



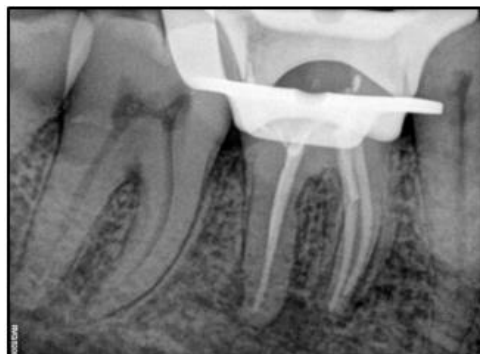
**Figure 8:** Mid mesial canal



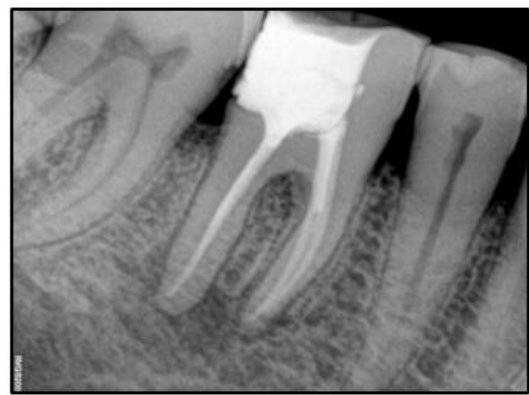**Figure 9:** Working length



**Figure 10:** Master cone



**Figure 11:** Obturation



**Figure 12:** Post-obturation

### 3. Discussion

In literature there is description of multiple canals in mesial roots of mandibular first molars hence the clinician treating a mandibular first molar should be cautious to examine the pulp chamber floor to rule out any of the anatomical variation. Proper access cavity preparation is a fundamental requirement for successfully detecting all root canal orifices. The use of a microscope enables dentists to confidently locate and treat extra canals. According to De Toubes et al., use of dental operating microscope improved locating the mid mesial canal (30%) than that of CBCT which accounted for 27%<sup>6</sup> as was done in our case.

Until today all the clinical cases reported have the middle mesial canal either joined with mesiobuccal canal or mesiolingual canal. It is same in the present case report and the midmesial canal joins with mesiobuccal canal in 44.5% and mesiolingual canal in 14.8% in the apical area according to Aminsobhani et al.<sup>7</sup>

Karapinar-Kazandag reported troughing preparation using microscope with a mean depth ranging between 0.7 and 1.1 mm to be adequate in finding an extra canal in mandibular molars,<sup>8[8]</sup> whereas Azim et al proposed a standardized troughing preparation with a 2-mm depth for better analyzing the deeper located canals.<sup>9</sup> Detection of middle mesial canal was increased upto 40% while troughing the floor of pulpal chamber in mesioapical direction for 2mm as was done in our cases.

The accessory canal system should be prepared cautiously due to the hourglass shape of the mesial root, which increases the risk of perforation. Difficulties in cleaning and shaping the mesial root canal during conventional treatment can lead to failure leading to retreatment or surgical intervention.

### 4. Conclusion

The diagnosis and treatment of mid-mesial canals can be complex, requiring the use of diagnostic imaging, precise instrumentation, and careful obturation procedures. In this

case report, we highlight the importance of taking a comprehensive approach in treating middle mesial canals.

## 5. Source of Funding

None.

## 6. Conflict of Interest

None.

## References

1. Cohen S. Orofacial dental pain emergencies, endodontic diagnoses and management. *Pathways of pulp*. 2001:31-75.
2. Vertucci FJ, Williams RG. Root canal anatomy of the mandibular first molar. *Journal of the New Jersey Dental Association*. 1974;45(3):27.
3. Baugh D, Wallace J. Middle mesial canal of the mandibular first molar: a case report and literature review. *Journal of endodontics*. 2004 Mar 1;30(3):185-6.
4. Pomeranz HH, Eidelman DL, Goldberg MG. Treatment considerations of the middle mesial canal of mandibular first and second molars. *Journal of endodontics*. 1981 Dec 1;7(12):565-8.
5. Hatipoglu FP, Magat G, Hatipoglu Ö, Taha N, Alfirjani S, Abidin IZ, Lehmann AP, Alkhawas MB, Buchanan GD, Kopbayeva M, Surendar S. Assessment of the prevalence of middle mesial canal in mandibular first molar: a multinational cross-sectional study with meta-analysis. *Journal of endodontics*. 2023 May 1;49(5):549-58.
6. de Toubes KM, de Souza Côrtes MI, de Abreu Valadares MA, Fonseca LC, Nunes E, Silveira FF. Comparative analysis of accessory mesial canal identification in mandibular first molars by using four different diagnostic methods. *Journal of Endodontics*. 2012 Apr 1;38(4):436-41.
7. Aminsobhani M, Bolhari B, Shokouhinejad N, Ghorbanzadeh A, Ghabraei S, Rahmani MB. Mandibular first and second molars with three mesial canals: a case series. *Iranian endodontic journal*. 2010;5(1):36.
8. Karapinar-Kazandag M, Basrani BR, Friedman S. The operating microscope enhances detection and negotiation of accessory mesial canals in mandibular molars. *Journal of Endodontics*. 2010 Aug 1;36(8):1289-94.
9. Azim AA, Deutsch AS, Solomon CS. Prevalence of middle mesial canals in mandibular molars after guided troughing under high magnification: an in vivo investigation. *Journal of endodontics*. 2015 Feb 1;41(2):164-8.

**How to cite:** Gupta S, Sankhyan V, Negi S, Ohri T / Seeing the unseen: Endodontic management of middle mesial canal. *Journal of Orofacial and Health Sciences* 2025;12(1):79–82