

## Review Article

## Anteroposterior dysplasia- an overview

Kumar VM<sup>1\*</sup>, Naik ES<sup>1</sup>, Naik MT<sup>1</sup>, Padala RG<sup>1</sup>, Gattu V<sup>1</sup> <sup>1</sup>Meghna Institute of Dental Sciences, Nizamabad, Telangana, India

## Abstract

Skeletal malocclusion is a collection of human craniofacial morphologic traits that either exceed or lack volume and proportion, resulting in an inappropriate relationship between the jaws and the temporomandibular joints. The cumulative impact of aberrant growth and development of the different skeletal units of the craniofacial complex on their functionality and outward appearance. Disorders characterized by sagittal disparity between the maxilla and the mandible are known as skeletal class II and III malocclusions. Sagittal disparities are not a separate entity; they are frequently accompanied with several major skeletal, dental, and functional abnormalities. When treating these malocclusions, one must clearly grasp the many components involved and how they correlate with the sagittal dimension.

**Keywords:** Extraction; Growth modification, Non-extraction, Skeletal malocclusion, Surgery**Received:** 25-09-2024; **Accepted:** 13-11-2024; **Available Online:**

This is an Open Access (OA) journal, and articles are distributed under the terms of the [Creative Commons Attribution-NonCommercial 4.0 International](https://creativecommons.org/licenses/by-nc/4.0/), which allows others to remix, and build upon the work noncommercially, as long as appropriate credit is given and the new creations are licensed under the identical terms.

For reprints contact: [reprint@ipinnovative.com](mailto:reprint@ipinnovative.com)

## 1. Introduction

Malocclusion is a developmental malformation ranging from mild to serious deformities of the dental or skeletal system, including systemic syndromic abnormalities. It could be restricted to the maxillofacial bones or affect the entire craniomaxillofacial complex.

Skeletal malocclusion is a collection of human craniofacial morphologic traits that exceed or decrease volume and proportion. It causes an incorrect jaw relationship, which affects the normal equilibrium of the face due to issues with dental occlusion and the temporomandibular joints.<sup>1</sup>

The sagittal or horizontal plane is the main concern in orthodontic assessment and planning of treatment among the three dimensions of the craniofacial anatomy. Disorders characterized by sagittal disparity between the upper and the lower jaw are known as class II and III skeletal malocclusions. Patients with Class II skeletal malocclusion have an anterior maxilla relative to the mandible, which could be caused by maxillary prognathism (increased upper jaw size and growth) or mandibular retrognathism (reduced lower jaw size and growth). Class III skeletal malocclusion, which

is distinguished by a retrusive maxilla position relative to the mandible, may be caused by maxillary retrognathism, mandibular prognathism or an intersection of the two. Patients with class II and III skeletal malocclusions have far less effective chewing skills. Furthermore, individuals with class III skeletal malocclusion exhibit a significant degree of abrupt and discontinuous masticatory movements as well as difficulty swallowing a bolus. Other parts of the digestive system may also be negatively impacted by Class II and III skeletal malocclusions.<sup>2</sup>

## 1.1 Prevalence

In permanent dentition, Class I, Class II, and Class III had worldwide distributions of 74.7%, 19.56%, and 5.93%, respectively, whereas in mixed dentition, they had global distributions of 72.74%, 23.11%, and 3.98%, respectively.<sup>3</sup>

In permanent stage of the dentition, Africans had the highest incidence of Class I malocclusion (89.44%), although the difference was not statistically significant. The greatest incidence was found in class II (22.9%) in Caucasians.<sup>3</sup>

Corresponding author: Kumar VM  
Email: [mareshkumarvallapu1@gmail.com](mailto:mareshkumarvallapu1@gmail.com)

## 1.2 Etiology

Environmental factors: A variety of environmental factors have been proposed as contributing factors to the formation of mandibular prognathism. These include congenital anatomic deficiencies (Monteleone and Davigneaud<sup>6</sup>, 1963), tonsil enlargement (Angle<sup>7</sup>, 1907), nasal obstruction (Davidov et al<sup>8</sup>, 1961), hormonal imbalance (Pascos et al<sup>9</sup>, 1960), endocrine disturbances (Downs<sup>10</sup>, 1928), posture (Gold<sup>11</sup>, 1949), and disease/trauma including premature shedding of the permanent first molars (Gold<sup>11</sup>, 1949) are among these.

Teratogens: These are the substances, such as chemicals, if administered at a certain point, have the potential to cause problems in reproduction. The majority of medications are not teratogenic because they do not disrupt regular development or, in large enough quantities, kill the embryo without causing problems. When teratogens are administered at greater quantities, they do have fatal effects, but at lower concentrations, they usually induce specific deformities. The most common cause of class III malocclusion is maxillary insufficiency caused by cleft lip and palate. Teratogens that cause cleft lip and palate include valium, 6-Mercaptopurine, aspirin, and cigarette smoke (hypoxia). Overconsumption of vitamin D results in early suture closure and may cause class III malocclusion.

Trauma: There are two main types of injuries that are visible from birth:

1. Intrauterine Molding: Stress on the growing face during pregnancy can cause parts to expand quickly to become distorted. Although the effects are there from birth, this falls under the category of birth injuries even though it is not one in the strict sense. Rarely, an arm may be forced across the face during pregnancy, leaving the baby severely lacking in the maxilla after birth.
2. Mandibular Birth Trauma:- Many patterns of facial deformities that are now proven to have other origins were formerly attributed to birth trauma. Even when a congenital disease is clearly present, many parents will still attribute their child's facial deformity to a birth injury, even after receiving explanations from their doctors.<sup>4</sup>

## 2. Classification of Skeletal Malocclusion

Skeletal classification is a working classification that has grown over time through clinical experience. It is based on Angle's classic classification<sup>12</sup> and Strang's interpretation of it (Fig 01).

**Skeletal class I:** An orthognathic face with the following important features:

1. Profile is straight
2. ANB angle is  $2^\circ \pm 2$
3. Facial angle (downs) ranges from 82–95° (mean 87.3°)

4. Angle of convexity (downs) ranges from +10 to -8.5° (mean 0°).

**Skeletal class II:** A retrognathic face, which may be caused by a prognathic maxilla or retrognathic mandible.

1. Profile is convex
2. ANB angle greater than 4°
3. Decreased facial angle
4. Higher angle of convexity
5. Extreme backwards rotation of the mandible may be observed.

**Skeletal class III:** A prognathic face may be due to a retrognathic maxilla or prognathic mandible. Possible significant features are:

1. Profile is concave
2. Chin is prominent
3. ANB angle less than 0°
4. Lesser facial angle.<sup>13</sup>

## 3. Classification of skeletal class II malocclusion:

Class II skeletal malocclusions can be sub classified into those comprised of either maxillary excess or mandibular deficiency.

1. Mandibular deficiency caused by position or size
2. Maxillary excess
3. Association of Maxillary excess and Mandibular deficiency.<sup>14</sup>

## 4. Classification of skeletal class III malocclusion:

Tweed (1966) categorized Class III malocclusion:

1. Pseudo class III malocclusion
2. Skeletal class III malocclusion

Moyers(1988) classified class III malocclusion as:

1. Osseous
2. Muscular
3. Skeletal

Jean Delaire<sup>15</sup> (1997) based on a sample of 172 records of class III subjects, taking into account maxillary- mandibular anomalies into sagittal plane only, grouped these into 9 discrete types:

1. Maxillary and mandibular retrusion
2. Maxillary normally positioned with mandibular protrusion
3. Maxillary and mandibular protrusion
4. Maxillary retrusion with normally positioned mandible
5. Maxilla and mandible normally positioned
6. Maxillary retrusion with mandibular protrusion
7. Maxilla normally positioned with mandibular retrusion

8. Maxillary protrusion with mandible normally positioned
9. Maxillary protrusion with mandibular retrusion

## 5. Diagnosis

### 5.1 Clinical features of skeletal class II malocclusion:

Extraoral features:

On extraoral clinical examination, class II subjects present

1. Convex profile,
2. Posterior divergence face
3. Retruded chin
4. Incompetent lips.

## 2.2 Intraoral features

1. Class II molar relationship
2. Upper incisors are proclined which increases the overjet/retroclined decreasing the overjet
3. Deep bite which may be traumatic
4. Upper arch is usually narrow, V shaped
5. Palatal vault is usually deep.<sup>16</sup>

## 6. Clinical Features of Skeletal Class III Malocclusion

Extraoral features:

On extraoral clinical examination, class III subjects present

1. A concave face, prominent chin and/or deficient maxilla
2. Malar deficient
3. Increased lower face height
4. Anatomically increased lower lip length.

### 6.1 Intraoral features

1. Zero or negative overjet
2. Narrow maxillary arch with crowding
3. Unilateral or bilateral posterior cross-bite
4. Retroclined mandibular incisors
5. Proclined maxillary incisors
6. A broad lower arch buccal segment showing compensations to accommodate narrow maxillary arch
7. Low tongue posture
8. A flat curve of Spee.<sup>13</sup>

## 6.2 Cephalometric analysis for anteroposterior dysplasia

Cephalometry was discovered in 1931 and has since become an important clinical tool for assessing the relationship between the jaws in transverse, vertical and anteroposterior planes. This examination is an essential part of orthodontic treatment planning. Over the years, a number

**Table 1:** Syndromes affecting face and jaws linked to mandibular deficiency and class II malocclusion

of analyses have been put forth to evaluate sagittal jaw relationships, with differing degrees of success and dependability.<sup>17</sup>

1. Assessment of Anteroposterior Dysplasia given by Wendell L Wylie
2. Down AB Plane Angle and Angle of Convexity<sup>17</sup>
3. Steiners Analysis<sup>18</sup>
4. Angle ANB
5. Jenkins a plane
6. Taylor AB linear Distance
7. A-D Distance and AXD angle
8. Wits Appraisal
9. Anteroposterior Dysplasia Indicator<sup>17</sup>
10. COGS Analysis<sup>19</sup>
11. Freeman AXB Angle
12. JYD Angle
13. Quadrilateral Analysis or Proportional Analysis
14. McNamara Maxillomandibular Differential
15. AF-BF Distance
16. APP-BPP Distance
17. FH-AB Plane Angle
18. Beta Angle
19. Overjet as Predictor of sagittal discrepancy
20. Yen angle
21. Dentoskeletal Overjet
22. W- Angle
23. Pi Analysis<sup>17</sup>

### 6.3 Syndromes associated with anteroposterior dysplasia

Syndromes affecting face and jaws linked to mandibular deficiency and class II malocclusion (**Table 1: Syndromes affecting face and jaws linked to mandibular deficiency and class II malocclusion** **Table 1: Syndromes affecting face and jaws linked to mandibular deficiency and class II malocclusion** **Table 1: Syndromes affecting face and jaws linked to mandibular deficiency and class II malocclusion** **Table 1: Syndromes affecting face and jaws linked to mandibular deficiency and class II malocclusion** **Table 1)**

Syndromes affecting the face and jaws where midfacial insufficiency is a key feature and may manifest as a class III relationship. (**Table 2:** Syndromes affecting the face and jaws where midfacial insufficiency is a key feature and may manifest as a class III relationship. **Table 2:** Syndromes affecting the face and jaws where midfacial insufficiency is a key feature and may manifest as a class III relationship. Table 2)

### Syndromes associated with mandibular prognathism (Table 3)

Syndrome	Clinical features	Etiology
Hemifacial macrosomia (Goldenhar syndrome)	Unilateral dysplasia of the ear, Hypoplasia of mandibular ramus, Cardiac and renal abnormalities	Most cases sporadic; few familial instances; pedigrees compatible with both autosomal dominant and autosomal

		recessive transmission.
Pierre robin syndrome	Micrognathia; Cleft lip and palate and Glossoptosis	Heterogenous
Treacher Collins Syndrome	Dysplastic low set ears; Downslanting palpebral fissures; micrognathia	Genetic/autosomal dominant

**Table 2:** Syndromes affecting the face and jaws where midfacial insufficiency is a key feature and may manifest as a class III relationship.

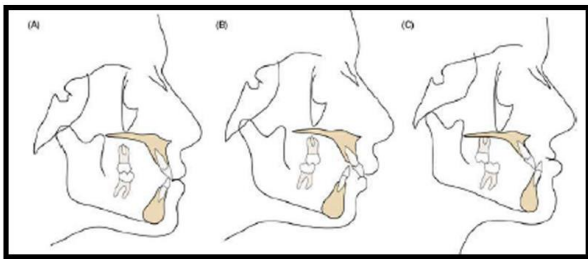
Syndrome	Clinical features	Etiology
Aperts syndrome	Craniosynostosis; midfacial deficiency; proptosis; hypertelorism; symmetric syndactyly of the hands and feet.	Autosomal Dominant
Crouz syndrome	Craniosynostosis; maxillary hypoplasia accompanied by relative mandibular prognathism; shallow orbits; proptosis	Autosomal dominant
Achondroplasia	Short-limbed dwarfism; enlarged head; depressed nasal bridge; lordosis; high palatal vault	Autosomal dominant
Down syndrome	Small cranium, midface and nasal bone depression, flat malar processes, upward slanting of eyes.	Trisomy 21

**Table 3:** Syndromes associated with mandibular prognathism

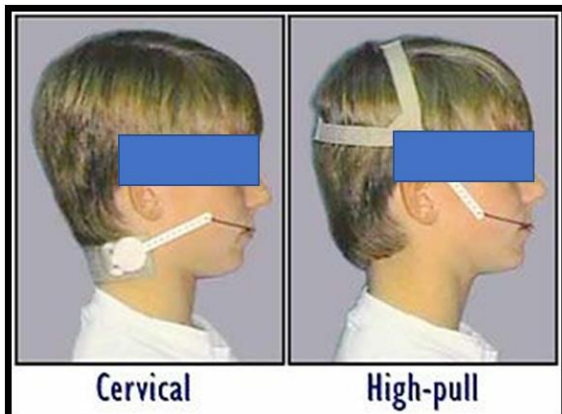
Syndrome	Clinical features	Etiology
Basal cell naevus (Gorlin) syndrome	Macrocephaly; frontal and parietal bossing; prognathism; multiple jaw cysts; multiple basal cell carcinomas; bifid ribs	Genetic/autosomal dominant
Klinefelter's syndrome	Mandibular prognathism; skeletal disproportion; gynaecomastia; small testes	Commonly XXY karyotype but XXXY and XXXXY may also occur
Osteogenesis imperfecta	Fragile bones; blue sclera; deafness; mandibular prognathism	Autosomal dominant (common type) <sup>13</sup>

**Table 4:** Fixed functional appliances

Rigid FFA	Flexible FFA	Hybrid FFA
Herbst and its modifications	Jasper Jumper	Eureka spring
Mandibular Anterior Repositioning Appliance	Adjustable bite corrector	Twin force bite corrector
Mandibular Protraction Appliance	Klapper super spring	Forsus resistant fatigue device
Magnetic Telescopic Device	Scandee tubular jumper	Sabbagh Universal spring 2
Biopedic appliance	Flex developer	Advance sync
Functional Mandibular Activator	Amoric Torsion Coils	
	The Bite Fixer	
	The SUPER spring II	
	The Curro Jumper	



**Figure 1:** Skeletal classification of malocclusion



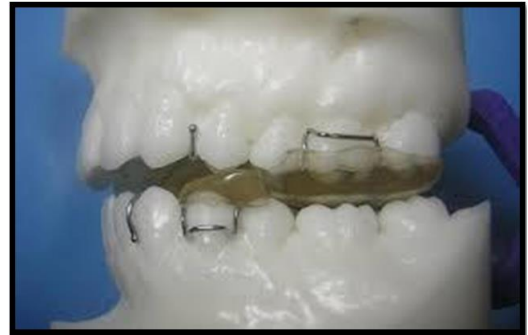**Figure 2:** Different types of Headgear



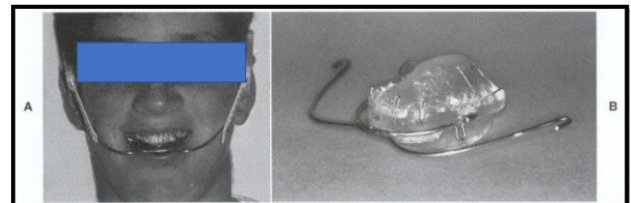
**Figure 3:** Activator



**Figure 4:** Bionator



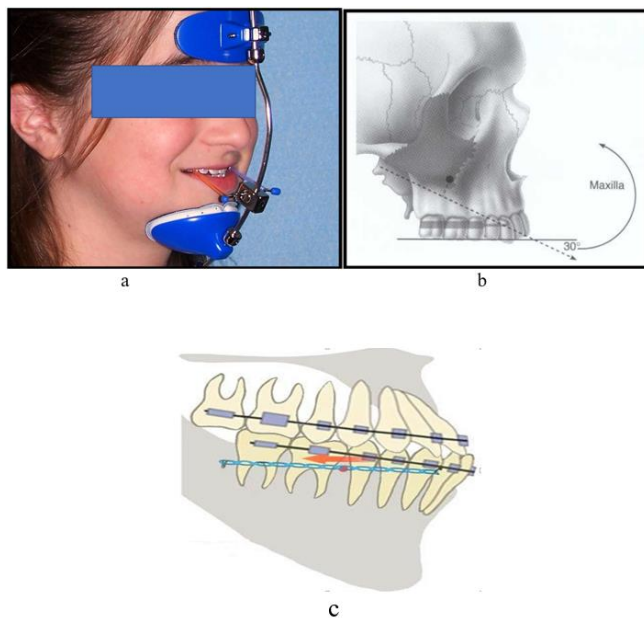
**Figure 5:** Twin block



**Figure 6:** Combination growth modification using headgear and activator.



**Figure 7:** Chin cup therapy



**Figure 8: a:** Facemask **b:** Maxillary protraction below the center of resistance produces anticlockwise rotation of the maxilla (arrow). Protraction elastics attached near the maxillary canine with a downward and forward pull of 30 degrees to the occlusal plane minimize bite opening **c:** mandibular total arch distalization using TADs

## 7. Discussion

### 7.1 Management of class ii skeletal malocclusion

There are three options for correcting any skeletal problem: Growth modification, Camouflage, and Orthognathic surgery. All three may be achievable in a growing child, but only the later two are viable alternatives in an adult.

### 7.2 Growth modification

Extraoral force appliances, functional appliances and combination of both are the three main types of orthodontic appliances used to modify the growth of class II skeletal abnormalities

#### 7.3 Extra oral appliance (Headgear)

A growth modification headgear is designed to deliver enough extraoral orthopaedic force which compresses the maxillary sutures, altering the pattern of bone apposition at these locations. The treatment goal is to restrict the maxillary growth to occur while the mandible continues to grow forward enough to "keep up" with the maxilla.

There are two types of headgear:

Facebow and

J-Hook headgear.

Extraoral force must be substantially greater, in the range of 400 to 600 g per side for a total of 800 to 1200 g, to optimize

bone change while reducing dental changes. Intermittent forces lasting 12 to 16 hours seem to be useful for facial orthopaedic changes<sup>20</sup> [20] (**Figure 2**).

### 7.4 Functional appliances

Class II functional appliances are intended to move the jaw downward and forward in order to promote or accelerate mandibular growth. In theoretically, moving the mandibular condyles out of the glenoid fossae lessens pressure on the actively growing condylar cartilage and changes muscle tension on the condyles, resulting in more endochondral growth that would normally occur.

*Different types of functional appliances are*

Activator (**Figure 3**)

Bionator (**Figure 4**)

Twin block (**Figure 5**)

Another favourable scenario for treatment with a functional appliance is having a mandibular deficit and normal maxillary development.<sup>14</sup>

*Combined growth modification treatment:* Headgears are meant to inhibit maxillary growth, and functional appliances to stimulate mandibular growth. It appears probable that a combined appliance strategy to orthopaedic treatment using extraoral force in conjunction with a functional appliance may produce larger cumulative skeletal growth effects than the usage of either appliance alone<sup>21</sup> (**Figure 6**).

### 7.3 Camouflage

Non-growing patients with a maxillary protrusion and/or combined mandibular deficiency can be treated using non-extraction or extraction treatment.

#### 7.3.1 Non-extraction treatment

Camouflage treatment without any extractions is indicated in mild cases where arch length discrepancy is minimal, and the upper and lower dental arches can accommodate the full complement of teeth without any adverse effects on the facial profile. The overjet is correctable with dental movements alone. Treatment options include intraoral molar distalization, correction of molar rotations, and an increase in arch perimeter with maxillary dentoalveolar expansion. Mild class II cases can also be corrected either with class II elastics or fixed functional appliances.

Fixed functional appliances and molar distalization:

#### 7.3.2 Fixed functional appliances

Successful treatment relies heavily on patient compliance in wearing the removable appliance and/or headgear. Therefore, in noncompliant patients, fixed functional appliances are alternate treatment strategies of functional appliances have been devised. These devices are broadly grouped as 'fixed



functional appliances' (FFA). Fixed functional appliances are often used in combination with full-banded fixed appliances.

#### 7.4 Indications

1. Correction of class II malocclusion due to retrognathic mandible in growing patients.
2. To utilize residual growth left in preadolescent patients
3. Uncooperative patients.

In adult patients

1. Can be used to enhance anchorage.
2. Used as a mandibular anterior repositioning splint in patients having TMDs
3. Presurgical muscle conditioning of patients with class II malocclusion
4. Post-surgical stability of class II / class III malocclusion

Sagittal changes:

Restraint of maxillary growth: headgear-like effect

Stimulation of mandibular growth.

Proclination of lower incisors.

Posterior movement of upper molars: headgear-like effect.

#### 7.5 Vertical changes

1. Eruption of lower molars; intrusion of lower incisors; reduction of overbite.
2. Proclination of lower incisors contributing to overbite reduction.

Classification of fixed functional appliance given by RITTO[22] (2001) (Table 04)

### 8. Molar Distalization

Class II malocclusion can be corrected without extraction by distalizing the maxillary molars with intraoral or extraoral pressures. Molar distalization is a treatment that involves distalizing molars using an internal or external appliance to acquire arch length in nonextraction situations. Typically, maxillary molars are distalized in class II div 1 instances where sagittal is necessary and the mandible is normal.

#### 8.1 Indications

1. Cases with minimal arch length disparity and modest class II molar relationship are associated with a normal mandible.
2. Borderline cases can be effectively addressed without extracting teeth, thereby gaining space required for necessary corrections.
3. Low mandibular plane angle with class II div 1 cases.
4. Impacted or blocked out canines.

#### 8.2 contraindications

1. Severe arch length tooth size discrepancy.
2. High mandibular angle cases are contraindicated for distalization of molars.

3. Distalization therapy presents additional challenges for patients who are fully developed. The forces needed for the third molar to distalize can result in anterior anchoring loss.<sup>23</sup>

Classification of Intraoral molar distalization appliance

#### 8.3 Dental/conventional anchorage derived appliances

##### a. Buccal appliance

1. Jigs with class II elastics
2. Repelling magnets
3. NiTi springs and wires
4. Jones jig
5. K loop

##### b. Palatal appliance

1. Pendulum appliance
2. Modifications of pendulum appliance
3. Fixed piston appliance by Greenfield
4. Distal Jet spring loaded palatal appliance

##### c. Buccal and palatal appliance

First class appliance

2. Skeletal anchorage using miniscrews/skeletal anchorage system

##### a. Palatal anchorage

1. Bone anchored pendulum appliance (BAPA)
2. Miniscrew supported pendulum appliance
3. Palatal supported all wire framework Beneslider
4. TAD supported buccal jig
5. TAD supported long arm buccal jig
6. TAD supported jig on fixed appliance

3. Combination of buccal and palatal application of force

Dual force distalizer supported with Nance button anchored and TAD.<sup>13</sup>

**Extraction treatment:** In certain clinical situations with large overjet, class II full cusp molar relation, and minimal crowding of the lower arch, camouflage treatment may be possible with the extraction of first premolars in the upper arch only and thereby maintaining class II molar relations

Indications for first premolar extraction in the upper arch only

1. For patients in class II who are non-growing and have a considerable overjet, extraction of upper premolars is frequently preferred over orthognathic surgery.
2. In class II situations where attempts to establish class I canine bonds through headgear or functional appliance treatment have failed.
3. A significant overjet, especially if the patient has thick lips.
4. Lack of mandible strength.

5. Less or no crowding in the lower arch.
6. The maximum anchorage necessary for an orthodontic camouflage.<sup>13</sup>

## 9. Surgery

Many skeletal Class II abnormalities in persons with little or no residual growth potential cannot be corrected effectively with orthodontic treatment alone. In the case of Class II skeletal malocclusions, surgical treatment options are at least as many as the underlying causes of the disorders. These possibilities can be neatly classified into five categories:

1. Mandibular advancement,
2. Mandibular total subapical advancement,
3. Maxillary impaction,
4. Maxillary apical subapical setback, or
5. A combined surgery for maxilla and mandible.<sup>24</sup>

### 9.1 Management of skeletal class iii malocclusion

There are three options for correcting any skeletal problem: growth modification, dental camouflage, and orthognathic surgery. All three may be achievable in a growing child, but only the latter two are viable alternatives in an adult.

### 9.2 Growth modification

#### 9.2.1 Chin cup therapy

A chin cup can be utilized for treating Class III skeletal malocclusion in cases where the maxilla is mainly normal and mandible is somewhat protruding. The goal of early chin cup treatment is to offer posterior mandibular placement and growth suppression or redirection (**Figure 7**).

The orthopaedic effects on mandible using chin cup involves

1. Mandibular development can be redirected vertically
2. Clockwise rotation of the mandible,
3. Closure of the gonial angle by remodelling of the mandible.
4. Retardation of vertical ramus growth.<sup>25</sup>

Most of the published trials recommended an orthopaedic force of 300-500 grams each side. Patients are instructed to wear the device for 14 hours each day. The orthopaedic force is often directed either through or below the condyle.

### 9.3 Protraction face mask therapy

The protraction facemask, often known as reverse headgear and one of the most commonly used interceptive techniques for developing skeletal Class III malocclusion (Fig 08.a). Elastics should be held at a 30° angle to the occlusal plane, close to the maxillary canines (Fig 8.b). The elastic pressures require wearing for 12-14 hours a day, with an average of 400-450 g per side(14-16 OZ).<sup>26</sup>

## 9.4 Camouflage

Where skeletal deformity is mild to moderate and orthodontic non-surgical treatment can correct the dental malocclusion without hurting the soft tissues of the face.

### 9.4.1 Non-extraction approach

Use of distalization of the lower arch using anchorage derived from mini-implants. The TADs have proved useful in providing the anchorage required to distalize the whole mandibular arch including second molars. However, the presence of third molars will have to be evaluated and if needed, it may require surgical extraction (**Figure 8**).

### 9.4.2 Extraction approach

Extraction decision should be executed only after due consideration of the goals of occlusion which vary considerably in class III malocclusion. According to the requirement of the case, the extraction choices could be:

1. Mandibular incisor
2. Upper second and lower first bicuspid
3. Only lower first bicuspid
4. Mandibular second molars.<sup>13</sup>

## 10. Surgery

Many skeletal Class III abnormalities in persons with little or no residual growth potential cannot be treated effectively with orthodontic treatment alone who requires orthognathic surgery. In terms of Class II skeletal malocclusions, the surgical treatment options are at least as abundant as the underlying causes of the problems. These options can be divided conveniently into three categories:

1. Mandibular setback,
2. Maxillary impaction,
3. A combined surgery for both maxilla and mandible.<sup>24</sup>

## 11. Conclusion

Many sagittal discrepancies are caused by a combination of major bone, dental, and functional imbalances rather than a single cause. When treating with these malocclusions, one must have a clear grasp of the many components involved and how they interact with the sagittal dimension. It should be noted that accurately identifying such cases necessitates the development of substantial diagnostic abilities. The crucial element to successfully resolve various sagittal discrepancies is that each patient's treatment procedure is tailored to the recognition, location, and nature of the affected regions of the craniofacial region. Sagittal discrepancies at various developmental stages can be treated using a variety of methods, including accelerating or inhibiting craniofacial development and correcting aberrant dental connections.



## 12. Source of Funding

None.

## 13. Conflict of Interest

None.

## References

- Greenberg BL. Etiology of Skeletal Malocclusion. *Craniomaxillofacial Reconstr Correct Bone Surg* [Internet]. Springer, New York, NY; 2002 [cited 2024 Jun 20]. p. 38–42. Available from: [https://link.springer.com/chapter/10.1007/978-0-387-22427-5\\_4](https://link.springer.com/chapter/10.1007/978-0-387-22427-5_4)
- Gershater E, Li C, Ha P, Chung C-H, Tanna N, Zou M, et al. Genes and Pathways Associated with Skeletal Sagittal Malocclusions: A Systematic Review. *Int J Mol Sci* 2021;22:13037.
- Alhammadi MS, Halboub E, Fayed MS, Labib A, El-Saaidi C. Global distribution of malocclusion traits: A systematic review. *Dent Press J Orthod* 2018;23:40.e1-40.
- William R P, Henry WF, Contemporary orthodontics, 6<sup>th</sup> edition. *Br Dent J* 2019;724.
- Strohmayer, W. (1937) Die Vereburg des Hapsburger Familientypus, Nova Acta Leopoldina, 5<sup>th</sup>, 219–96.
- Monteleone, L and Duvigneaud, JD (1963) Prognathism, Journal of Oral Surgery, 21, 190–5.
- Angle, E. H. (1907) Treatment of Malocclusion of the Teeth, 7th edn S. S. White Manufacturing Company, Philadelphia. p-327
- Davidov, S., Geseva, N., Donveca, T and Dehova, L. (1961) Incidence of prognathism in Bulgaria, Dental Abstracts, 6, 240.
- Pascoe, J., Hayward, JR and Costich, ER (1960) Mandibular prognathism, its etiology and a classification, J Oral Surg, 18, 21–4.
- Downs, W. G. (1928) Studies in the causes of dental anomalies, J Dent Res, 8, 267–379.
- Gold, J. K. (1949) A new approach to the treatment of mandibular prognathism, American Journal of Orthodontics, 35, 893–912.
- Angle EH. Classification of malocclusion. *Dent Cosmos*. 1899;41(3):248–64.
- Kharbanda OP. *Orthodontics: Diagnosis and Management of Malocclusion and Dentofacial Deformities* [Internet]. Elsevier India Pvt. Limited; 2009. Available from: <https://books.google.co.in/books?id=BwYzngEACAAJ>
- Bishara SE. *Textbook Of Orthodontics* [Internet]. Elsevier (A Division of Reed Elsevier India Pvt. Limited); 2001. Available from: <https://books.google.co.in/books?id=2YTDMgEACAAJ>
- Delaire J. Maxillary development revisited: relevance to the orthopaedic treatment of class III malocclusions. *Eur J Orthod*. 1997;19(3):289–311.
- Singh G. *Textbook of Orthodontics* 3<sup>rd</sup> edi [Internet]. Jaypee Brothers Medical Publishers Pvt. Limited; 2015. p–734 Available from: <https://books.google.co.in/books?id=MsIHCgAAQBAJ>
- Sundareswaran S, Kumar V. Cephalometric Assessment Of Sagittal Dysplasia – A Review Of Twenty One Methods. *J Indian Orthod Soc* 2014;volume 48:33–41.
- Steiner CC. Cephalometrics for you and me. *Am J Orthod* 1953;39:729–55.
- Burstone CJ, James RB, Legan H, Murphy GA, Norton LA. Cephalometrics for orthognathic surgery. *J Oral Surg*. 1978 Apr;36(4):269–77.
- Graber TM, Chung DDB, Aoba JT. Dentofacial orthopedics versus orthodontics. *J Am Dent Assoc* 1967;75:1145–66.
- Clark W. The Twin Block traction technique. *Eur J Orthod* 1982;4:129–38.
- Verma N, Garg A, Sahu S, Choudhary AS, Baghel S. Fixed functional appliance-A Bird's Eyeview.
- Umale V, Jalgaonkar N, Patil C, Gangadhar M, Sheth S. Molar distalization – A review. *Indian J Orthod Dentofac Res* 2018;4:146–50.
- Reyneke JP. *Essen Orthog Surg* p–312 [Internet]. Quintessence Publishing Company; 2003. Available from: <https://books.google.co.in/books?id=YVFqAAAAMAAJ>
- Graber LW. Chin cup therapy for mandibular prognathism. *Am J Orthod* 1977;72:23–41.
- Namara JA Jr. An orthopedic approach to the treatment of Class III malocclusion in young patients. *J Clin Orthod*. 1987 Sep;21(9):598–608.

**How to cite:** Kumar VM, Naik ES, Naik MT, Padala RG, Gattu V / Anteroposterior dysplasia- an overview. Journal of Orofacial and Health Sciences 2025;12(1):19-27