

Content available at: <https://www.ipinnovative.com/open-access-journals>

Journal of Orofacial and Health Sciences

Journal homepage: <https://www.johs.in/>

## Original Research Article

## Impact of resin infiltration in controlling proximal initial carious lesion: A randomized controlled trial

Avishek Singh<sup>1\*</sup>, B Aravind Anto<sup>2</sup>, Nikhil Bhardwaj<sup>3</sup>, Shailly Suri<sup>3</sup>, Shweta Dangi<sup>1</sup>, Aishwarya Mital<sup>4</sup><sup>1</sup>Dept. of Public Health Dentistry, NIMS Dental College and Hospital, Jaipur, Rajasthan, India<sup>2</sup>Dept. of Oral and Maxillofacial Surgery, NIMS Dental College and Hospital, Jaipur, Rajasthan, India<sup>3</sup>Dept. of Conservative Dentistry and Endodontics, PDM Faculty of Dental Sciences, Bahadurgarh, Haryana, India<sup>4</sup>Dept. of Periodontology and Implantology, NIMS Dental College and Hospital, Jaipur, Rajasthan, India

## ARTICLE INFO

## Article history:

Received 14-06-2024

Accepted 21-07-2024

Available online 24-09-2024

## Keywords:

Proximal lesions

Resin infiltration

Sealant

Remineralization

## ABSTRACT

**Introduction:** Dental caries is a major public health concern commonly affecting all age groups. Early detection and treatment of such lesions will limit the need for invasive treatment in the future. Resin infiltration is proposed as an encouraging non-invasive approach that can be used as an option in addition to non-operative and operative approaches to treatment.

**Aim:** To assess the efficacy of micro-invasive interventions (resin infiltration or sealing) for controlling caries progression on proximal surfaces.

**Materials and Methods:** The randomized clinical trial was carried out among 30 proximal caries lesion patients. After randomization participants were equally allocated in three groups; infiltration, sealant and placebo. DMFT & DMFS index and ICDAS were recorded at baseline, 3 months, 6 months and 9 months. The ANOVA and chi square tests were used to determine significant differences between groups. In all tests, p-values less than 0.05 were considered significant.

**Results:** There is a significant difference in the mean DMFT and DMFS value of infiltration and resin group as compared to control group p value 0.023 and 0.007 respectively. Also infiltration group had lower score as compared to resin group. Also, Infiltration group had the lowest mean ICDAS score at all time points, indicating the lowest severity of tooth decay, followed by the sealant group and then the Control group.

**Conclusion:** Our randomized controlled trial provides valuable insights into the effectiveness of resin infiltration, sealant, and placebo groups in preventing the progression of early enamel lesions. Resin infiltration was found to be the most effective method.

This is an Open Access (OA) journal, and articles are distributed under the terms of the [Creative Commons Attribution-NonCommercial 4.0 International](#), which allows others to remix, and build upon the work non-commercially, as long as appropriate credit is given and the new creations are licensed under the identical terms.

For reprints contact: [reprint@ipinnovative.com](mailto:reprint@ipinnovative.com)

## 1. Introduction

Dental caries is a serious public health issue that typically affects people of all ages. It is detrimental to an adult's overall health and dental health. Early proximal carious lesions have received special attention with the goal of preserving the most amount of tooth structure possible.<sup>1</sup> This is mostly due to the fact that restorative therapy

for interproximal lesions necessitates the removal of a significant portion of sound tissue, which forces the tooth into a treatment and retreatment cycle. Consequently, the necessity for intrusive treatment in the future will be reduced by early detection and treatment of such lesions. The preventative effects of several non-invasive approaches for treating early caries lesions and smooth surface caries have been beneficial. This covers applying sealants, fluoride, restoring resin in advance, and many other

\* Corresponding author.

E-mail address: [avisheksingh80a@gmail.com](mailto:avisheksingh80a@gmail.com) (A. Singh).

things.

Cueto and Buonocore initially introduced sealants in the 1960s as a component of preventive programmes to shield the occlusal tooth surfaces' pits and fissures from dental caries. By stopping the development of the microorganisms that cause dental caries, these sealants prevented dental decay.<sup>2</sup> On both the occlusal and proximal surfaces of the teeth, sealants prevent caries. However, because of the resin's limited penetration ability, a less viscous resin infiltration (RI) material was required to reach the lesion base, arrest the lesion, provide mechanical support, and enhance the enamel's appearance.

A relatively recent resin product called Infiltration Concept (ICON®) was created in Germany and is used to treat incipient lesions. On smooth surfaces, it enhances retention and guards against caries, but not on pit and fissure surfaces.<sup>3</sup> Unlike sealants, which merely serve as a mechanical barrier between the tooth structure and the oral environment, ICON® penetrates the lesion, renders the bacteria dormant, and stops the progression of caries. There are two ICON® products on the market, based on how they are utilised. ICON caries infiltrate-proximal is the first product, and it is used for early interproximal caries lesions. The second one is used to treat all other smooth surfaces and is called Icon - Caries Infiltrate smooth surface.

Applying fluorides, maintaining regular dental care, and eating a healthy diet can all help prevent dental caries lesions. These techniques are safe but frequently ineffective when dealing with patients who are noncompliant and lesions that are progressing more quickly. There is some uncertainty regarding the best course of action when it comes to restorative approaches, especially when it comes to interproximal caries lesions that radiographically extend into the outer and inner enamel or to the outer third of the dentin, because access to the lesion area necessitates the removal of significant amounts of healthy tissue. A new therapeutic option that falls between preventive and restorative therapies is resin infiltration, a revolutionary technique for stopping caries lesions. In this procedure, the resin substance

The resin substance fills in the lesion's porosities during this treatment. The resin completely plugs the tooth's pores, halting the spread of caries. The unique resins penetrate to a considerable depth and are designed for quick capillary penetration. A research investigation discovered that the advancement of proximal caries lesions in permanent teeth following treatment was less likely to occur when using resin infiltrant in addition to oral hygiene measures, as opposed to non-invasive techniques.<sup>4</sup>

In order to compare resin infiltration with a sealant and placebo group, the current study aimed to evaluate the impact of resin infiltration on the development of interproximal caries lesions. It was predicted that proximal lesions infiltrated with resin would exhibit a markedly

slower rate of caries progression than non-infiltrated control lesions.

## 2. Materials and Methods

A multi-arm randomised controlled clinical experiment was carried out in a private dental college and hospital in Jaipur. Utilising  $\alpha = 0.05$ , power = 0.8, and effect size = 0.5, the sample size was determined. A sample size of 21 participants was computed. After a year, there should be at least 30 participants, with a 20% drop-out rate anticipated. Thirty people made up the rounded sample size. Three groups of ten individuals each—A for infiltration, B for sealing, and C for placebo—were randomly assigned to the subjects. Participants in the study were those who, according to radiographs, had proximal caries lesions that reached into the enamel or outer half of the dentine (but not the pulp); they ranged in age from 18 to 40. Excluded from the study were participants who did not attend the entire study time, orthodontic patients undergoing treatment, and teeth that advanced to the cavitation stage during the study period.

### 2.1. Material used

ICON® pre- product (DMG, Hamburg, Germany) for resin infiltration; Solar Universal Bond (GC) for resin sealant, Interdental brush, Bitewing x-ray & holder, Mouth mirror, probe and tweezer, Dental floss, Orthodontic elastic band and Cotton rolls.

### 2.2. Procedure

Bitewing radiographs that were consistently geometrically aligned were taken during the initial appointment. A single, skilled examiner classified the radiographic proximal surfaces of posterior teeth. Then, clinical examination was conducted to assess DMFT, DMFS and the ICDAS score (International Caries Assessment and Detection System). Patients were randomly divided in three groups.

Group 1: the selected tooth with proximal lesion was dried and isolated with cotton rolls. After 120 seconds of 15% hydrochloric acid etching, 30 seconds of rinse time, and air drying, the surface was finished. Every etching procedure was followed by a cleaning procedure with ethanol. The 95% ethanol was allowed to completely evaporate for 30-60 seconds. The surface was gently dried with air and light cured in both side. The hypomineralised areas should look crispy and chalky white. Finally resin infiltration was done for 120 sec and light cured for 20 seconds, Reapplied infiltration for 30 seconds, then repeated light curing. Group 2: Orthodontic elastic bands were initially used to separate teeth and recall after one week. At second visit cotton rolls and plastic strip was used for isolation from the adjacent teeth. Pretreatment was identical to group 1, with an adhesive used to seal the lesion.

(Solare universal bond). Group 3: After two minutes, the process was repeated with a microbrush running through the crevices between teeth for thirty seconds.

Dietary recommendations, flossing techniques, and normal oral care instructions were given to each participant. At three, six, and nine months, a single examiner who was blind to the therapy groups that were chosen conducted recall and clinical evaluation. Should there be widespread, clearly visible cavitated lesions, the subjects will be directed towards surgical intervention.

Statistical analysis: With SPSS version 26, statistical analysis was carried out. For every variable, the mean and standard deviation were determined. To ascertain statistical significance, a one-way ANOVA was performed, and a p value of less than 0.05 was deemed statistically significant.

### 3. Results

The average mean age of the Infiltrate group (26.50), the Sealant group (28.40) and the Control group is 32.60 and the gender frequency in each group is almost the same, with seven males and three females in the Control and Sealant groups, and six males and four females in the Infiltrate group. (Table 1)

**Table 1:** Distribution of participants based on demographic details

Variables	Infiltration (n=10)	Sealant (n=10)	Control (n=10)
Age(mean)	26.50	28.40	32.60
Sex(frequency)	Male- 06 Female-04	Male- 07 Female-03	Male- 07 Female-03

#### 3.1. DMFT scores across three groups

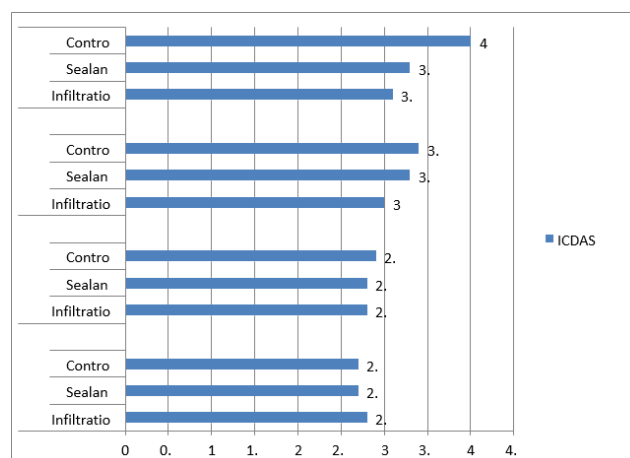
At baseline, the mean DMFT scores were 2.2 for Infiltration, 2.4 for Sealant and 1.9 for Control. At 9<sup>th</sup> month, the mean DMFT scores for Infiltration and Sealant remained the same as at 6<sup>th</sup> month, but the Control group had a higher mean DMFT score of 2.8. At 6<sup>th</sup> month and 9 month, the p value for Infiltration, Sealant and Control group was 0.05, which suggests a significant difference between these three treatments. (Table 2)

#### 3.2. DMFS scores across three groups

At baseline, the mean DMFS scores were 2.9 for Infiltration, 2.8 for Sealant and 2.6 for Control. At 3<sup>rd</sup> month, the mean DMFS scores remained unchanged for Infiltration and Sealant, while the Control group had a slightly higher mean DMFS score of 2.9. At 6<sup>th</sup> month, the mean DMFS scores increased slightly for Infiltration, Sealant and Control groups (3.2, 3.2 and 3.2, respectively). At 9<sup>th</sup> month, the mean DMFS scores for Infiltration remained the same as at 6<sup>th</sup> month, but the Sealant and Control group had a slightly higher mean DMFS score of 3.4, 4.1 (P value < 0.05).

(Table 3)

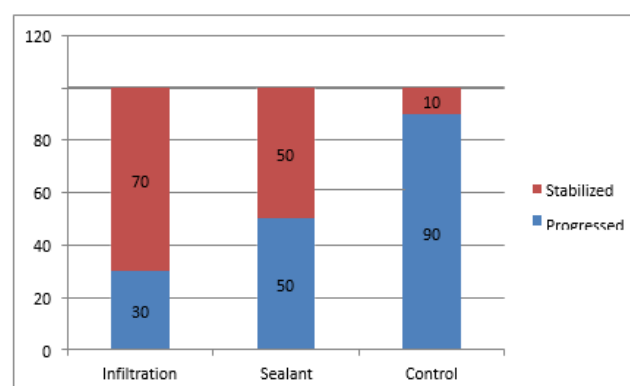
**ICDAS scores across three groups:** These results suggest that the Infiltration group had the lowest mean score at all time points, indicating the lowest severity of tooth decay, followed by the sealant group and also Control group. Amongst, Control group had maximum mean score at all time points, indicating the highest severity of tooth decay. The changes in mean scores over time also suggest that the Infiltration group may have had the most effective intervention in preventing or slowing the progression of tooth decay. (Figure 1)



**Figure 1:** Intergroup comparison of ICDAS score

#### 3.3. Radiographic assessment of lesions

At the end of the study in the infiltration group it was seen that 70% of the carious lesion were stabilized and in only 30% progression of the caries was seen, in sealant group it was 50% stabilized and progressed carious lesions and control group it was 90% carious lesions is progressed and in only 10% caries is stabilized. (Figure 2)



**Figure 2:** Proximal lesions' radiographic pair-wise reading progression after nine months from baseline

**Table 2:** Inter group comparison of DMFT for all participants

DMFT score		N	Mean	Std. Deviation	p value
Baseline	Infiltration	10	2.2000	1.39841	0.600
	Sealant	10	2.4000	1.07497	
	Control	10	1.9000	.73786	
3rd month	Infiltration	10	2.2000	1.39841	0.600
	Sealant	10	2.4000	1.07497	
	Control	10	2.2000	.73786	
6th month	Infiltration	10	2.3000	1.41814	0.045
	Sealant	10	2.5000	1.17851	
	Control	10	2.6000	1.03280	
9th month	Infiltration	10	2.3000	1.26491	0.023
	Sealant	10	2.5000	1.15470	
	Control	10	2.8000	1.17379	

**Table 3:**

DMFS score		N	Mean	Std. Deviation	p value
Baseline	Infiltration	10	2.9000	2.07900	0.774
	Sealant	10	2.8000	1.68655	
	Control	10	2.6000	.96609	
3 <sup>rd</sup> month	Infiltration	10	2.9000	2.07900	0.920
	Sealant	10	2.8000	1.68655	
	Control	10	2.9000	1.07497	
6 <sup>th</sup> month	Infiltration	10	3.2000	2.20101	0.975
	Sealant	10	3.2000	2.09762	
	Control	10	3.2000	.73786	
9 <sup>th</sup> month	Infiltration	10	3.2000	2.68535	0.007
	Sealant	10	3.4000	1.79196	
	Control	10	4.1000	1.17379	

#### 4. Discussion

Caries is a common oral disease caused by bacteria that can lead to tooth decay and cavities. Traditional treatment for caries on proximal surfaces involves removing the affected tooth structure and placing a restoration. However, micro-invasive interventions such as resin infiltration or sealing have emerged as a less invasive approach to managing caries. The purpose of the current study was to evaluate how well micro-invasive treatments work to slow the advancement of caries on proximal surfaces. The study's findings demonstrated the effectiveness of micro-invasive procedures in preventing the advancement of caries on proximal surfaces, such as resin infiltration and sealing. The interventions were found to be as effective as traditional restorative treatments, with similar success rates and lower risks of complications. The study also found that resin infiltration was more effective than sealing in preventing caries progression.

In the present study DMFT and DMFS values shows statistical significance difference at 9th month in between Infiltration vs. Control groups. In our study, at baseline, the mean DMFT scores were 2.2 for Infiltration, 2.4 for Sealant and 1.9 for Control. At the end of the study there is an increase of 2.3 for Infiltration, 2.5 for Sealant and 2.8 for

Control. which is contrast to Paris et al<sup>5</sup> study showed that Despite being the case in the first three years (mean DMFT after three and seven years = 9.4 and 9.3, respectively), the DMFT did not increase during the last four years.

The results suggests that Infiltration and Sealant treatments may be effective in reducing dental caries compared to Control treatment. Additionally, the Control group had the highest mean score at all time points, indicating the highest severity of tooth decay. The changes in mean scores over time also suggest that the Infiltration group may have had the most effective intervention in preventing or slowing the progression of tooth decay. The effectiveness of micro-invasive therapies for preventing the advancement of caries on proximal surfaces has also been examined in earlier research. A comprehensive evaluation and meta-analysis In a 2018 publication, Yuee Liang et al.<sup>6</sup> examined eight trials and discovered that resin infiltration was successful in halting the advancement of caries on proximal surfaces. The review came to the conclusion that resin infiltration might be a good substitute for conventional restorative procedures in the management of early carious lesions. Chen et al.<sup>7</sup> in 2021 conducted a comprehensive review and meta-analysis of 22 trials, concluding that resin infiltration and sealing were equally effective in preventing the advancement of caries on proximal surfaces. Micro-

invasive therapies appear to be a viable strategy for treating caries in its early phases, according to the review's findings.

Only 30% of the carious lesions in the infiltration group in the current study showed signs of progression, whereas 70% of the lesions were found to be stabilised, in sealant group it was 50% stabilized and progressed carious lesions and control group it was 90% carious lesions is progressed and in only 10% caries is stabilized. After 18 months, progression was seen in 2 out of 27 lesions (7%) in the test group and 10 out of 27 lesions (37%) in the control group, according to a study by Paris et al.<sup>4</sup> In contrast to 33.3% (14 out of 42) of the control lesions, Ammari et al.<sup>8</sup> saw caries progression in 11.9% (5 out of 42) of the test lesions. Ten test lesions (40%) and eighteen control lesions (72%) of the twenty-five individuals examined at the 24-month follow-up visit demonstrated caries progression, according to Bagher et al.<sup>9</sup> For 32 lesion pairs, a comparative pairwise assessment showed that control lesions (n = 7) had considerably higher progression than infiltration lesions (n = 1). Krois et al.<sup>10</sup>

Arsilan et al.<sup>11</sup> found that 2.2% of lesions in the test group (1/45) and 20% in the control group (9/45) showed progression. Arthur RA et al.<sup>12</sup> followed up with seventeen subjects (27 pairs of lesions), where only four subjects were caries-active. In the test group, 7.4% (2/27) of lesions progressed, compared to 18.5% (5/27) in the placebo group. Foster Page LA et al.<sup>13</sup> reported progression rates of 22.7% (15/66 lesions) in the test group and 43.5% (30/69 lesions) in the control group. Jorge RC et al.<sup>14</sup> observed caries progression in 24.1% (7/29) of test lesions versus 55.2% (16/29) of control lesions (p = 0.012).

Meyer-Lueckel et al. conducted an in vitro study comparing the penetration characteristics of ICON® with a conventional adhesive using confocal microscopy and transverse microradiography. They observed that ICON® achieved significantly greater maximum penetration depth and penetration percentage compared to the adhesive. The penetration of resin infiltrating material is hindered by the mineralized surface layer of the white spot lesion, which can be addressed through etching to remove this surface layer. Various types of etching gels were evaluated for their effectiveness in this process. Research indicated that using 15% hydrochloric acid for 90 to 120 seconds was notably more effective than using 37% phosphoric acid.<sup>15</sup>

However, it is important to note that there are limitations to our study. Initially, it's possible that the sample size was insufficient to identify minute variations across the groups. Second, the study only looked at short-term outcomes, and it is unclear how these treatments will perform in the long term. Based on our findings, it is recommended that resin infiltration be considered as a viable treatment option for early enamel lesions.

## 5. Conclusion

Our randomized controlled trial provides valuable insights into the effectiveness of resin infiltration, sealant, and

placebo groups in preventing the progression of early enamel lesions. While resin infiltration was found to be the most effective method, there are limitations to the study that must be taken into account. Future studies should focus on overcoming these shortcomings and offering stronger proof for the application of resin infiltration in therapeutic settings.

## 6. Source of Funding

None.

## 7. Conflict of Interest


None.


## References

1. Gomez SS, Basili CP, Emilson CG. A 2-year clinical evaluation of sealed noncavitated approximal posterior carious lesions in adolescents. *Clin Oral Inves.* 2005;9(4):239–82.
2. Saloranta AA, Forss H, Walsh T, Hiiri A, Nordblad A. Sealants for preventing dental decay in the permanent teeth. *Cochrane Data Syst Rev.* 2013;28(3):1830.
3. Kumar H, Palamara J, Burrow MF, Manton DJ. Resin infiltration-taking the first steps to filling the holes in cheese molars. *AR Aust Coll Dent Surg.* 2012;21:120–3.
4. Meligy OAESE, Alamoudi NM, Ibrahim SE, Felemban OM, Al-Tuwirqia AA. Effect of resin infiltration application on early proximal caries lesions in vitro. *J Dent Sci.* 2018;16(1):296–303.
5. Paris S, Bitter K, Krois J, Lueckel HM. Seven-year-efficacy of proximal caries infiltration - Randomized clinical trial. *J Dent.* 2020;93:103277.
6. Liang Y, Deng Z. Micro-invasive interventions for managing non-cavitated proximal caries of different depths: a systematic review and meta-analysis. *Clin Oral Inves.* 2018;22(8):2675–84.
7. Chen Y, Chen D, Lin H. Infiltration and sealing for managing non-cavitated proximal lesions: a systematic review and meta-analysis. *BMC Oral Health.* 2021;21(1):13.
8. Ammari MM, Jorge RC, Souza IP, Soviero VM. Efficacy of resin infiltration of proximal caries in primary molars: 1-year follow-up of a split-mouth randomized controlled clinical trial. *Clin Oral Invest.* 2018;22(3):1355–62.
9. Bagher SM, Hegaz FM, Finkelman M, Gowharji RA, and NS. Radio effectiveness of resin Infiltration in arresting insipient proximal enamel lesions in primary molars. *Pediatr Dent.* 2018;40(3):195–200.
10. Krois J, Göstemeyer G, Reda S, Schwendicke F. Sealing or infiltrating proximal carious lesions. *J Dent.* 2018;74:15–22.
11. Arslan S, Kaplan MH. The effect of resin infiltration on the progression of proximal caries lesions: a randomized clinical trial. *Med Princ Pract.* 2020;29(3):238–81.
12. Arthur RA, Zenkner JE, Junior JP, Correia RT, Alves LS, Maltz M. Proximal carious lesions infiltration-a 3-year follow-up study of a randomized controlled clinical trial. *Clin Oral Invest.* 2018;22(1):469–74.
13. Page LF, Beckett D, Ahmadi R, Schwass DR, Barra LDL, Moffat S, et al. Resin infiltration of caries in primary molars in a community setting: 24-month randomized controlled trial findings. *JDR Clin Trans Res.* 2017;2(3):287–94.
14. Jorge RC, Ammari MM, Soviero VM, Souza IP. Randomized controlled clinical trial of resin infiltration in primary molars: 2 years follow-up. *J Dent.* 2019;90:103184.
15. Lueckel HM, Wardius A, Krois J, Bitter K, Moser C, Paris S, et al. Proximal caries infiltration – Pragmatic RCT with 4 years of follow-

up. *J Dent.* 2021;111:103733.


### Author's biography

**Avishek Singh**, Post Graduate Student  <https://orcid.org/0000-0003-0635-9682>

**B Aravind Anto**, Post Graduate Student  <https://orcid.org/0009-0005-0142-3915>

**Nikhil Bhardwaj**, Post Graduate Student

**Shailly Suri**, Post Graduate Student

**Shweta Dangi**, Post Graduate Student  <https://orcid.org/0009-0001-6359-1069>

**Aishwarya Mital**, Post Graduate Student

**Cite this article:** Singh A, Aravind Anto B, Bhardwaj N, Suri S, Dangi S, Mital A. Impact of resin infiltration in controlling proximal initial carious lesion: A randomized controlled trial. *J Orofac Health Sci* 2024;11(3):133-138.