

Content available at: <https://www.ipinnovative.com/open-access-journals>

International Journal of Recent Innovations in Medicine and Clinical Research

Journal homepage: <https://www.ijrimcr.com/>

## Case Report

# A curious case of concealed abdominal hematoma in a 34-week pregnant woman, masquerading as eclampsia and diabetic ketoacidosis: A case report of maternal near-miss

Surya Kumar Maddala<sup>1\*</sup>, Amit Kumar Dey<sup>1</sup>, Alok Kumar Sahoo<sup>1</sup>,  
Sweta Singh<sup>2</sup>

<sup>1</sup>Dept. of Anesthesiology and Critical Care, All India Institute of Medical Sciences, Bhubaneswar, Odisha, India

<sup>2</sup>Dept. of Obstetrics and Gynaecology, All India Institute of Medical Sciences, Bhubaneswar, Odisha, India



## ARTICLE INFO

### Article history:

Received 14-06-2024

Accepted 10-07-2024

Available online 08-08-2024

### Keywords:

POCUS

Abdominal hematoma

Uterine rupture

Maternal near-miss

## ABSTRACT

A 34-week pregnant woman with apparently normal antenatal visits, presented to the Emergency department with drowsiness, very high blood pressure, and episodes of seizure 3 hours back. She was provisionally diagnosed as eclampsia with diabetic ketoacidosis. She was intubated and resuscitated for the same. However, in the intensive care unit, a point-of-care ultrasound of the abdomen showed free fluid and blood clots in the abdominal cavity, suggesting uterine rupture. Emergency surgical intervention saved the life of the patient.

This is an Open Access (OA) journal, and articles are distributed under the terms of the [Creative Commons Attribution-NonCommercial-ShareAlike 4.0 License](#), which allows others to remix, and build upon the work non-commercially, as long as appropriate credit is given and the new creations are licensed under the identical terms.

For reprints contact: [reprint@ipinnovative.com](mailto:reprint@ipinnovative.com)

## 1. Introduction

Maternal mortality is one of the major indicators of health care and a lot of resources are invested by the government to reduce maternal mortality.<sup>1,2</sup> Severe acute maternal morbidity (SAMM), also known as "near miss", is defined as "A very ill pregnant or recently delivered woman who would have died had it not been that luck and good care were on her side."<sup>3</sup> Point-of-care ultrasound (POCUS) has been found to be the greatest accessory widely used by intensivists managing critically ill patients, whereby they can accurately and rapidly assess for many pathologies at the bedside. Here, we present a case in which maternal life was saved by the POCUS.

## 2. Case Presentation

A 32-year-old obese G2P1L1 mother attended a local hospital due to a decreased perception of fetal movements for one day. Ultrasound (USG) of the abdomen was done, which showed intrauterine fetal demise (IUD). While under observation, the patient had seizure-like activity, and her blood pressure was 140/100 mm of Hg, suspected antepartum eclampsia. She received an injection of Magnesium sulfate 10 gm intravenously and was referred to our tertiary care hospital for further management.

On presentation to our obstetrics emergency, she was irritable and irrelevant talking, her pulse rate was 120/min, feeble, SpO<sub>2</sub> 90% on room air, and her BP, which initially was 190/100, came down to 90/60 mm of Hg. Pallor was present without any other significant physical finding. On per abdominal examination, the uterus was 32 weeks in size; fetal heart rate (FHR) was not recordable (confirmed by hand-held Doppler). There was no bleeding per vaginum.

\* Corresponding author.

E-mail address: [maddalasuryakumar@gmail.com](mailto:maddalasuryakumar@gmail.com) (S. K. Maddala).

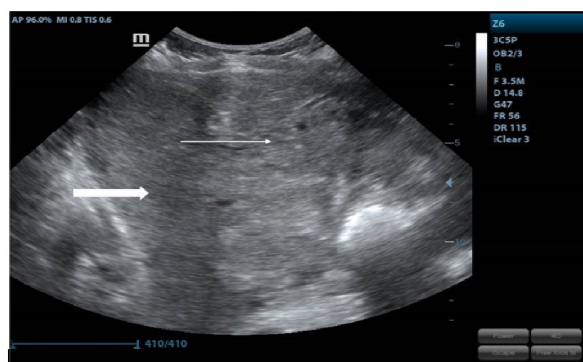
The patient was started with oxygen by face mask and rapid infusion of 1 liter of normal saline. Blood glucose was 400 mg/dl. Arterial blood gas showed severe metabolic acidosis, leading to suspicion of new-onset Diabetic ketoacidosis (DKA). In the course, the patient had one more episode of seizures. Injection of Lorazepam 4 mg IV was given, and the patient was shifted to the Intensive care unit (ICU) with oxygen support.

In the ICU, the patient's vitals were GCS-E2V1M4, pulse rate 130/min, and blood pressure unrecordable, ABG showed pH 6.9, PaO<sub>2</sub> 178 mmHg, PaCO<sub>2</sub> 38 mmHg, HCO<sub>3</sub> 10, lactate 12. The patient was intubated with rapid sequence intubation using fentanyl and succinylcholine with the help of bougie, as the airway was difficult due to obesity and pregnancy-related changes. Adequate ventilation was assured.

Noradrenaline was initially started at a low 4 mcg/kg/hr through the peripheral line. Insulin infusion started given high blood glucose, and sodium bicarbonate infusion started because of severe metabolic acidosis causing hemodynamic instability.

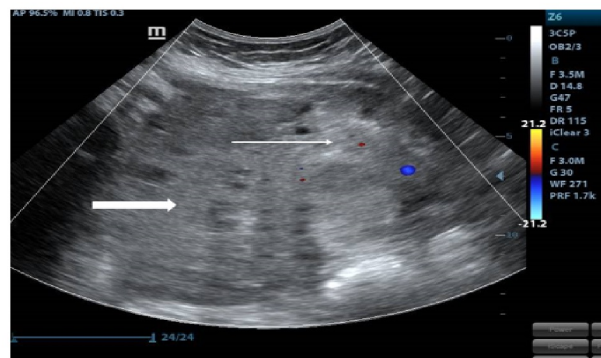
The response to the initial vasopressor was not adequate. Hence, central venous access was done, and noradrenaline support was increased to a dose of 20 mcg/kg/hr along with Vasopressin 2.4 unit/hr and Adrenaline 10 mcg/kg/hr in an attempt to maintain the mean arterial pressure. With this, we searched for any possible cause of undifferentiated shock.

A point-of-care ultrasound of the abdomen was done, which showed the uterine cavity with a placenta and a huge retro placental hematoma (Figure 1), which did not take up color (Figure 2). The fetus was found outside the uterine cavity in the peritoneal cavity, surrounded by heterogeneous lesions suggestive of blood clots (Figure 3).

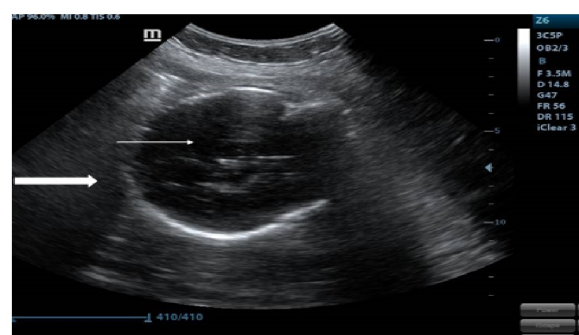


**Figure 1:** 2D grey scale ultrasound showing uterine cavity with placenta (thin arrow) with retro placental hematoma (thick arrow). Note: The absence of fetus inside the uterine cavity.

In the meantime, a thorough history of the patient's progress and evaluation of recent documents showed that Tab Misoprostol 200 mcg SL was administered to the patient, which is a very high dose for labor induction



**Figure 2:** Color Doppler ultrasound showing the placenta (thin arrow) and retro placental hematoma (thick arrow) with no vascularity.



**Figure 3:** 2D grey scale ultrasound showing fetal head (thin arrow) lying in the peritoneal cavity surrounded by hetero-echoic lesions (thick arrow) suggestive of blood clots.

considering the later stage of pregnancy.

Due to suboptimal visualization by bedside ultrasound given obese maternal habitus, this finding was confirmed by a radiologist.

Consent was obtained from her husband, and with the maximal support of vasopressors, the patient was shifted to the operation theatre with information to the blood bank for the need for a massive transfusion.

In the operation theater, ASA standard monitors were attached and vitals were PR 130/min BP 90/40 with maximal vasopressor support. The patient was induced with, fentanyl 2mcg/kg, ketamine, and atracurium 0.5 mg/kg and maintained with O<sub>2</sub> and sevoflurane.

On laparotomy, a hemoperitoneum of 2,500 ml of fresh blood and 500 ml of clotted blood was suctioned out. The dead fetus was lying in the peritoneal cavity and was delivered by breech extraction. The Placenta was delivered in toto. The uterus showed scar rupture with the extension of rupture till the fundus of the uterus, pooling of blood was seen, and bilateral fallopian tubes and ovaries were normal. Obstetric total hysterectomy was performed as a life-saving measure.

Massive blood transfusion protocol was activated and 3 PRBC, 3 FFP, 3 RDP were given in the ratio of 1:1:1. 1 ampule calcium gluconate 10 ml 10% slow IV over 10 minutes was given to avoid hypocalcemia.

After completion of the surgery, the patient was shifted to ICU. The vasopressor support gradually reduced over the next 12 hours, ABG returned normal, and the patient was extubated next day. She was discharged on the fourteenth postoperative day in good condition.

### 3. Discussion

In this patient, initial blood pressure and blood glucose were very high in response to the ongoing stress of uterine rupture or dextrose infusion from the peripheral center, which led to suspicion of DKA as ABG also showed severe metabolic acidosis due to shock (acute massive blood loss). This severe acidosis and hypotension may lead to a seizure that was further confused with eclampsia, as she had very high BP.

There was no bleeding per vaginum in this case, probably due to the sealing effect of a big baby on the cervix. On examination, the uterine contour appeared well maintained. This was probably due to the masking effect of obese maternal habitus.

Pregnants with preeclampsia should have a history of high blood pressure. However, there is no such history in this case. Also, the husband revealed that she had received a tablet of Misoprostol 200mcg peroral instead of PV.

According to the Nguetack et al., misoprostol was responsible for 71% of uterine rupture.<sup>4</sup>

Pregnant patients with severe shock not responding to resuscitation with intravenous fluids and vasopressor support should lead to suspicion of ongoing bleeding inside the abdomen.

POCUS, where imaging is undertaken at the bedside, clinic, or emergency department (ED) by the clinician overseeing treatment, is a rapid form of assessment to find the bleeding sources that are not obvious. Indications for POCUS in obstetrics and gynecology are many and include Acute pelvic pain in patients of reproductive age and bleeding in early pregnancy. Hemodynamically unstable patient, etc.<sup>5,6</sup> Timely performed POCUS saved the mother's life in our case and avoided maternal near-miss.<sup>7</sup>

### 4. Conclusion

Timely intervention with a quick diagnosis with a skilled multidisciplinary team involving an obstetrician, anaesthesiologist, radiologist, and intensivist will help in complete recovery from maternal near-miss events.

A bedside point-of-care ultrasound helps in arriving at the correct diagnosis, thereby saving maternal lives.

### 5. Source of Funding

None.


### 6. Conflict of Interest

None.


### References

1. Evaluating the quality of care for severe pregnancy complications: The WHO near-miss approach for maternal health; 2011. Available from: [https://iris.who.int/bitstream/handle/10665/44692/9789241502221\\_eng.pdf](https://iris.who.int/bitstream/handle/10665/44692/9789241502221_eng.pdf).
2. Transforming our world: The 2030 agenda for sustainable development. In: UN 2023 Water Conference. New York, NY; 2023. Available from: <https://sdgs.un.org/2030agenda>.
3. Mantel GD, Buchmann E, Rees H, Pattinson RC. Severe acute maternal morbidity: A pilot study of a definition for a near-miss. *Br J Obstet Gynaecol*. 1998;105(9):985–90.
4. Nguetack CT, Ekane GH, Yaya EA, Njamen TN, Kamgaing JT, Egbe TO, et al. Uterine rupture in the Douala general hospital, Cameroon: Prevalence, risk factors, management and prognosis. *Health Sci Dis*. 2016;17(1).
5. Collins K, Collins C, Kothari A. Point-of-care ultrasound in obstetrics. *Australas J Ultrasound Med*. 2019;22(1):32–9.
6. Conducting a maternal near-miss case review cycle at hospital level: Manual with practical tools. Europe; 2016. Available from: <https://www.qualityofcarenetwork.org/knowledge-library/conducting-maternal-near-miss-case-review-cycle-hospital-level-manual-practical>.
7. Tunçalp O, Hindin MJ, Souza JP, Chou D, Say L. The prevalence of maternal near miss: A systematic review. *BJOG Int J Obstet Gynecol*. 2012;119(6):653–9.

### Author biography

**Surya Kumar Maddala**, Senior Resident  <https://orcid.org/0000-0001-6676-8782>

**Amit Kumar Dey**, Senior Resident  <https://orcid.org/0009-0002-6026-7957>

**Alok Kumar Sahoo**, Additional Professor  <https://orcid.org/0000-0001-5006-5513>

**Sweta Singh**, Professor and HOD  <https://orcid.org/0000-0002-1206-2474>

**Cite this article:** Maddala SK, Dey AK, Sahoo AK, Singh S. A curious case of concealed abdominal hematoma in a 34-week pregnant woman, masquerading as eclampsia and diabetic ketoacidosis: A case report of maternal near-miss. *Int J Recent Innov Med Clin Res* 2024;6(2):46–48.