

Content available at: <https://www.ipinnovative.com/open-access-journals>

The Journal of Dental Panacea

Journal homepage: <https://www.jdentalpanacea.org/>

Case Report

Oral cavity- Mirror to the body - A case report

Vidushi Sheokand^{1,*}, Preeti Upadhyay², Amit Bhardwaj¹, Shalini Kapoor¹,
Shilpa Kamra¹, Himanshu Deswal¹

¹Dept. of Periodontics, SGT University, Gurugram, Haryana, India²Inderprastha Dental College, Ghaziabad, Uttar Pradesh, India

ARTICLE INFO

Article history:

Received 22-01-2022

Accepted 23-01-2022

Available online 31-01-2022

Keywords:

Gingival enlargement

Thyroid stimulating hormone

Hypothyroidism

Retained deciduous teeth

Dry thick lips

ABSTRACT

Gingival enlargement is a bizarre condition causing aesthetic, functional, psychological and masticatory problems in oral cavity. Gingival enlargement has been associated with a variety of factors, including medications, inflammation and systemic disorders. Recent periodontal studies have suggested a mild to moderate association between periodontal disease and thyroid disorders due to altered gingival microcirculation compromising the first line of defence which may result in gingival hyperplasia. This case report is an unusual presentation of gingival fibromatosis in a 20 year old girl. The gingival hyperplasia and associated clinical features alerted us to the possibility of altered functioning of the thyroid gland. Subsequent investigations revealed subclinical hypothyroidism. This case report emphasizes, yet again the adage/saying that 'the oral cavity is the mirror to the body!'

This is an Open Access (OA) journal, and articles are distributed under the terms of the [Creative Commons Attribution-NonCommercial-ShareAlike 4.0 License](#), which allows others to remix, tweak, and build upon the work non-commercially, as long as appropriate credit is given and the new creations are licensed under the identical terms.

For reprints contact: reprint@ipinnovative.com

1. Introduction

For long, physicians and dentists have paid close attention to their own respective fields. However, in recent years, there has been intense interest in potential associations between periodontal disease and various chronic systemic diseases and conditions. The important relationship of oral health to general health and well-being is also recognised by Surgeons General report 2000, the report describes oral cavity as an Sentinel/ Early Warning System for systemic health and as a Potential source of pathology affecting other tissues & organs.¹

Gingival enlargement is a bizarre condition causing aesthetic, functional, psychological and masticatory problems in oral cavity. Gingival enlargement has been associated with a variety of factors, including medications, inflammation and systemic disorders. Recent periodontal

studies have suggested a mild to moderate association between periodontal disease and thyroid disorders due to altered gingival microcirculation compromising the first line of defence which may result in gingival hyperplasia.²

The thyroid gland is a major regulator of metabolism and affects all of the body functions. Thyroid dysfunction is the second most common glandular disorder of the endocrine system which may rear its head in any system in the body including the mouth. The oral cavity is adversely affected by either an excess or deficiency of these hormones.³

The purpose of this case report is to highlight association between Gingival fibromatosis and altered thyroid function.

2. Case History

A 20 year old girl reported with a chief complaint of swollen gums since 1 year. This was her first visit to dentist and patient had no significant medical history or deleterious habit.

* Corresponding author.

E-mail address: vidushi.sheokand@gmail.com (V. Sheokand).

On intraoral examination the color of the gingiva was reddish pink with generalised diffuse gingival enlargement which was more massive in mandibular anterior region covering the 2/3 of the crowns. Generalised bleeding on probing was present with probing depth of 5-6 mm. Minimal calculus or plaque deposits were visible with naked eye. (Figure 1).

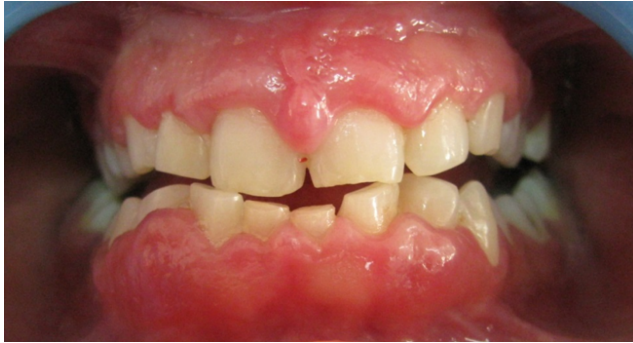

Fig. 1:

Other noticeable intra oral findings were deep bite, tongue tie, (Figures 2 and 3). Retained deciduous 71, 81, Congenitally missing tooth buds 31,41, Multiple carious teeth 16,24,26,27,36,37 and Root stumps 46 were present. (Figure 4).

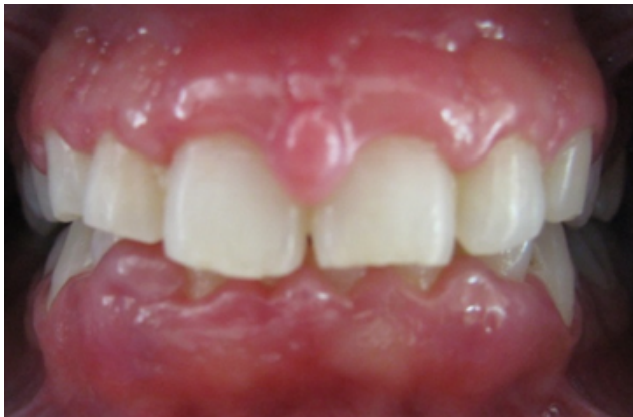

Fig. 2:

Phase 1 therapy consisting of scaling and root planing, restoration of carious teeth and extraction for root stumps was planned, simultaneously routine blood investigations comprising of complete blood count was advised to the patient.

Patient was recalled for checkup after 15 days of scaling and to our surprise no regression in enlargement was observed after phase 1 therapy.(Figure 5)

Massive gingival enlargement in this patient, with minimal calculus, which did not regress after phase 1 therapy and numerous oral findings alerted us that some

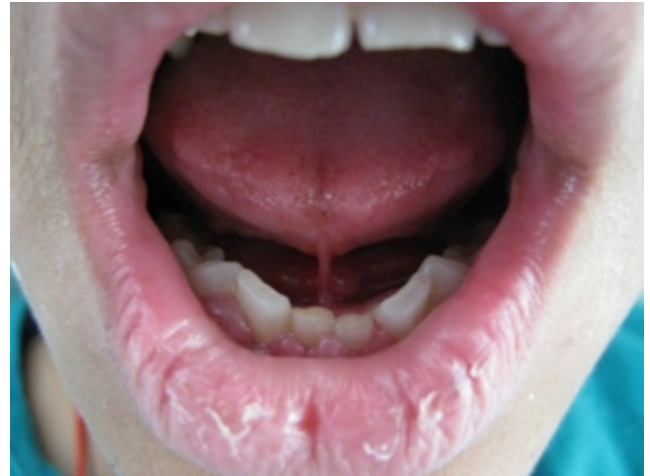

Fig. 3:

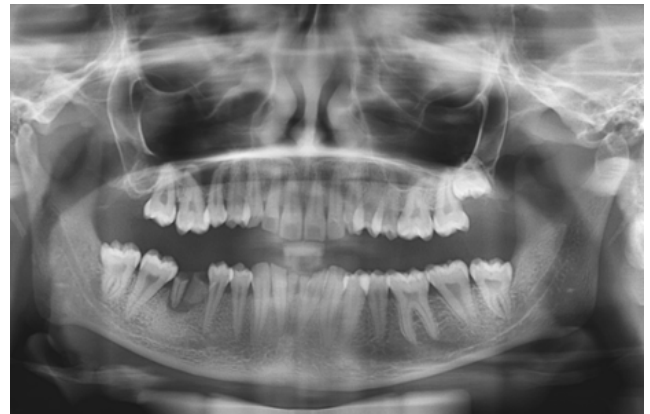

Fig. 4:

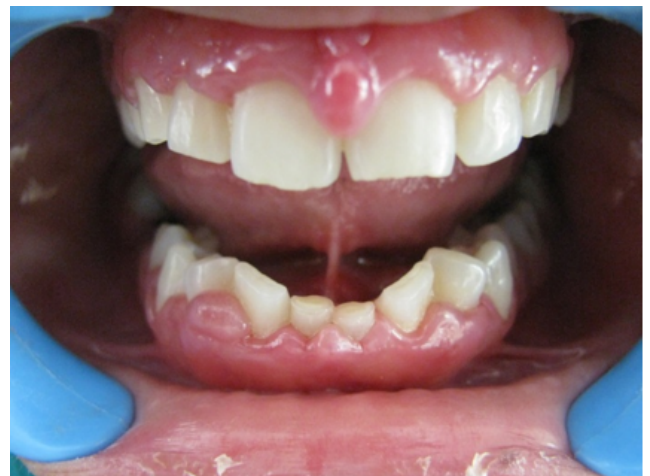

Fig. 5:

underlying systemic factor might be responsible for the condition.

Again detailed medical history was taken for the patient who now disclosed intolerance towards cold thus further blood investigations for thyroid hormones and sex hormones were advised to the patient. The blood investigations revealed increased levels of thyroid stimulating hormones, indicating hypothyroidism.

| S.No | Investigation | Result | Units | Reference |
|------|---|--------|--------|------------|
| 1. | Iodothyronine Total (TT3) (electrochemiluminescence) | 1.07 | ng/ml | 0.80-2.0 |
| 2. | Thyroxine Total (TT4) (electrochemiluminescence) | 7.0 | µg/dl | 5.1 – 14.1 |
| 3. | Thyroid Stimulating Hormone (TSH) (electrochemiluminescence) | 7.31 | mIU/ml | 0.51-4.30 |
| 4. | Estradiol (electrochemiluminescence) | 196 | Pg/ml | |
| 5. | Progesterone (electrochemiluminescence) | 8.89 | ng/ml | |

Before undertaking any further dental procedure, the patient was referred to endocrinologist for expert advice.

Endocrinologist confirmed the diagnosis of hypothyroidism, though she decided not to start with medications and gave a green signal to carry out further dental treatment.

Patient was, thus, advised to monitor her thyroid function tests annually.⁴

Gingivectomy and Gingivoplasty were taken up in phased manner. (Figure 6)

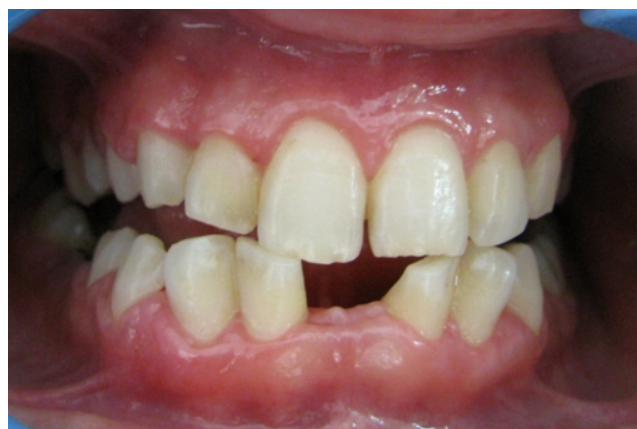

Fig. 6:

3. Discussion

Subclinical hypothyroidism, is usually diagnosed when peripheral thyroid hormone levels are within normal reference laboratory range but serum thyroid-stimulating hormone (TSH) levels are mildly elevated. (Figure 7).

This condition occurs in 3% to 8% of the general population.⁵ It is more common in women than men, and

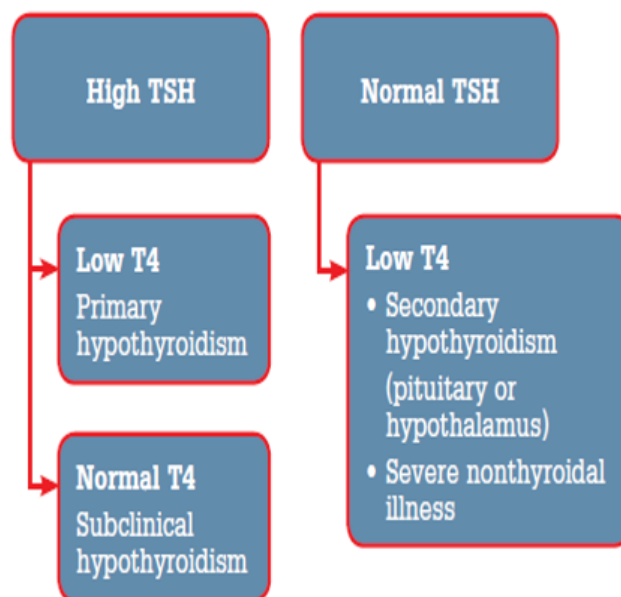


Fig. 7:

its prevalence increases with age.⁶ The most important implication of individuals with long standing untreated hypothyroidism is highly likelihood of progression to clinical hypothyroidism.⁵ Such individuals are also at increased risk for developing cardiovascular disease, difficulty in antipating pregnancy, premature labour, pre-eclampsia, low birth weight, neural disturbances^{6,7} etc.

Thus patient with a thyroid dysfunction, as well as the patient taking medications for it, requires proper risk management before considering dental treatment by the dentist. Thus, communication of dentist and physician must be bidirectional, not only maintain patient's oral and thyroid health but also overall well-being of the patient.

In this case the exact cause for the gingival enlargement, was not clear but the patients appearance, her history of intolerance to cold. Other oral findings like gingival enlargement, retained deciduous incisors, thick dry lips all indicated thyroid malfunctioning.²

Pathophysiology behind thyroid malfunctioning and gingival disease is explained as below. (Figure 8)

Large-scale randomized studies are needed for evidence-based recommendations regarding screening for mild thyroid failure and levothyroxine therapy for subclinical hypothyroidism. Currently, the practical approach is routine levothyroxine therapy for persons with a persistent serum TSH of more than 10.0 mIU/L and individualized therapy for those with a TSH of less than 10.0 mIU/L.⁶

Though in our case physician advised to monitor the condition of patient closely and appreciated our promptness to help in diagnosing the patient's condition at an early stage.

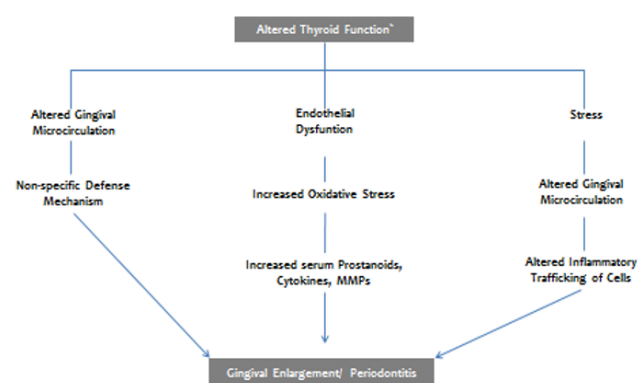


Fig. 8:

Better understanding of this correlation will help both dental and medical professionals to determine the best approach to patient care.

4. Conclusion

As part of a health care team, the dentist plays an important role in detecting thyroid abnormalities. We may be the first to suspect a serious thyroid disorder and aid in early diagnosis. Better understanding of this correlation will help both dental and medical professionals to determine the best approach to patient care.

Indications for treatment in subclinical hypothyroidism are not established, but general guidelines can be offered. Greater magnitude and duration of TSH elevation and higher titers of antithyroid antibodies increase the probability that the condition will progress to overt hypothyroidism.⁷

While a number of interactions have been identified, additional research is required to determine whether this association between increased TSH level and gingival enlargement is causal or coincidental!

This case report emphasises, yet again the adage/saying that ‘the oral cavity is the mirror of the body’.

5. Conflict of Interest

The authors have stated explicitly that there are no conflicts of interest in connection with this article.

6. Source of Funding

None

References

1. U.S. Department of Health and Human Services. Oral Health in America: A Report of the Surgeon General. Rockville, MD: U.S. Department of Health Human Services, National Institute of Dental and Craniofacial Research, National Institutes of Health; 2000.
2. Chandana S, Bathla M. Oral manifestations of thyroid disorders and its management. *Indian J Endocrinol Metab.* 2011;15(2):113–6. doi:10.4103/2230-8210.83343.
3. Pinto A, Glick M. Management of patients with the thyroid disease: Oral health considerations. *J Am Dent Assoc.* 2002;133(7):849–58. doi:10.14219/jada.archive.2002.0299.
4. Thyroid function test: Diagnoses and monitoring of thyroid function disorders in adults. Guidelines and Protocols Advisory Committee, British Columbia Medical Association; 2010.
5. Karmisholt J, Andersen S, Laurberg P. Variation in thyroid function tests in patients with stable untreated subclinical hypothyroidism. *Thyroid.* 2008;18(3):303–8. doi:10.1089/thy.2007.0241.
6. Fatourehchi V. Subclinical Hypothyroidism: An Update for Primary Care Physicians. *Mayo Clin Proc.* 2009;84(1):65–71.
7. Victor A. Subclinical Hypothyroidism: Deciding When to Treat. *Am Fam Physician.* 1998;15(4):776–80.

Author biography

Vidushi Sheokand, Reader

Preeti Upadhyay, Professor

Amit Bhardwaj, Professor and HOD

Shalini Kapoor, Professor

Shilpa Kamra, Reader

Himanshu Deswal, PhD. Scholar

Cite this article: Sheokand V, Upadhyay P, Bhardwaj A, Kapoor S, Kamra S, Deswal H. Oral cavity- Mirror to the body - A case report. *J Dent Panacea* 2021;3(4):181-184.