



Case Report

A case report of comminuted mandibular fracture treated successfully with open reduction and internal fixation

Mayukh Pandit^{1,*}, Arindam Mandal²

¹Dept. of Anatomy, Triveni Institute Of Dental Sciences Hospital & Research Centre, Bilaspur, Chhattisgarh, India

²Dept. of Oral and Maxillofacial Surgery, DESUN Hospital, Kolkata, West Bengal, India



ARTICLE INFO

Article history:

Received 10-04-2021

Accepted 24-04-2021

Available online 14-05-2021

Keywords:

comminuted bony segments
Open Reduction and Internal Fixation
reconstructive CT Scan
miniplates.

ABSTRACT

Mandible is the most prominent, largest and strongest bone of facial skeleton which is in direct relation to the base of skull. In majority of cases due to trauma, there is a breakthrough in mandible which often results in mandibular fracture. If there is presence of multiple fracture lines it is the case of comminuted fracture which further results in small pieces in the same area of mandible. Our following case report describes about a 35 year old male patient who met with severe road accident due to head on collision. With the aid of 3D reconstructive CT scan of face revealed comminuted fracture of anterior mandible along with gross malocclusion. The patient underwent Open reduction and Internal fixation which successfully reduced all communicated bony segments and fixation was achieved with application of miniplates, along with preservation of mental nerves. Satisfactory outcome was achieved from both aesthetic and functional point of view.

© This is an open access article distributed under the terms of the Creative Commons Attribution License (<https://creativecommons.org/licenses/by/4.0/>) which permits unrestricted use, distribution, and reproduction in any medium, provided the original author and source are credited.

1. Case Report

A 35 years old male patient met with sudden severe road accident due to head on collision and lost his consciousness. He was admitted at Intensive Care Unit at Desun Hospitals, Kolkata where proper neurological support and basic health aids were provided. A 3D reconstruction CT Scan of face was conducted. The report revealed that comminuted fracture of anterior mandible with gross malocclusion.

The management for this case was ruled out to perform an Open Reduction and Internal Fixation surgery.¹ Open Reduction is a surgical procedure where fracture bone ends are exposed by intraoral or extraoral approach and brought into an alignment. Internal Fixation of mandibular fracture describes the fixation of fractured fragments in their normal anatomical relationship to prevent displacement and achieve proper fixation. Under General Anesthesia, patient underwent Open Reduction and Internal Fixation where external facial wounds at chin regions were modified and

extended to get the proper exposure of fracture site. All comminuted bony segments were anatomically reduced and internal fixation was achieved with the application of miniplates to prevent further displacement. Preservation of mental nerves was also achieved on both sides. After 10 days, stitches were removed. There were no signs of non-union or mal-union were found upon close clinical examination. Antibiotic regimen was given to prevent intraoperative and post operative complications. A very satisfactory outcome have been achieved by from both esthetical and functional point of view.

2. Conclusion

Comminuted fracture is one of the most complicated fracture which requires efficient surgical approach in order to restore normal esthetics and functions of mandible. Comminuted mandibular fracture could be treated by various surgical procedure such as closed reduction, external pin fixation, internal wire fixation and open reduction and internal fixation.² Closed reduction have been

* Corresponding author.

E-mail address: mayukhpandit17@gmail.com (M. Pandit).

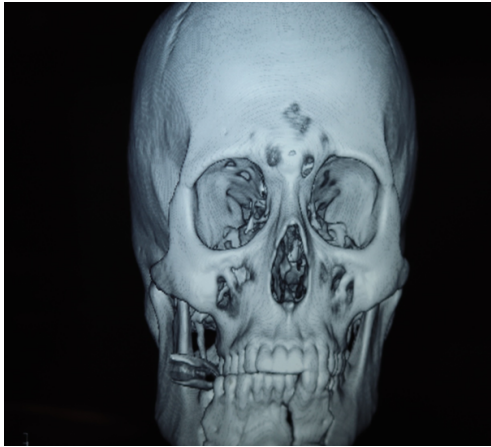

Fig. 1:

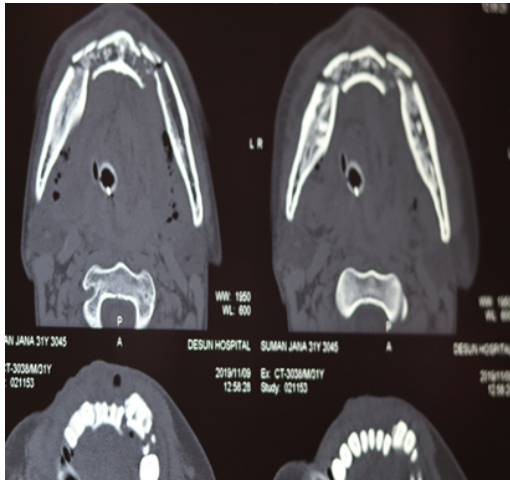


Fig. 2:

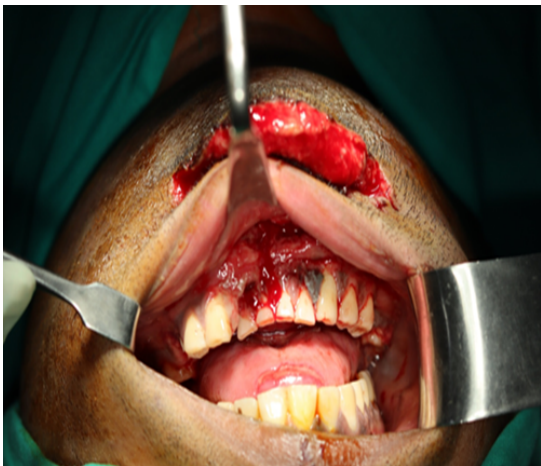

Fig. 3:

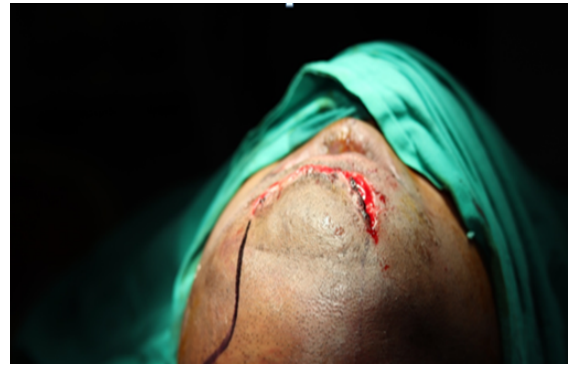

Fig. 4:

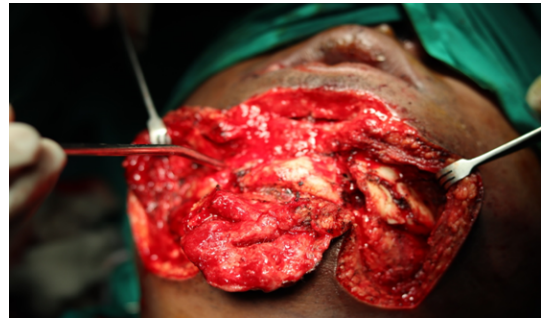


Fig. 5:

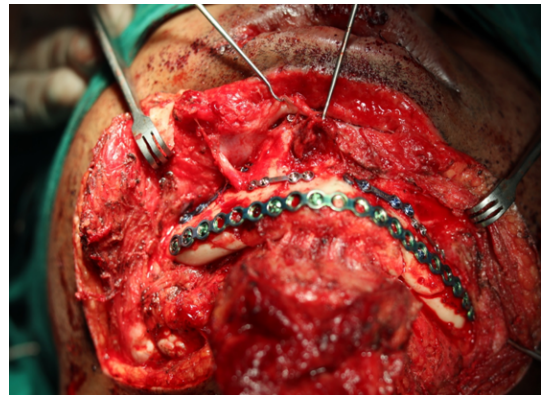


Fig. 6:

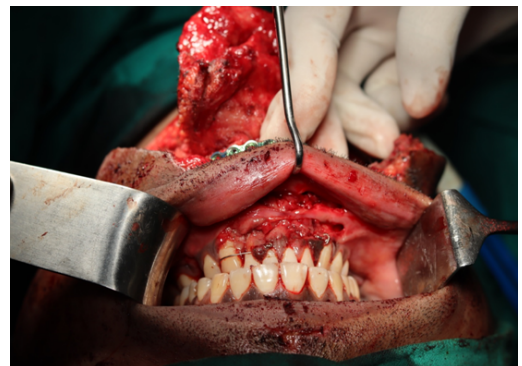

Fig. 7:

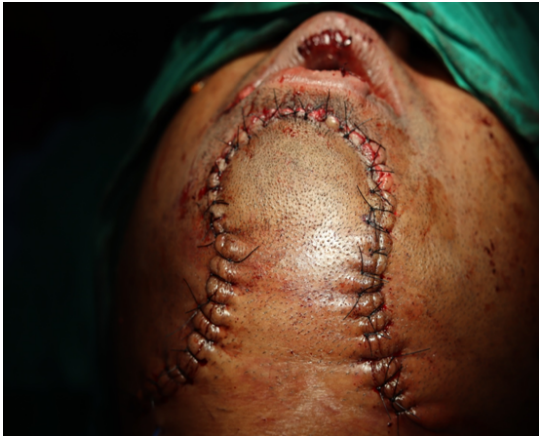

Fig. 8:

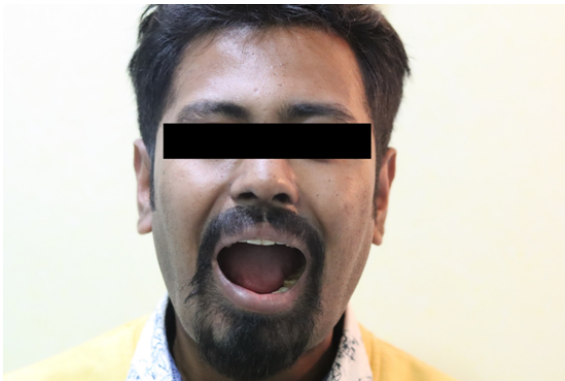

Fig. 9:

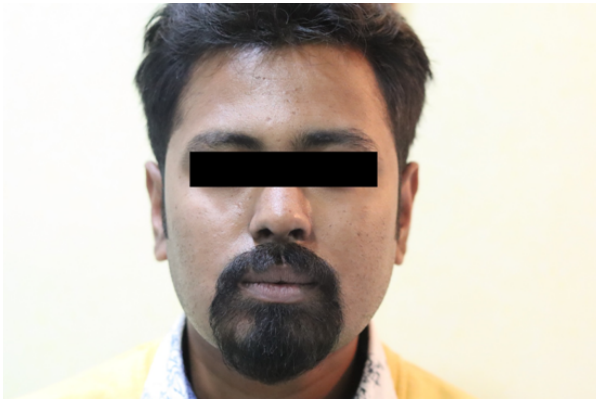

Fig. 10:

considered as the optimal treatment for long period of time

because of its preservance of vascularity to comminuted fracture and prevention of secondary infection.³ In our recent times , it have been widely reported across the world that Open Reduction and Internal Fixation surgery is considered as the treatment of choice for comminuted mandible fracture because of its lower complication rate as well fast rehabilitation of oral functions. So, Open Reduction and Internal Fixation Surgery is the most accepted surgical procedure for the cases of comminuted mandibular fractures in order to reconstruct the mandible therefore preserving the esthetics of mandible and also to rehabilitate the basic functions of mandible with minimal possible complications.

3. Source of Funding

None.

4. Conflict of Interest

None.

References

1. Lee K, Yoon K, Park KS, Cheong J, Shin J, Bae J, et al. Treatment of extensive comminuted mandibular fracture between both mandibular angles with bilateral condylar fractures using a reconstruction plate: a case report. *J Oral Maxillofac Surg.* 1996;40(3):320-7. Available from: <https://www.ncbi.nlm.nih.gov/pmc/articles/PMC4095810/>.
2. Lee K, Yoon K, Park KS, Cheong J, Shin J, Bae J, et al. Treatment of extensive comminuted mandibular fracture between both mandibular angles with bilateral condylar fractures using a reconstruction plate: a case report. *J Korean Assoc Oral Maxillofac Surg.* 2014;40(3):135-9. Available from: <https://www.ncbi.nlm.nih.gov/pmc/articles/PMC4095810/>.
3. Nazimi AJ. Treatment of Extensively Comminuted Mandibular Fracture with the Aid of a Condylar Positioning Device. *Hindawi.* 2017;2017:1-4. Available from: <https://www.hindawi.com/journals/crid/2017/2732907/>.

Author biography

Mayukh Pandit, (Board Certified Researcher in Anatomy)

Arindam Mandal, Maxillofacial and Oral Oncosurgeon

Cite this article: Pandit M, Mandal A. A case report of comminuted mandibular fracture treated successfully with open reduction and internal fixation. *IP J Surg Allied Sci* 2021;3(1):27-29.