



Content available at: <https://www.ipinnovative.com/open-access-journals>

IP International Journal of Ocular Oncology and Oculoplasty

Journal homepage: <https://ijooo.org/>



Guest Editorial

Post exenteration prosthetic rehabilitation in mucormycosis cases: Tips and tricks

Sachin Gupta^{1,*}

¹Managing Director - Arts Eyes, Custom made Artificial Eye Center, Janak Puri, New Delhi, India



ARTICLE INFO

Article history:

Received 23-10-2021

Accepted 24-10-2021

Available online 25-10-2021

This is an Open Access (OA) journal, and articles are distributed under the terms of the [Creative Commons Attribution-NonCommercial-ShareAlike 4.0 License](#), which allows others to remix, tweak, and build upon the work non-commercially, as long as appropriate credit is given and the new creations are licensed under the identical terms.

For reprints contact: reprint@ipinnovative.com

Introduction

Mucormycosis spread rapidly during COVID time. Many patients had to undergo exenteration. This became a sudden shock for the patient and the family to lose a part of the face on sudden onset. It caused a deep psychological and social impact on a patient's life. It is necessary to replace the missing part of the face with prosthetics which can help the patients to heal the psychological impact to some extent.

Question 1: *What is the ideal time for suggesting prosthesis implantation to a patient after orbital exenteration?*

Answer: Orbital prosthesis can be fitted once the wound is completely healed and in case of skin graft when the graft is settled. Usually it takes 6-12 months for complete healing.

Question 2: *What points should be kept in mind by the ophthalmologist while doing a surgery to ensure proper fitting of the prosthesis at a later stage?*

Answer: Good prosthetic outcomes depend on good surgical results however Exenteration is a lifesaving surgery and during the surgery removal of affected tissues is of utmost priority. Below points can make the prosthesis fitting easier and better:

1. Intra Orbital space should be more than 15mm so that prosthesis will fit into the space without a proptose look.
2. Avoid excessive turning of the eyebrow; as it makes it difficult to fit the prosthesis and compromise prosthesis handling by the patient.
3. Complete closure of the defect is preferable for better hygiene and functionality.

Question 3: *What are the different types of prosthesis used in cases of orbital exenteration?*

Answer: Based on material there are two types of Orbital prosthesis.

1. Acrylic Orbital Prosthesis (Usually Spectacle Mounted).
2. Silicone Orbital Prosthesis (available in both spectacle and adhesive mounted).

Based on Retention Method:

1. Adhesive Mounted (used with medical grade adhesive).
2. Spectacle Mounted (Fitted in the spectacle and used with spectacle only).
3. Magnet Mounted (Used when Osteo-integrated implants are placed in the orbital bones with magnetic abutments and magnets are placed behind the orbital prosthesis).

* Corresponding author.

E-mail address: sachin.opt@gmail.com (S. Gupta).

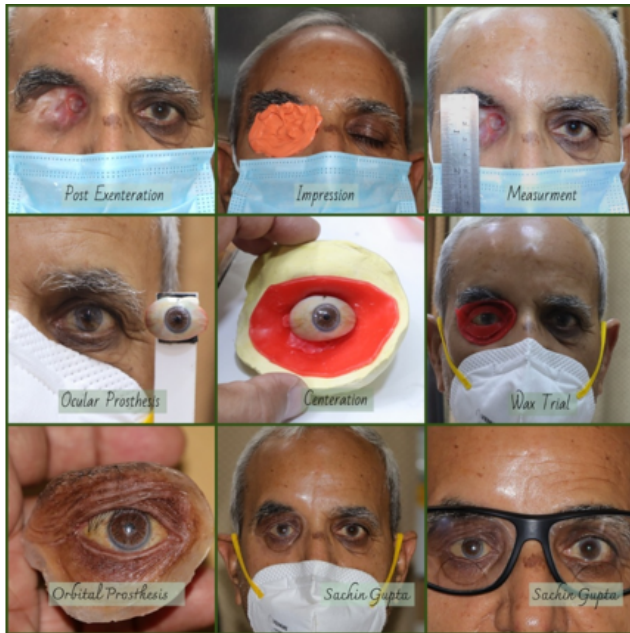

Fig. 1: Steps of making orbital prosthesis.

Question 4: Many patients of mucormycosis had to undergo total or partial maxillectomy along with orbital exenteration which led to absent orbital rim in the inferior quadrant. Does it affect the choice or fitting of the prosthesis? Is facial reconstruction needed in such cases?

Answer: In such cases basically there are two cavities; 1. Oral cavity and 2. Orbital cavity and we have to rehabilitate both the cavities. Generally the Prosthodontists fit the Obturator which is required for functional and aesthetic restoration. Once the Oral cavity is taken care of we can make Orbital prosthesis. In a few cases where the defect size is big and a large size of prosthesis is needed then we prefer to make spectacle mounted prosthesis which also needs adhesive at some points to stick. As retention is an issue here.

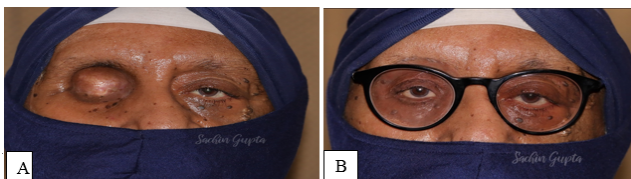


Fig. 2: **A:** Post exenteration photograph of a mucormycosis patient; **B:** Clinical photograph with orbital prosthesis.

Question 5: How can an ophthalmologist ensure proper care of the prosthesis?

Answer: Ophthalmologist/Ocularist should guide the patient about the handling instructions. It is always better to provide the written instruction.

Question 6: How should the patient take care of the prosthesis at home?

Answer:

1. Patients should clean the back surface of the prosthesis with Isopropyl alcohol (70%) every day.
2. Patient should store the prosthesis in a cool and dry place. Keep it out of the reach of children and animals.
3. Orbital prosthesis should be kept in an upside down position.
4. After removal of the prosthesis skin should be cleaned with mild soap and water and moisturizer should be used.
5. The lid of the adhesive bottle should be tightened to prevent the evaporation of adhesive.
6. Smoking should be avoided as it can cause a change in colour.

Question 7: What are the basic steps involved in making a silicone prosthesis?

Answer: The process begins with the detailed counselling about the procedure, its advantages, limitation, handling, care and regime. Once the counselling session is done the first step is taking the impression of the defect. Usually impressions are taken by light body silicone impression material or by dental alginate, which is supported by POP gauge. Once the impression is complete, a positive mold of this impression is made in stone or POP materials. Meanwhile, an ocular piece is prepared according to the fellow eye. With the help of an ocular piece and positive POP mold a wax model of missing part is created which includes eyelids, skin, canthus and skin texture. Once this wax mold replicates the defective part of the face, it is used to make the final dye of the wax model. Now we take medical grade silicone and color it intrinsically to match the patient's skin. This silicone after adding its activator is poured onto the final dye and left for curing procedure. Once the curing of silicone is done, it is tried over the patient's face and if required colors are added over it extrinsically to match the skin texture and shades. After the final fitting and hands on training on insertion and removal, the prosthesis is delivered to the patient.

Conflict of Interest

The author declare that there are no conflicts of interest in this paper.

Cite this article: Gupta S. Post exenteration prosthetic rehabilitation in mucormycosis cases: Tips and tricks. *IP Int J Ocul Oncol Oculoplasty* 2021;7(3):233-235.

Author biography



Sachin Gupta, (Senior Ocularist)
Managing Director - Arts Eyes
(Custom made Artificial Eye Center), Janak Puri,
New Delhi, India