



## Original Research Article

## Fundus changes in patients with chronic renal failure undergoing hemodialysis

Amit H Pathak<sup>1</sup>, Manasi R Ketkar<sup>1,\*</sup>, Ajit K Joshi<sup>1</sup>, Bipin Munjappa<sup>1</sup><sup>1</sup>Dept. of Ophthalmology and Nephrology, Bharati Vidyapeeth Deemed to be University, Medical college and Hospital, Sangli, Maharashtra, India

## ARTICLE INFO

## Article history:

Received 04-01-2020

Accepted 28-01-2020

Available online 24-04-2020

## Keywords:

Diabetes Mellitus

Hypertension

Maculopathy

Retinopathy

Endstage renal disease

Chronic renal

## ABSTRACT

**Introduction:** The assessment of renal vascular pathology requires invasive procedures. The retinal vasculature, conversely, can be observed noninvasively and therefore offers a unique opportunity to explore the association between systemic microvascular diseases and renal function.

**Aims:** The study aims to highlight the importance of ocular screening in patients with chronic renal failure (CRF) on haemodialysis by analysing the fundus changes in these patients.

**Settings and design:** This was a prospective observational study.

**Materials and Methods:** 94 patients with CRF on haemodialysis were evaluated over a period of 6 months. Ocular examination included visual acuity, intraocular pressure measurement, slit lamp examination and fundus examination with indirect ophthalmoscope.

**Results:** 60.64% of 188 eyes had visual acuity < 6/18. The most common causes of visual impairment were maculopathy in 68 eyes. The fundus findings included Hypertensive Retinopathy (HR) which was seen in 32 patients, followed by Diabetic Retinopathy (DR) in 22 patients, mixed retinopathy in 12 patients, Age-related macular degeneration (ARMD) in 9 patients, Retinal Detachment in 2 patients, glaucomatous optic atrophy in 1 patient and Vein Occlusion in 2 patient.

**Conclusion:** The study highlights the importance of detailed ophthalmic examination in patients with CRF on haemodialysis. These patients should be followed up regularly in order to prevent further deterioration of retinal changes and visual loss. Since retinopathy is asymptomatic in its early stages, patients must be made aware of the ocular morbidity associated with CRF.

© 2020 Published by Innovative Publication. This is an open access article under the CC BY-NC-ND license (<https://creativecommons.org/licenses/by/4.0/>)

## 1. Introduction

Chronic renal failure (CRF) is an irreversible and progressive disease process that leads to End Stage Renal Disease (ESRD), in which the patient has to be dependent on renal replacement therapy for survival.<sup>1</sup> The global annual growth of number of ESRD patients is at 7%.<sup>2</sup> The most common cause of CRF is diabetic nephropathy, followed by hypertensive nephroangiosclerosis and various primary and secondary glomerulonephropathies.<sup>3</sup>

The assessment of renal vascular pathology requires invasive procedures. The retinal vasculature, conversely, can be observed noninvasively in humans and therefore offers

a unique opportunity to explore the association between systemic microvascular diseases and renal function.<sup>4</sup> The presence of retinal changes may be a prognostic indicator for renal disease progression.<sup>2,5</sup>

The retina and renal system have a similar developmental, physiological and pathogenic pathway. For example, the retinochoroidal barrier and glomerular filtration barrier are structurally similar.<sup>6</sup> Also, non-anastomotic end arteries, renin-angiotensin-aldosterone system is common to both the systems.<sup>7</sup> The renal epithelial cells (podocytes) and retinal pigment epithelial cells are both dependent on cilia to function.<sup>6</sup> The various mechanisms that contribute to Chronic kidney disease (CKD) are atherosclerosis, vascular remodelling, oxidative stress, endothelial dysfunction and inflammation. These are also implicated in some retinal

\* Corresponding author.

E-mail address: [manasiketkar17@gmail.com](mailto:manasiketkar17@gmail.com) (M. R. Ketkar).

pathologies.<sup>7</sup>

Both the retina and the kidney are low-resistance end organs that are supplied by very small vessels. The small vessels in the retina and the kidney are highly susceptible to fluctuations in BP and blood flow.<sup>5</sup> The pathologic and hemodynamic abnormalities occurring in both retinopathy and nephropathy are thickening of the basement membrane and increased leakage. Thus, retinal abnormalities due to nephropathy may be a useful indicator of cumulative microvascular damage from hypertension, inflammation and diabetes.<sup>8</sup>

Ocular abnormalities in patients with CRF on hemodialysis include intraocular pressure (IOP) changes, corneal and conjunctival abnormalities, cataract, hypertensive retinopathy, diabetic retinopathy, maculopathy, retinal detachment and retinal vein occlusion.<sup>9</sup> Amongst the above abnormalities, retinal pathologies are the ones responsible for sight threatening complications.

With an aim of highlighting the importance of ocular screening in patients with CRF undergoing hemodialysis and scarcity of the data on ocular manifestations in hemodialysis patients, we conducted this study in a teaching hospital.

## 2. Materials and Methods

This was a prospective observational study which included 94 patients with CRF that underwent hemodialysis in the dialysis unit of the Nephrology Department of a teaching hospital from December 2018 to June 2019. The study was approved by the Institutional Ethical Committee. Patients were enrolled in the study only after taking written informed consent.

### 2.1. Inclusion criteria

The patients with ESRD undergoing hemodialysis.

### 2.2. Exclusion criteria

Cases with reversible renal failure and not willing to participate.

A complete ocular examination including visual acuity using Snellen's chart, IOP measurement with Perkin's hand-held tonometer, anterior segment evaluation on slit lamp and detailed fundus examination with indirect ophthalmoscope was done for all patients. Fundus photographs were taken whenever possible. Hypertensive Retinopathy (HR) was graded based on Keith-Wagner-Baker Classification<sup>10</sup> and Diabetic Retinopathy (DR) was classified on the basis of Early Treatment Diabetic Retinopathy Study (ETDRS)<sup>11</sup>

## 3. Results

A total of 188 eyes of 94 patients were studied which included 66 (70.22%) males and 28 (29.78%) females.

**Table 1:** Age distribution

Age	Number of patients	Percentage (%)
0-20	1	4.25
20-40	10	15.95
40-60	50	48.93
>60	33	30.87
Total	94	100

The mean age of the patients in our study was  $55.36 \pm 12.58$  years (range:19-80). The most commonly affected age group in our study was between 40-60 years (53.19%) followed by patients above 60 years of age (35.10%), as shown in Table 1.

**Table 2:** Distribution of patients based on Visual Acuity

WHO Criteria	Visual Acuity	Number of eyes	Percentage (%)
No impairment	6/6 to 6/18	74	39.36
Moderate visual impairment	<6/18 to 6/60	66	35.10
Severe visual impairment	<6/60 to 3/60	38	20.21
Blindness	<3/60 to no PL	10	5.31

### 3.1. Visual Acuity

The best corrected visual acuity (BCVA) was taken for all the patients. The patients were classified according to WHO criteria and 39.36% patients had no visual impairment while 5.31% belonged to the category of blindness. 35.10% of total patients enrolled had vision between <6/18 to 6/60 as elucidated in Table 2.

### 3.2. Cause of CRF

The commonest cause of CRF was diabetes (36.17%), followed by hypertension (31.91%), glomerulonephritis (20.21%), polycystic kidney disease (PCKD) (7.44%), renal calculi (2.13%), amyloidosis and malignancy (1.06% each) (Figure 1)

Out of the 94 patients included in the study, 14 patients had normal fundus findings. The most common cause of visual impairment was maculopathy (68 eyes). 30 eyes had maculopathy due to diabetic retinopathy, 17 eyes showed macular involvement secondary to mixed retinopathy and 13 eyes due to DLDs or ARMD.

(Table 3)

## 4. Discussion

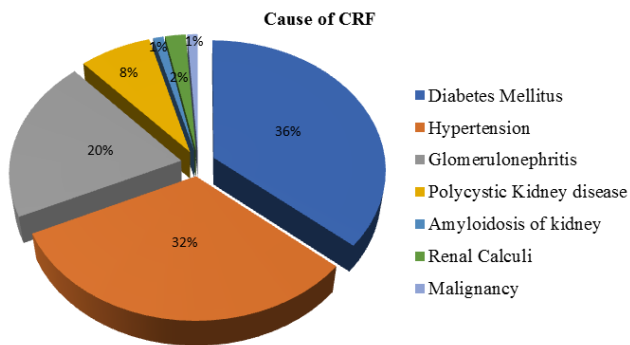
CRF results in progressive deterioration of renal function and is independent of age, gender.<sup>2</sup> Studies have shown that the retinal microvascular parameters are predictive of chronic kidney disease.<sup>12</sup>

**Table 3:** Fundus findings with Maculopathy

S. No	Fundus changes	No of patients (%)	No of eyes with Maculopathy
1	Diabetic Retinopathy (DR)	22 (28%)	
		a) Mild NPDR*	1
		b) Moderate NPDR	12
		c) Severe NPDR	5
		d) PDR <sup>§</sup>	4
2.	Hypertensive Retinopathy (HR)	32 (40%)	
		a) Grade I	6
		b) Grade II	18
		c) Grade III	7
		d) Grade IV	1
3.	Mixed Retinopathy	Diabetic & Hypertensive	12 (15%)
4.	Vein Occlusions		2 (3%)
5.	ARMD/ Drusen-like deposits (DLD)		9 (11%)
6.	Optic Atrophy		1 (1%)
7.	Retinal Detachment	Serous RD	2 (3%)
	Total		80
			68 eyes

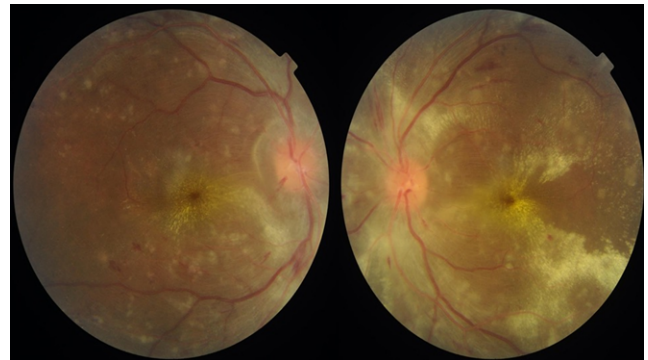
\*Non-Proliferative Diabetic Retinopathy

§Proliferative Diabetic Retinopathy

**Fig. 1:** Causes of CRF

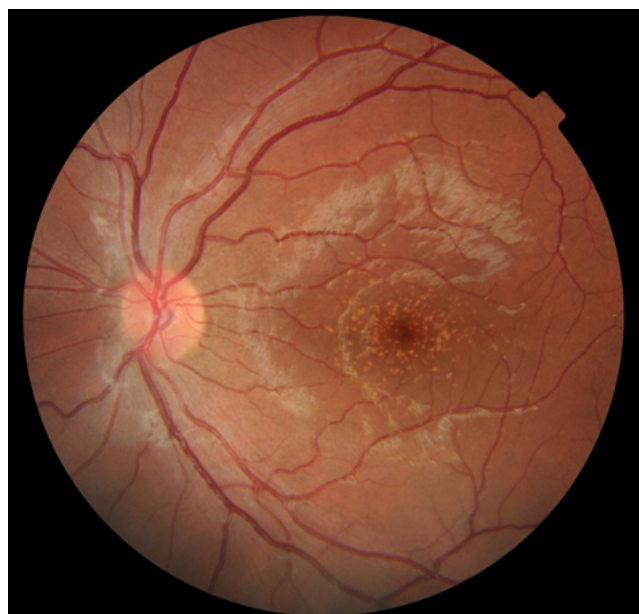In the present study, the most common retinal abnormality was hypertensive retinopathy which was seen in 32 patients (40%). Hypertension (HTN) and CKD have a cause and effect relationship. A degrading kidney function with advanced CKD can lead to increased blood pressure (BP) whereas, sustained elevations in BP can deteriorate the kidney function.<sup>13</sup> Majority of the patients in our study had Grade II hypertensive retinopathy. 1 patient had Grade IV changes bilaterally with presence of papilledema and macular star.(Figure 2)

Out of the 34 diabetic patients, 22 patients had diabetic retinopathy and 12 patients had overlapping features of diabetic with hypertensive retinopathy (mixed retinopathy). Therefore, all the patients with diabetic nephropathy had retinal changes which correlates with the studies by Bajracharya et al,<sup>1</sup> Leys et al,<sup>14</sup> Schleiffer et al.<sup>15</sup> Majority (54.55%) of the patients had moderate NPDR of

**Fig. 2:** Fundus photo of a patient with bilateral Grade IV hypertensive retinopathy

which some patients were newly diagnosed and were not aware of the vision threatening effects of their systemic condition. Of the 4 PDR patients, 2 patients had pan retinal photocoagulation (PRP) marks. A study by Deva et al,<sup>16</sup> has demonstrated that the severity of retinal changes was more in renal failure patients.

19 patients had glomerulonephritis as a cause of CKD. Out of the 19 patients, 7 showed drusen/drusen-like deposits (DLDs) on the macula or peripheral region and 5 patients had microvascular changes of arteriolar attenuation and A-V nicking. However, the patients with DLDs had no significant visual impairment except for those who were associated with atrophic changes. Figure 3 shows a fundus photo of a 23 years old male with CKD with DLDs on the macula in the left eye.



**Fig. 3:** Fundus photo showing DLDs in a patient with CKD.

Glomerulonephritis is associated with electron dense deposits in the lamina densa of glomerular basement membrane. Choroid and kidney are anatomically similar as both have a large capillary bed with fenestrated vessels. Thus, such deposits can also occur at the level of Bruch's membrane.<sup>17</sup> Also, CKD is known to accelerate the progression of atherosclerosis and increase propensity to oxidative stress, both of which are implicated in AMD pathogenesis.<sup>18</sup>

In the present study, 2 patients had CKD due to hypertension and renal malignancy, respectively. Both these patients had vision impairment due to choroidal neovascular membrane (CNVM).

There were 7 patients with polycystic kidney disease (PCKD) in our study; of which 3 had retinal changes. 2 patients had branch retinal vein occlusion and hemi-retinal vein occlusion respectively. While 1 patient had bilateral microvascular changes of arteriolar narrowing and AV nicking. These changes might be secondary to hypertension caused by CKD.

There were 2 patients (2.12%) in our study with serous retinal detachment. The possible mechanism of serous retinal detachment in CKD is focal increase in choriocapillary permeability which causes large molecules like fibrinogen to enter the subretinal space. Also, dialysis can induce fluid shift in sub-retinal space or beneath the pigment epithelium due to altered osmolarity which can be a factor responsible for serous detachment.<sup>19</sup>

1 patient had bilateral glaucomatous optic atrophy and the cause was unrelated to CKD or hemodialysis. During the course of our study, 16 eyes with DME, 2 eyes with maculopathy secondary to vein occlusions, 13 eyes with

maculopathy due to mixed retinopathy and 2 eyes with CNVM were given intravitreal Anti-Vascular Endothelial Growth Factor (Anti-VEGF) injection.

## 5. Limitations

Our study only included patients with ESRD on hemodialysis. CKD patients with mild and moderate grades of CRF were not considered in our study. This was one of the limitations of our study. Secondly, only the retinal changes are taken into consideration while ocular surface abnormalities, cataract, IOP fluctuations, in CRF patients are not included in our study.

## 6. Conclusion

The retinal changes in CRF may be attributed to the underlying etiologies of CRF mainly DM and HTN. However, they are exaggerated by the bleeding tendency due to uraemia.<sup>16</sup> The caliber of retinal vessels is greatly affected in CKD. Renal dysfunction is also associated with alteration of microvascular architecture and is independent of Diabetes.<sup>20</sup>

This study has highlighted the importance of timely screening and regular follow-up in all patients with CRF on hemodialysis. Patients must also be made aware of the ocular morbidity associated with CRF. A multidisciplinary approach should be advocated in management of patients with CKD.

## 7. Source of funding

None.

## 8. Conflict of interest

None.

## References

1. Bajracharya L, Shah DN, Raut KB, Koirala S. Ocular evaluation in patients with chronic renal failure- a hospital based study. *Nepal Med College J.* 2008;10(4):209–214.
2. S BMM, S MHKM, Velampalli S. A Clinical Study of Retinal Changes in Chronic Renal Failure Patients. *IOSR J Dent Med Sci.* 2017;16(04):31–34.
3. Vrabec C, Vatauvuk Z, Pavlovic D, Sesar A, Cala S, et al. Ocular Findings in Patients with Chronic Renal Failure undergoing Hemodialysis. *Coll Antropol.* 2005;1:95–98.
4. Grunwald J, Alexander J, Maguire M. Prevalence of ocular fundus pathology in patients with chronic kidney disease. *Clin J Am Soc Nephrol.* 2010;5:867–873.
5. Lee WJ, Sobrin L, Kang MH, Seong M, Kim YJ, et al. Ischemic diabetic retinopathy as a possible prognostic factor for chronic kidney disease progression. *Eye.* 2014;28:1119–1125.
6. Savage J, Ratnaik S, Colville D. Retinal Abnormalities Characteristic of Inherited Renal Disease. *J Am Soc Nephrol.* 2011;22(8):1403–1415.
7. Wong CW, Wong TY, Cheng CY, Sabanayagam C. Kidney and eye diseases: Common risk factors, etiological mechanisms, and pathways. *Kidney Int.* 2013;p. 1290–1302.

8. Grunwald J, Alexander J, Ying GS. Retinopathy and Chronic Kidney Disease in the Chronic Renal Insufficiency Cohort Study (CRIC). *Arch Ophthalmol*. 2012;130(9):1136–1144.
9. Fesharaki S, Kianersi F, Taheri S, Fesharaki H, Mirmohammadkhani M, et al. Ocular manifestations in hemodialysis patients: Importance of ophthalmic examination in prevention of ocular sequels. *Int J Prevent Med*. 2019;10(1):20.
10. Grosso A, Veglio F, Grignolo FM, Wong TY. Hypertensive retinopathy revised: Some answers, more questions. *Br J Ophthalmol*. 2005;89:1646–1654.
11. Grading diabetic retinopathy from stereoscopic color fundus photographs—an extension of the modified Airlie House classification: ETDRS report number 10. *Ophthalmol*. 1991;98:786–806.
12. Lim LS, Lui Cheung CY, Sabanayagam C, Lim SC, Tai ES, et al. Structural Changes in the Retinal Microvasculature and Renal Function. *Invest Ophthalmol Visual Sci*. 2013;54(4):2970–2976.
13. Judd E, Calhoun DA. Management of Hypertension in CKD: Beyond the Guidelines. *Adv Chronic Kidney Dis*. 2015;22(2):116–122.
14. Leys AM. Eye Fundus of the diabetic patient with nephropathy and hypertensive retinopathy, Macroangiopathic complication. *Bull Soc Belge Ophthalmol*. 1995;256:49–59.
15. Schleiffer T, Hölken H, Brass H. Morbidity in 565 Type 2 Diabetic Patients According to Stage of Nephropathy. *J Diabetes Complicati*. 1998;12(2):103–109.
16. Deva R, Alias MA, Colville D, Tow FKNFH, Ooi QL, et al. Vision threatening retinal abnormalities in chronic kidney disease stage 3 to 5. *Clin J Am Nephrol*. 2011;6:1866–1871.
17. McAvoy CE, Silvestri G. Retinal changes associated with type 2 glomerulonephritis. *Eye*. 2005;19(9):985–989.
18. Liew G, Mitchell, Wong TY, Iyengar SK, Wang JJ. CKD increases the risk of ARMD. *J Am Soc Nephrol*. 2008;19(4):806–811.
19. Chang YS, Weng SF, Chang C. Risk of serous retinal detachment in patients with end stage renal disease on dialysis. *PLOS ONE*. 2017;12(6):1–11.
20. Toyoda K. Cerebral small vessel disease and chronic kidney disease. *J Stroke*. 2015;17(1):31–37.

## Author biography

**Amit H Pathak** Assistant Professor

**Manasi R Ketkar** Junior Resident

**Ajit K Joshi** Professor and HOD

**Bipin Munjappa** Professor

**Cite this article:** Pathak AH, Ketkar MR, Joshi AK, Munjappa B. Fundus changes in patients with chronic renal failure undergoing hemodialysis. *IP Int J Ocul Oncol Oculoplasty* 2020;6(1):67-71.