



Original Research Article

A study of epidermal and dermal tumors over face in ageing skin

Gnanasekaran R¹, Rajagopal R², Radhakrishnan S³, Narmadhadevi TG^{1,*},
Premananth P⁴, Shanmugapriya K¹

¹Dept. of Dermatology, Venereology & Leprology, Velammal Medical College and Research Institute, Madurai, Tamil Nadu, India

²Consultant Dermatologist, Bengaluru, Karnataka, India

³Dept. of Dermatology, Venereology & Leprology, Aemed Forces Medical College, Pune, Maharashtra, India

⁴Dept. of Dermatology, Respiratory Medicine, Velammal Medical College and Research Institute., Madurai, Tamil Nadu, India



ARTICLE INFO

Article history:

Received 15-01-2020

Accepted 21-01-2020

Available online 21-04-2020

Keywords:

Epidermal tumors

Dermal tumors

Ageing skin

ABSTRACT

Introduction: Ageing is a complex process that has been defined as the accumulation of molecular damage over time. signs of ageing skin are atrophy, laxity, wrinkling, sagging, dryness, yellowness, a multiplicity of pigmented and other blemishes and sparse grey hair. More than 90% of age-associated cosmetic problems are caused by ultraviolet (UV) radiation on exposed skin, which damages telomeres, generates free-radicals and whose effects are largely proportionate to skin type. Skin tumours develop as a result of proliferation of a single or multiple components of the skin. Skin tumours are a challenging group of conditions that can be categorized into epidermal and dermal tumors depends on their origin. skin tumours in ageing skin are challenging because of wide variations in clinical presentations, the occurrence, behaviour and variety of the epidermal and dermal tumours makes it worthwhile to study this topic.

Aim: The aim of this study was to study the clinical features and epidemiology of epidermal and dermal tumours of skin over face in ageing.

Materials and Methods: fifty patients with Epidermal and Dermal skin tumors over face in ageing skin attending the opd of department of dermatology.

Results: The highest age prevalance was in 5th decade (50%), The female: male ratio was 1.2: 1. The commonest skin tumours recorded were epidermal tumours (74%), followed by dermal tumors (26%). Commonest among Epidermal tumours were seborrheic keratosis – 28 cases (75.07%), were firm in consistency in 30 cases (81.08%), cystic in 04 cases (10.81), soft in 03 cases (8.1 %). Among Commonest among dermal tumors were compound nevus – 5 cases (38.46%), Among dermal tumors, 06 cases were biopsied. clinical diagnosis concordance with histopathological diagnosis was seen in 04 cases (66.66%). Discordance seen in 02 cases (33.33%), clinically suspected as sebaceoma and dermal nevus turned out to be dermal nevus and dermatofibroma histopathologically.

© 2020 Published by Innovative Publication. This is an open access article under the CC BY-NC-ND license (<https://creativecommons.org/licenses/by/4.0/>)

1. Source of Data

50 patients of Epidermal and Dermal skin tumors of both sexes over face with age more than 50 years. Attending the department of Dermatology

1.1. Exclusion criteria

cutaneous infections like warts, erysipelas. Skin lesions other than tumors. 4. Melanocytic nevus those not fulfilling tumor criteria (>5mm in size) i.e flat lesions like junctional nevus, dysplastic nevus and small lesions like DPN.

1.2. Method of collection of data

Informed consent was taken from all the patients included in the study.

* Corresponding author.

E-mail address: gnanagnani123@gmail.com (Narmadhadevi TG).

All patients in our study undergone a detailed history taking, general physical, systemic and dermatological examination and a set of routine investigations. Skin biopsy routinely not done for all patients as the lesions were present over the face and patients were not willing due to cosmetic concerns.

However 15 cases were subjected to skin biopsy when there was a diagnostic dilemmas and patients who were willing. For smaller lesions, excisional biopsy and for larger lesions incisional biopsy was done Special stains like mason fontana for melanin were used whenever diagnostic dilemma in histopathology.

Clinical photographs were taken in all cases of facial tumors. Patient was referred to oncosurgeon in case of suspected malignant epidermal, dermal tumors for biopsy and further necessary management.

1.3. Evaluation

For the study, a proforma was prepared to record the relevant details of the patient like age, sex, occupation, socioeconomic status, number of lesions, site, symptoms, and clinical examinations which include presenting lesion, consistency etc. In clinically doubtful cases and those willing for biopsy skin biopsy was done. Results were correlated for concordance and discordance.

Records were maintained and data analyzed, variables was tested using appropriate statistical tool (SPSS Software version 16).

2. Results

The highest age prevalence was in the age group of 51 – 60 years, 25 cases (50%), followed by 61-70 years 13 cases (26 %) and 71-80 years 10 cases (20 %), 81- 90 years 02 cases (4 %), The least prevalence was observed in 81-90 years.

Among males, maximum numbers of cases were in the age group of 51-60 years, 9 cases (18%) and least was in the age group of 81-90 years 02 cases (4%), whereas in females, commonest was in the age group of 51-60 years, 16 cases (32 %) and least was in the age group of 71-80 years, 04 cases (8 %). Out of 50 cases, 28 were females and 22 were males.

The female: male ratio being 1.27: 1. Patients from Urban area (76%) outnumbered those from rural areas (24%). Most frequently affected individuals are housewives (54%) followed by clerks (16%), business and agriculturists (12% each), Labourer, supervisor and ann (2% each). Out of 50 patients studied 04 patients belongs to lower class (8%), 42 patients belongs to middle class (84%) and 04 patients belongs to upper class (8%). Most common skin tumors were epidermal tumors (74%) followed by dermal tumors (36%). Commonest among Epidermal tumours were seborrheic keratosis – 28 cases (75.07%), (observed p value $-0.014 < 0.05$) followed by epidermoid cyst 4 cases (10.81%), acrochordons 3 cases (8.1) and keratoacanthoma

, basal cell carcinoma 1 case each (2.75%). The commonest tumours in this study among dermal tumors were compound nevus – 5 cases (38.46%), (observed p value $-0.09 < 0.05$) followed by syringoma and sebaceous hyperplasia 3 cases each (23.07%), and Dermal nevus, Dermatofibroma 01 case each (7.6 %). Tables 1 and 4.

It is observed from the above table, the calculated p-value (.009) is lesser than the level of significance i.e. 0.05. ($p < 0.05$) So, we reject the null hypothesis and concluded that there is association between most common dermal tumors and compound nevus.

Most of the patients with epidermal tumors suffered for years (86.48%), compared to those with months (13.5%), most commonly seborrheic keratosis presented for years (observed p value $0.01 < 0.05$). Among dermal tumors most patients suffered for years (46.15%), compared to those with months (30.76%) at birth (23.07%). Majority of the epidermal tumors presented with multiple lesions 22 cases (59.45%) and 15 cases with single lesions (40.54%). majority of the dermal tumors presented with multiple lesions 9 cases (69.23%) and 4 cases with single lesions (30.76%).

Commonest presenting symptoms among epidermal tumours was itching (8.1%), pain (2.7 %), bleeding (2.7 %) most of the patients among dermal tumours were asymptomatic (100%). Commonest site in face among epidermal tumors were cheeks (67.56%), followed by forehead (16.21%) eyelids (8.1), chin (5.4%) and nose (2.7%). Table 9 B shows, that among dermal tumors commonest site in face is cheeks (46.15%), followed by eyelids (23.07%), by forehead (15.38%), chin (15.38%) Table 5 A & B.

2.1. Morphology

Commonest presenting lesions among epidermal tumors were papule (56.7 %), followed by plaque (32.43%), nodule (10.8%). Commonest presenting lesions among dermal tumors were nodule (53.84 %), followed by papule (46.15%).

Among epidermal tumors majority of the lesions were firm in consistency (81.08%), soft (10.81%) and cystic (8.1%). Among dermal tumors all the lesions presented with firm consistency (100%). Among epidermal tumors, 09 cases were biopsied. clinical diagnosis concordance with histopathological diagnosis was seen in 08 cases (88%). Discordance seen in 01 case (12%), clinically confirmed as melanocytic nevus turned out to be dysplastic nevus histopathologically.

Table 1: Prevalance of various types of epidermal skin tumours

Group	Type of epidermal tumour	No. of cases	Percentage (% in epidermal tumours)	Percentage (% of total tumours)
I	Benign keratinocyte tumours	36	97.29	72
	A) Seborrhoeic keratosis	28	75.07	56
	B) Keratoacanthoma	1	2.7	2
	C) Acrochordons	3	8.1	6
	D) Epidermoid cyst	4	10.81	8
II	Malignant epidermal tumours	1	2.7	2
	A) Basal cell carcinoma	1	2.7	2
	Total	37	100	74

Table 2: Prevalance of seborrhoeic keratosis in epidermaltumors - statistics Chisquare

0: There is no association between most common epidermal tumors and seborrhoeic keratosis

H1: There is association between most common epidermal tumors and seborrhoeic keratosis

Case Processing Summary

	N		N	Percent		
epidermaltumours	37	97.4%	1	2.6%	38	100.0%
*seborrhoeic keratosis						

Epidermaltumours * Seborrhoeic Keratosis Crosstabulation

				No	Total
epidermaltumours	benign		28	8	36
		% within epidermaltumours	77.8%	22.2%	100.0%
		% within seborrhoeic	100.0%	88.9%	97.3%
		% of Total	75.7%	21.6%	97.3%
	Malignant		0	1	1
		% within epidermaltumours	0.0%	100.0%	100.0%
		% within seborrhoeic	0.0%	11.1%	2.7%
		% of Total	0.0%	2.7%	2.7%
	Total		28	9	37
		% within epidermaltumours	75.7%	24.3%	100.0%
		% within seborrhoeic	100.0%	100.0%	100.0%
		% of Total	75.7%	24.3%	100.0%

-Square Tests

Chi-Square	9.198a	1	. Sig. (2-sided)	.014
------------	--------	---	------------------	------

. 2 cells (50.0%) have expected count less than 5. The minimum expected count is .24.

b. Computed only for a 2x2 table

It is observed from the above table, the calculated p-value (.014) is lesser than the level of significance i.e. 0.05. (p < 0.05). So, we reject the null hypothesis and concluded that there is association between most common epidermal tumors and seborrhoeic keratosis.

Among dermal tumors, 06 cases were biopsied. clinical diagnosis concordance with histopathological diagnosis was seen in 04 cases (66.66%). Discordance seen in 02 cases (33.33%), clinically suspected as Fibrous papule of faces turned out to be dermal nevus and dermatofibroma histopathologically. Table 6 A ,B

2.2. Associated Diseases

Most patients did not have any associated conditions 34 cases (68%), associated conditions seen were diabetes mellitus in 07 cases (14%) and hypertension 9 cases (18 %).

2.3. Clinical and histopathological

Epidermal Tumors

Table 3: Prevalance of Seborrhoeic Keratosis In Epidermal Tumors - Statistics

:

H0: There is no association between most common dermal tumors and compound nevus

H1: There is association between most common dermal tumors and compound nevus

Case Processing Summary

* compoundnevus	13	100.0%	0	0.0%	13	100.0%
* compoundnevus Crosstabulation						
						Total
				5	1	6
	acquired	% within Dermal tumors		83.3%	16.7%	100.0%
		% within compoundnevus		100.0%	12.5%	46.2%
		% of Total		38.5%	7.7%	46.2%
			0	6	6	
Dermal tumors	appendageal	% within Dermal tumors		0.0%	100.0%	100.0%
		% within compoundnevus		0.0%	75.0%	46.2%
		% of Total		0.0%	46.2%	46.2%
			0	1	1	
	soft tissue	% within Dermal tumors		0.0%	100.0%	100.0%
		% within compoundnevus		0.0%	12.5%	7.7%
		% of Total		0.0%	7.7%	7.7%
			5	8	13	
Total		% within Dermal tumors		38.5%	61.5%	100.0%
		% within compoundnevus		100.0%	100.0%	100.0%
		% of Total		38.5%	61.5%	100.0%
-Square Tests						
Chi-Square	9.479a		2		.009	

. Sig. (2-sided)

a. 6 cells (100.0%) have expected count less than 5. The minimum expected count is .38.

Table 4: Prevalance of various types of dermal skin tumours

Type of dermal tumours	No. of cases	Percentage (% in dermal tumours)	Percentage (% of total tumours)
Acquired melanocytic nevi	6	46.1	12
A) Compound nevus	5	38.46	10
B) Dermal nevus	1	7.6	2
Appendageal tumours	6	46.1	12
A) Sebaceous hyperplasia	3	23.07	6
B) Syringoma	3	23.07	6
Soft tissue tumours	1	7.6	2
A) Dermatofibroma	1	7.6	2
Total	13	100	26

Table 5: A. Site And Distribution Of Lesions Of Epidermal Tumors

Type of tumours	Site	Forehead				Chin
Epidermal Tumours) Seborrhoeic keratoses	6	2	1	17	2
) Keratoacanthoma	0	0	0	1	0
) Acrochordons	0	1	0	2	0
) Epidermoid cyst	0	0	0	4	0
) Basal cell carcinoma	0	0	0	1	0
/ Percentage		6 / 16.21	2 / 5.4	1 / 2.7	25 / 67.56	2 / 5.4 B :
Site and distribution of lesions of dermal tumors						
Type of Tumours						
Dermal Tumours) Compound nevus	1	0	0	2	2
) Dermal nevus	0	0	0	1	0
) Sebaceous hyperplasia	1	0	0	2	0
) Syringoma	0	3	0	0	0
) Dermato fibroma	0	0	0	1	0
/ Percentage		2 / 15.38	3 / 23.07	0	6 / 46.15	2 / 15.38

Table 6: Clinico Path Correlation Of Epidermal Tumors

Type of tumours		diagnosis	diagnosis		Discordance
Epidermal Tumours) Seborrhoeic keratoses	28	6	6	0
) Keratoacanthoma	1	0	0	0
) Acrochordons	3	0	0	0
) Epidermoid cyst	4	2	2	0
) Basal cell carcinoma	1	1	1	0
		37	9	9	0
: Clinico Pathological Correlation Of Dermal Tumors					
of Tumours		Diagnosis	Diagnosis		
Dermal Tumours) Compound nevus	5	3	3	0
) Dermal nevus	1	1	0	1
) Sebaceous hyperplasia	3	0	0	0
) Syringoma	3	1	1	0
) Dermato fibroma	1	1	0	1
Total		13	6	4	2

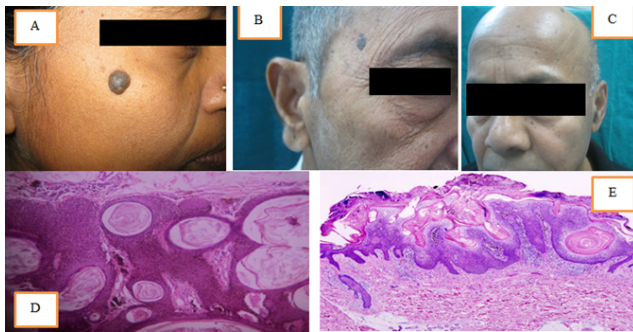


Fig. 1: A ,B,C: Seborrheic Keratosis, (D) - histopathology of pigmented seborrheic keratosis 10 X, (E) histopath of hyperkeratotic seborrheic keratosis Thin interwoven cords of basaloid cells show cytoplasmic melanin pigmentation Horn cysts are also present.

Seborrheic keratosis of hyperkeratotic type with marked papillomatosis and hyperkeratosis. (10 x ,H & E)

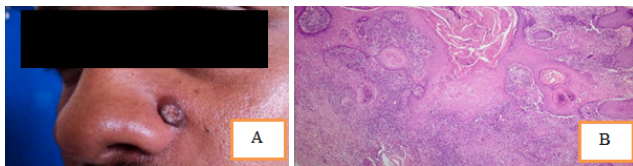


Fig. 2: A: Keratoacanthoma, (B) Histopathology of keratoacanthoma (10 X)

There is a large, central keratin-filled crater. Epidermis extends like a buttress over the side of the crater Irregular epidermal proliferations extend downward from the base of the crater into the dermis

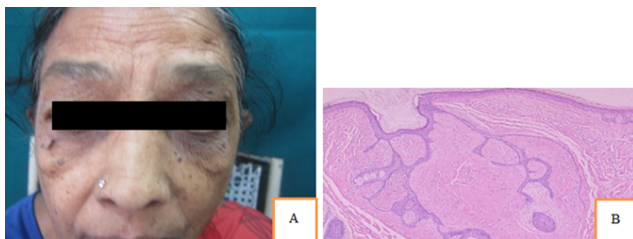


Fig. 3: A acrochordons. (B) Histopathology of acrochordons 10 X

Epidermal hyperplasia with stroma composed of loosely arranged collagen

Epidermal cysts are lined by stratified Squamous epithelium inflammatory cell infiltrate in the adjacent dermis,

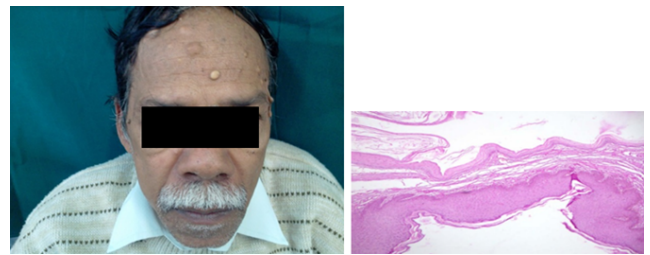

Fig. 4: A Epidermoid Cyst, (B) Histopathology -Epidermoidcyst

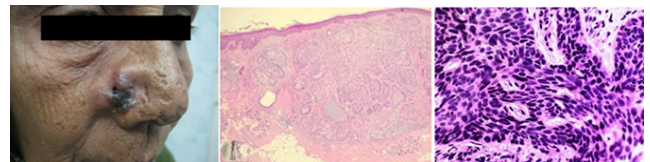


Fig. 5: A Basal Cell Carcinoma - Noduloulcerative Type, FIG 5 B Basal Cell Carcinoma (10X) Islands of basaloid cells with peripheral palisading, BASAL CELL CARCINOMA (40 X) solid type. High magnification. The basaloid tumor cellsflow through the dermis with a variable degree of peripheral palisading.

2.4. Dermal Tumors

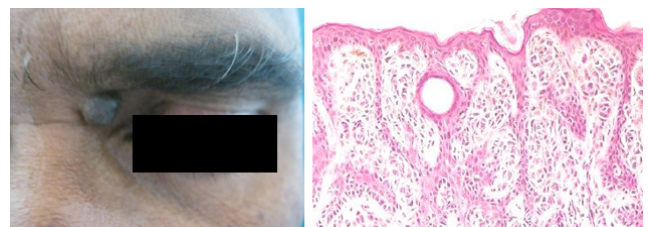


Fig. 6: A Compound Nevi, FIG 6B Compound nevus (H & E 100 X) Both junctional and dermal nests of nevus cells.

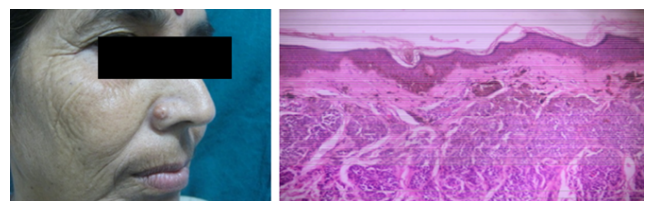


Fig. 7: 7A Dermal Naevus, B Histopathology of intradermal nevi10 X) nevus cells arranged in nests in dermis.

The epidermis overlying the dermal tumor is acanthotic and papillomatous with a central 'dell'.



Fig. 8: A&B – Syringoma, C Histopathology of Syringoma 10 X
In the dermis,numerous tubular structures are embedded in a dense, collagenous stroma.

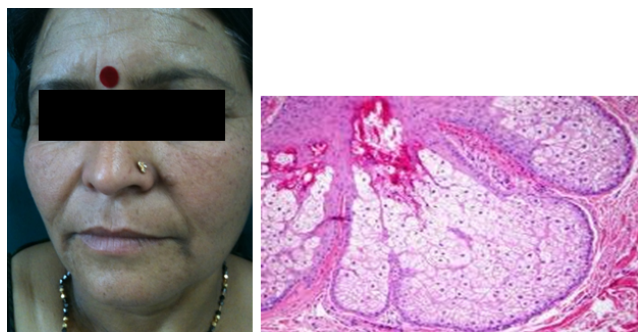


Fig. 9: A Sebaceous Hyperplasia, B Histopathology of sebaceous hyperplasia (100 X) Large sebaceous lobules with a rim of basaloid cells at the periphery and mature sebocytes in the center are part of the enlarged sebaceous gland

3. Discussion

3.1. Age

In the present study more number of patients, belonged to the age group of 51 – 60 years, 25 cases (50%), followed by 61-70 years 13 cases (26 %) and 71-80 years 10 cases (20 %), 81- 90 years 02 cases (4 %) . The least prevalence was observed in 81-90 years.

3.2. Sex

Among males, maximum numbers of cases were in the age group of 51-60 years, 9 cases (18%) and least was in the age group of 81-90 years 02 cases (4%), whereas in females, commonest were in the age group of 51-60 years, 16 cases (32 %) and least was in the age group of 71-80 years, 04 cases (8 %). Out of 50 cases, 28 were females and 22 were males.

The female: male ratio being 1.27: 1. In the present study 38 patients (76 %) belonged to urban area and only 12 patients (24%) belong to rural area. Though lot of people attend our hospital from rural areas the lower prevalence among them reflects their ignorance regarding the cosmetic orientation and also due to the asymptomatic nature of the lesions

In the present study among the occupational group, housewives constituted the majority (54%), followed by clerks (16 %), Business and agriculture (12% each), not

applicable in (2%), labourer (2%), supervisor and nurse (2% each). This reflects the degree of cosmetic orientation in these various occupational groups. In the present study 42 patients (84%) belonged to the middle socio-economic status whereas 04 patients each (08%) belonged to the upper and lower socioeconomic status. This is in concurrence with the observation that the majority of the patients attending our hospital belonged to middle socio-economic status. The lower prevalence among higher and lower socioeconomic status can be attributed to the fact that these patients as they are capable of attending private consultants remain out of record and thus add to a probable low prevalence.

3.3. Prevalance

In the present most common skin tumors were epidermal tumors (74%) followed by dermal tumors (26%). Table 5. Commonest among Epidermal tumours were seborrheic keratosis – 28 cases (75.07%) (p value = 0.014 , <0.05) , followed by epidermoid cyst 4 cases (10.81%), and acrochordons 3 cases (8.1%), keratoacanthoma & basal cell carcinoma 1 case each (2.7%).

The commonest tumours in this study among dermal tumors were compound nevus – 5 cases (38.46%), (p value = 0.09 , < 0.05) followed by syringoma and sebaceous hyperplasia 3 cases each (23.07%) , dermal nevus, and dermatofibroma 01 case each (7.6%). Table-1&4 / 2&3 chi square charts

3.4. Duration

Most of the patients with epidermal tumors suffered for years (86.48%), compared to those with months (13.5%) . In epidermal tumors SK most commonly presented for years (p value = 0.02 , < 0.05) Among dermal tumors most patients suffered for years (46.15%), compared to those with months (30.76%) at birth (23.07%) . In dermal tumors, compound nevus most commonly presented for years (p value = 0.01 , < 0.05)

3.5. Number of lesions

Majority of the epidermal tumors presented with multiple lesions 22 cases (59.45%) and 15 cases with single lesions (40.55%). Majority of the dermal tumors presented with multiple lesions 9 cases (69.23%) and 4 cases with single lesions (30.76%) .

3.6. Symptoms

Commonest presenting symptoms among epidermal tumours was itching in 3 cases (8.1%), pain in 1 case (2.7 %), bleeding in 1 case (2.7 %). All the patients with dermal

tumours were asymptomatic (100%).

3.7. Site and distribution of lesions over face

Commonest site in face among epidermal tumors were cheeks in 25 cases (67.56%), followed by forehead in 06 cases (16.21%) eyelids & chin in 02 cases each (5.4%), and nose in 1 case (2.7%). Among dermal tumors commonest site in face is cheeks in 06 cases (46.15%), followed by eyelids 03 cases (23.07%), forehead and chin in 02 cases each (15.38%), Table 5 A,B.

3.8. Morphology

Commonest presenting lesions among epidermal tumors were papules in 21 cases (56.7%), followed by plaques in 12 cases (32.4%), nodule in 04 cases (10.8%). Commonest presenting lesions among dermal tumors were nodule in 7 cases (53.84%), followed by papules in 06 cases (46.15%).

3.9. Consistency of lesions

Among epidermal tumors majority of the lesions were firm in consistency in 30 cases (81.08%), cystic in 04 cases (10.81%), soft in 03 cases (8.1%). Among dermal tumors all the lesions were firm in consistency (100%).

3.10. Clinico pathological correlation

Among epidermal tumors, 09 cases were biopsied. clinical diagnosis concordance with histopathological diagnosis was seen in 09 cases (100%). No discordance seen.

Among dermal tumors, 06 cases were biopsied. clinical diagnosis concordance with histopathological diagnosis was seen in 04 cases (66.66%). Discordance seen in 02 cases (33.33%), clinically suspected as sebaceoma and dermal nevus turned out to be dermal nevus and dermatofibroma histopathologically. Table 6 A ,B.

3.11. Associated diseases

Most patients did not have any associated conditions 34 cases (68%), associated conditions seen were diabetes mellitus in 07 cases (14%) and hypertension 9 cases (18%).

3.12. Discussion of individual tumours

3.13. Benign tumours of epidermis

3.14. Seborrheic keratosis

In the present study, most common among epidermal tumors were seborrheic keratosis seen in 28 patients (56%) (pvalue

0.014 < 0.05) out of which there were 15 females and 13 males. The female male ratio was 1.15:1. According to Quinn et al,¹ the males and females are equally affected. The highest age of onset was 87 years and least being 51 years. With mean age of onset was 67.42 years. This correlates well with statement by Jain et al⁸ that, seborrheic keratosis is common in the middle aged and elderly person.

Most commonly seborrheic keratosis presented for years. (pvalue 0.02 < 0.05). In our study, 25 patients were asymptomatic (pvalue 0.01 < 0.05), while 3 patients had itching, lesions were located over cheek in each of the patients, they were diagnosed as inflamed seborrheic keratosis.

Most commonly it presented as papules in 17 patients. The commonest site found was on the cheek (pvalue 0.02 < 0.05) and forehead. Other sites were chin. observations in the present study are almost identical to the observations mentioned in the literature.¹⁻³

In our study, only 6 patients were biopsied, and the remaining 22 patients did not agree for biopsy as the lesions were located over cosmetically concerned areas. Out of 6 patients, three showed features of irritated type, two showed features of hyperkeratotic type, and other one showed features of pigmented type. Observations in the present study are almost identical to the observations mentioned in the literature.^{1,4}

3.15. Epidermal cyst (Epidermoid cyst)

In the present study, there were 4 cases of epidermal cysts (8%), 2 male and 2 females. According to Quinn et al,⁵ it is commonly seen in young and middle aged adults. In this study the mean age of onset was 55.33 years. According to Kirkham,² the commonest site of involvement is face, scalp, neck and trunk but in our study all lesions were seen over the face.

In our study, only 1 patient was biopsied and the remaining 3 patients did not agree for biopsy. one patient showed features of typical histopathological features which were consistent with the findings of Quinn et al¹ Kirkham.²

3.16. Acrochordons

In the present study, acrochordons were seen in 03 patients (6%). of which 2 were males and 1 were females. According to Quinn et al,⁵ females were more commonly affected than males. The mean age of onset was 63.63 years, which is similar to the study by Zaher et al.⁶ Majority of lesions were multiple, small pedunculated papules (9%) located over periorbital, cheek.

According to Kumar et al,⁷ acrochordons are associated with diabetes mellitus, obesity, hyperlipidemia, acromegaly

and intestinal polyps, however in our study diabetes mellitus and hypertension was not associated with acrochordon. The observations made in the present study with regard to the clinical features of lesions are not in concurrence with the observations made in other studies.^{1,7}

3.17. Benign Tumours of Melanocyte

3.18. Compound nevus

In the present study, most common among dermal tumors were compound nevi seen in 5 patients (10 %) (pvalue 0.009 < 0.05), 3 females and 02 males they belonged to 50-70 years of age group. Most commonly presented as single lesions observed in 3 patients (p value 0.05 = 0.05) and asymptomatic in all 05 patients (pvalue 0.009 < 0.05). All the lesions were located over the face. Observations in the present study are almost identical to the observations mentioned in the literature.^{8,9} In our study, two patients were biopsied and the others did not agree for biopsy as the lesion was located over cosmetically concerned area. Histopathological features showed junctional activity of nevus cells and superficial dermis was composed predominantly of type a nevus cells arranged in nests. The observations in the present study are in concurrence with the observation mentioned in the literature.⁸⁻¹⁰

3.19. Intradermal nevi

In the present study, intradermal nevi were seen in 1 female patient. The lesions were single and situated over the cheek. In our study, initially thought of sebaceoma clinically but confirmed as dermal nevus with typical histopathological features of intradermal nevus which were consistent with the findings of Elder¹⁰, Newton Bishop⁸ Katarkar.¹¹

3.20. Appendageal tumours

In the present study, appendageal tumours were seen in 5 patients (10%). Out of which three patients had syringoma (6%) and two patients had sebaceous hyperplasia (4%). In our study, 2 male and 1 female patient (6%) had syringoma of onset 50-60 years of age concordant with study by Ramaswamy et al,¹² which showed that it was common in middle aged males. All cases presented with multiple lesions (p value 0.01 < 0.05) were seen around the eyelids (p value 0.01 < 0.05). According to Calonje,¹³ commonest site involved is head and neck, rarely over trunk and extremities. Histopathological findings were typical as described by Ramaswamy et al¹² Calonje¹⁶ Ahmed.¹⁷ In the present study, 01 male and 02 female patients (4%) had sebaceous hyperplasia. The lesions were multiple, yellow to skin coloured papules and nodules over forehead, nose and cheek. Observations in the present study are almost

identical to the observations mentioned in the literature.¹² 16, Histopathological findings were typical as described by Ahmed.¹⁴ Kumar et al.¹⁵

3.21. Benign soft tissue tumours

In the present study, benign soft tissue tumours were seen in 1 patient (2%), had dermatofibroma (2%). In our study, there was 1 Dermatofibroma male patient (2%). Lesions were multiple over face, however according to Calonje et al,¹⁶ they are common in young adults, however in our study found in old age. Clinically thought of intradermal nevus initially but after histopathology diagnosed as dermatofibroma. Histopathology showed cellular type of dermatofibroma. Observations made in the present study are almost identical to the observations mentioned in the literature.¹⁴

3.22. Basal cell carcinoma

In the present study, basal cell carcinoma were seen in 01 patient (2 %) According to Minnesota study,¹⁶ males were more commonly affected than females. In our study, 01 female patient had basal cell carcinoma. With age of onset was 69 years. According to Australian case-control study by Kricke et al.¹⁷ presence of large number of naevi, freckles and solar elastosis all add to the BCC risk, however in our study large number of nevi, freckles was not associated. It is more common in sun exposed areas like head and neck. The observations made in the present study with regard to the clinical features of lesions are in concurrence with the observations made in by Purnima et al.¹⁸

In our study, 1 case (2%) was biopsied by oncosurgeon, showed typical features of Noduloulcerative type basal cell carcinoma. which were consistent with the features described by Purnima et al.¹⁸ Immunohistochemistry was not done as this patient lost her follow up in our hospital.

3.23. Summary

Fifty patients presented with epidermal and dermal skin tumours attending the Department of Dermatology, Venereology and Leprology. The highest age prevalence was in 5th decade (50%), followed by 6th decade (26%) 7th decade (20 %), least prevalence was observed in 8th decade (6 %). The female: male ratio was 1.2: 1. Patients from urban area (76%) outnumbered those from rural areas (24%). Patients most frequently affected were housewives (54%), clerks (16%), business and agriculturists (12% each). Most patients belonged to middle class (84%).

The commonest skin tumours recorded were epidermal tumours (74%), followed by dermal tumours (26%). Commonest among Epidermal tumours were seborrheic

keratosis – 28 cases (75.07%), followed by epidermoid cyst 4 cases (10.81%), acrochordons 3 cases (8.1%), keratoacanthoma & basal cell carcinoma 1 case each (2.7%). Most of the patients with epidermal tumors suffered for years (86.48%), followed by months (13.5%). Majority of the epidermal tumors presented with multiple lesions 22 cases (59.45%) and 15 cases with single lesions (40.55%). Commonest presenting symptoms among epidermal tumours was itching in 3 cases (8.1%), pain in 1 case (2.7 %), bleeding in 1 case (2.7 %). Commonest site in face among epidermal tumors were cheeks in 25 cases (67.56%), followed by forehead in 06 cases (16.21%) eyelids & chin in 02 cases each (5.4%) , and nose in 1 case (2.7%).

Commonest presenting lesions among epidermal tumors were papules in 21 cases (56.7 %), followed by plaques in 12 cases (32.4%) , nodule in 04 cases (10.8%). Among epidermal tumors majority of the lesions were firm in consistency in 30 cases (81.08%), cystic in 04 cases (10.81), soft in 03 cases (8.1 %). Among epidermal tumors, 09 cases were biopsied. clinical diagnosis concordance with histopathological diagnosis was seen in 09 cases (100%). No discordance seen.

Commonest among dermal tumors were compound nevus – 5 cases (38.46%), followed by syringoma and sebaceous hyperplasia 3 cases each (23.07%) , dermal nevus, and dermatofibroma 01 case each (7.6%). Among dermal tumors most patients suffered for years (46.15%), followed by months (30.76%) and at birth (23.07%) . Majority of the dermal tumors presented with multiple lesions 9 cases (69.23%) and 4 cases with single lesions (30.76%). All the patients with dermal tumours were asymptomatic (100%). Among dermal tumors commonest site in face is cheeks 06 cases (46.15%), followed by eyelids 03 cases (23.07%), forehead and chin in 02 cases each (15.38%). Commonest presenting lesions among dermal tumors were nodule in 7 cases (53.84 %), followed by papules in 06 cases (46.15%). Among dermal tumors all the lesions were firm in consistency (100%). Among dermal tumors, 06 cases were biopsied. clinical diagnosis concordance with histopathological diagnosis was seen in 04 cases (66.66%). Discordance seen in 02 cases (33.33%), clinically suspected as sebaceoma and dermal nevus turned out to be dermal nevus and dermatofibroma histopathologically.

4. Conclusion

1. In ageing skin over face Epidermal and dermal skin tumors highest age prevalence was observed in 5th decade (50%), and least prevalence was observed in 8th decade (6 %). The female: male ratio was 1.2: 1. The commonest skin tumours recorded were epidermal tumours (74%), followed by dermal tumors (26%).
2. Commonest among Epidermal tumours were seborrheic keratosis (75.07%), followed by epidermoid cyst

(10.81%). Most of the patients with epidermal tumors suffered for years (86.48%), followed by months (13.5%) . Majority of the epidermal tumors presented with multiple lesions (59.45%) and single lesions (40.55%). Commonest presenting symptoms among epidermal tumours was itching (8.1%), followed by pain and bleeding (2.7 % each). Commonest site in face among epidermal tumors were cheeks (67.56%), followed by forehead (16.21%) eyelids & chin (5.4%) , and nose (2.7%). Commonest presenting lesions among epidermal tumors were papules (56.7 %), followed by plaques (32.4%) , nodules (10.8%). Among epidermal tumors majority of the lesions were firm in consistency (81.08%), cystic (10.81), soft (8.1 %). Among epidermal tumors, 09 cases were biopsied. clinical diagnosis concordance with histopathological diagnosis was seen in 09 cases (100%). No discordance seen.

3. Commonest among dermal tumors were compound nevus (38.46%), followed by syringoma and sebaceous hyperplasia each (23.07%), dermal nevus, and dermatofibroma each (7.6%). Among dermal tumors most patients suffered for years (46.15%), followed by months (30.76%) and at birth (23.07%) . Majority of the dermal tumors presented with multiple lesions (69.23%) and single lesions (30.76%). All the patients with dermal tumours were asymptomatic (100%). Among dermal tumors commonest site in face is cheeks (46.15%), followed by eyelids (23.07%), forehead and chin in each (15.38%). Commonest presenting lesions among dermal tumors were nodule in (53.84 %), followed by papules in (46.15%). Among dermal tumors all the lesions were firm in consistency (100%). Among dermal tumors, 06 cases were biopsied. Clinical diagnosis concordance with histopathological diagnosis was seen in 04 cases (66.66%). Discordance seen in 02 cases (33.33%), clinically suspected as sebaceoma and dermal nevus turned out to be dermal nevus and dermatofibroma histopathologically.
4. To conclude that in ageing skin over face most common skin tumors were epidermal tumors followed by dermal tumors . Prevalance of malignant epidermal tumors in patients were (2%). Whenever in diagnostic dilemma histopathology should be supplemented to get unambiguous results.

5. Source of funding

None.

6. Conflict of interest

None.

References

1. Quinn AG, Perkins W. Non Melanoma Skin Cancer and other Epidermal Skin tumours. *Rook's Textbook of Dermatol.* 2012;3:38–52.
2. Kirkham N, Elder DE, Elenitsas R, Johnson BL, Murphy GF, Xu X. Tumors cysts of the Epidermis. *Lever's Histopathology of the Skin.* 2009;p. 791–849.
3. Jain AK, Sukhija J, Radotra B, Malhotra V. Seborrheic keratosis of theconjunctiva. *Indian J Ophthalmol.* 2004;52:154–155.
4. Burns D, Breathnach. NH Cox and CEMGriffiths. *Rook's Textbook of Dermatology.*
5. Mittal RR, Sonal J. The sign of leser-trelat. *Indian J Dermatol Venereol Leprol.* 2001;67:791–849.
6. Zaher H, Safoury OS, Mahmoud SB, Hameed HA, Mcgauran MH, et al. Keratinous cystsof the skin: identifi cation and differentiation of pilar cysts from epidermalcysts. *Indian J Dermatol.* 1966;52(4):499–508.
7. Kumar YK, Seema S, Sujatha C, Ambika H. Penile acrochordon: An unusual site of presentation- A case report and review of the literature. *Int J Health All Sci.* 2012;1(2):122–125.
8. Bishop N, Lentigos JA, Melanoma MN, Bishop JAN, Breathnach T, et al. Oxford: Blackwell publishing ltd. In: and others, editor. *Rook's Textbook of Dermatology.* vol. 3. Oxford: Blackwell publishing ltd; 2012. p. 54–57.
9. Grichnik JM, Rhodes AR, Sober AJ. Benign neoplasias and hyperplasias of melanocytes. *Dermatol General Med.* 2003;p. 1099–1122.
10. Elder D. Benign pigmented lesions and malignant melanoma. *Lever's Histoopathology of skin.* 1997;p. 675–679.
11. Katarkar A, Shah P, Jain A, Shah M. A rare case of intradermal nevus of external auditory canal presenting with otorrhoea. *Indian J Otology.* 2011;17(1):20–21.
12. Ramaswamy AS, Yenni VV, Wilfred C, Manjunatha HK, Shilpa K. Hyaline cell-rich chondroid syringoma of the finger. *Indian J Dermatol.* 2011;56(2):209–217.
13. Burns T, Breathnach S, Cox N, Griffiths C. Tumours of the skin appendages. In: and others, editor. *Rook's Textbook of Dermatology.* vol. 3. Oxford: Blackwell publishing ltd; 2012. p. 53–54.
14. Ahmedtss P, Jd, Seykora JT, Elder DE, Elenitsas R, Johnson BL. Tumors of the epidermal appendages. In: and others, editor. *Lever's Histopathology of the Skin.* Southasian: Lippincott Williams Wilkins; 2009. p. 851–909.
15. Kumar P, Shashikala P, Kumar J, Kumar P. Sebaceous hyperplasia mimicking lymphangioma. *Indian J Dermatol.* 2007;52(2):102–103.
16. Madsen A. Studies on basal-cell epitheliomaof the skin: the architecture, manner of growth, and histogenesis of thetumours-whole tumours examined in serial sections cut parallel to the skinsurface. *Acta Pathol Microbiol Scand Suppl.* 1965;117:3–63.
17. Kricer A, Armstrong BK, English DR, Heenan PJ. A dose-response curve for sun exposure and basal cell carcinoma. *Int J Cancer.* 1995;60(4):482–488.
18. Singh A, Ramesh V, Malhotra P. Basal cell carcinoma in the North Indian population: Clinicopathologic review and immunohistochemical analysis. *Indian J Dermatol, Venereol, Leprol.* 2011;77(3):328–330.

Author biography

Gnanasekaran R Assistant Professor

Rajagopal R Professor

Radhakrishnan S professor

Narmadhadevi TG Assistant Professor

Premananth P Assistant Professor

Shanmugapriya K Assistant Professor

Cite this article: Gnanasekaran R , Rajagopal R , Radhakrishnan S , Narmadhadevi TG , Premananth P , Shanmugapriya K . A study of epidermal and dermal tumors over face in ageing skin. *IP Indian J Clin Exp Dermatol* 2020;6(1):84-94.