



Case Series

A case series of agenesis of the corpus callosum in children - Clinical and neuroimaging correlation with aspects of neuropathophysiology

Anirban Chatterjee^{1*}, Subham Bhattacharya², Malay Kumar Sinha³

¹Dept. of Paediatric Medicine, Maharaja Jitendra Narayan Medical College and Hospital, Cooch Behar, West Bengal, India

²Dept. of Hematology, Nil Ratan Sircar Medical College and Hospital, Kolkata, West Bengal, India

³Dept. of Paediatric Medicine, Institute of Post Graduate Medical Education and Research, Kolkata, West Bengal, India



ARTICLE INFO

Article history:

Received 25-05-2022

Accepted 15-10-2022

Available online 07-12-2023

Keywords:

Agenesis of Corpus callosum

Colpocephaly

Neuroradiology

Neurodevelopmental delay

Seizures

ABSTRACT

Background: The corpus callosum is the largest connective fiber between two hemispheres and a crucial structure for the integrated cerebral function of the normal brain. The study of agenesis of the corpus callosum (ACC) develops insights into neurodevelopmental delays and autism in children.

Materials and Methods: This is a case series of eight children with ACC confirmed by a neuroimaging in a teaching hospital. The clinico-neuroradiological profile of ACC were studied retrospectively and reviewed clinical correlation with neuroradiology in the light of neuropathophysiology knowledge.

Results: The study group was appeared as nonsyndromic. Every subject had a normal chromosomal study by karyotyping. These ACC patients neither had a specific recognizable syndrome nor the constellation of malformations are indicative of a disorder.

The mean age of subjects was 21.3 months, and no predilection for gender. The global developmental delay was the most common presentation found in seven ACC (87.5%) children. The second commonest, four ACC (50%) patients, was seizure. Two ACC (25%) had colpocephaly. Five ACC children (62.5%) had somatic anomalies; four ACC (50%) patients had cardiac defects.

Conclusions: ACC children present a poor neurodevelopmental outcome.

The extracallosal brain anomaly determines a worse neurological prognosis in nonsyndromic ACC. Grey matter heterotopia in neuroimaging was associated with seizure in ACC children.

However, colpocephaly along with ACC may present with normal neurodevelopment. Hence, ACC in neuroimaging may have not predicted the final neurological outcome.

ACC children with normal karyotyping may have somatic malformations. Moreover, echocardiography can be considered an initial routine screening in nonsyndromic ACC children.

This is an Open Access (OA) journal, and articles are distributed under the terms of the [Creative Commons Attribution-NonCommercial-ShareAlike 4.0 License](https://creativecommons.org/licenses/by-nc-sa/4.0/), which allows others to remix, tweak, and build upon the work non-commercially, as long as appropriate credit is given and the new creations are licensed under the identical terms.

For reprints contact: reprint@ipinnovative.com

1. Introduction

The corpus callosum (CC) is the largest connective white matter of the brain.¹ The CC is predominantly an excitatory fiber for interhemispheric transfer (IHT) which is responsible for the integrated brain function.²

The CC develops from the pioneer fibers during the 12th to the 20th weeks of gestation, and crosses the midline under

the guidance of commissural patterned glial cells. This is a multistep development observed in the animal model, and can be hindered in different steps by multiple causes. These are¹: genetic defects (trisomy 18 and 13 in 20%), metabolic disorder, maternal substance use (alcohol), and congenital infections.

Only 30% to 45% of agenesis of the corpus callosum (ACC) patients have definite etiology.² Of these, 10% had chromosomal abnormalities, and 20-35% had specific

* Corresponding author.

E-mail address: dr28ac@gmail.com (A. Chatterjee).

genetic syndromes. ACC is a rare anomaly and is listed in ORPHAnet (ORPHA200).

The estimated birth-prevalence of ACC is 0.018% in a population-based study³ and 2% to 3% in a pediatric population with neurodevelopmental delay.²

ACC most commonly presents with neurodevelopmental delays in children, and the second most common is seizures. Various associated malformations with ACC are described such as somatic anomalies, facial dysmorphism, cardiac defects, etc.³

Computerized tomography (CT), or Magnetic resonance imaging (MRI) of the brain is the best choice to diagnose ACC, and treatment is mostly supportive.¹

The functional anatomical classification of CC⁴ has failed to delineate the possible neurodevelopmental deficit associated due to ACC. Hence, the study of ACC may provide an understanding of normal integrated brain function and insight into neurodevelopmental disorders in children.²

We discuss the clinico-neuroradiological features of eight ACC children in the light of literature.

2. Materials and Methods

This is a case series of eight children who were confirmed ACC by neuroradiology.

We excluded secondary ACC (destroyed after normal formation) to major neural maldevelopment like holoprosencephaly, lissencephaly, etc.

They were presented with a neurodevelopmental deficit or different neurological symptoms in the Pediatric department of Institute of Postgraduate Medical Education and Research from 2007 to 2014.

The data were obtained from medical records. The following variables were reviewed retrospectively: demography, natal history, clinical details (history, general (Including dysmorphism), and systemic examination), assessment of development; MRI (1.5 or 3 Tesla) and/ or CT brain, Karyotyping, Echocardiography, and Auditory Brainstem Evoked Responses (ABER), electroencephalography (EEG), thyroid blood tests [T3, T4, thyroid-stimulating hormone (TSH)] and relevant investigations.

Excel was used for data management and statistical calculations like mean, range, and percentage.

3. Results

The detailed analysis of the variable is laid down in table 1.

4. Discussion

ACC presents from infant to adulthood with various clinical features such as neurodevelopmental delay in children, and schizophrenia in adults.²

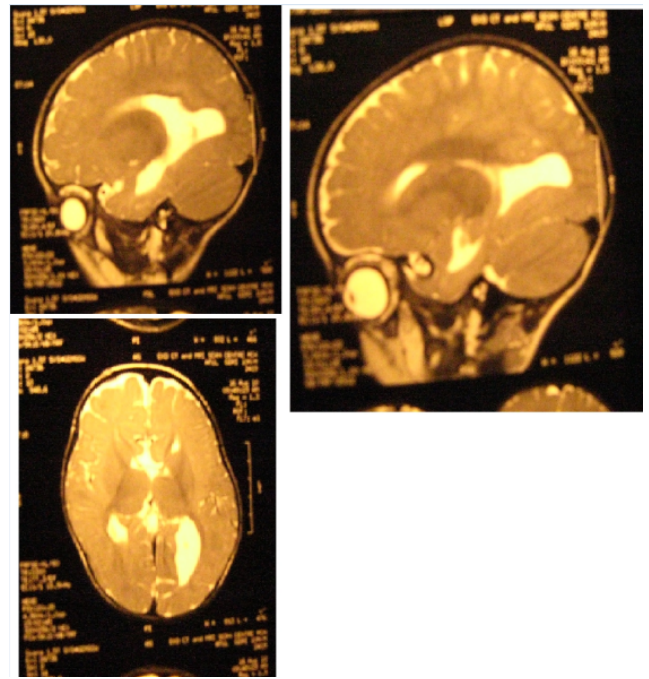


Figure 1: MRI brain (images of case no. 7) showing agenesis of the corpus callosum and colpocephaly

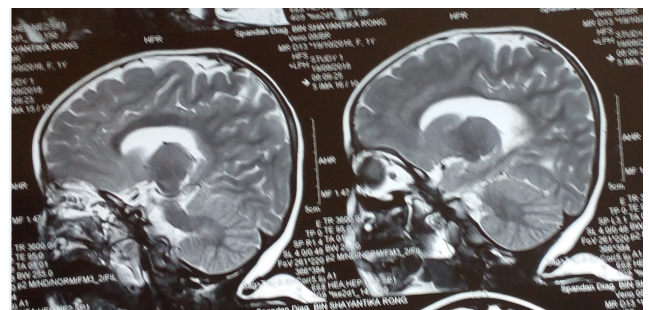


Figure 2: MRI brain the sagittal planes (images of case no. 8) showing partial agenesis of the corpus callosum (hypoplasia of splenium and a part of trunk)

The clinical presentation of ACCs commonly occurs between 12 months³ to 24 months,¹ and a range of 2 days to 10 years in children.⁵ In this series, the mean age of ACC was 21.3 months with a range of 6 months to 3 years. Although male predominance was described in literature with a ratio of 3:2⁶; gender preponderance was not observed in this series.

In this series, the global neurodevelopmental delay was observed in seven ACC children (87.5%). Similarly, other studies revealed significant number of neurodevelopmental delays in ACC patients, from 77%⁴ to 85%.⁶

However, ACC may incidentally be detected by neuroimaging in an absolutely asymptomatic child without any apparent neuro-deficit for ACC.¹ The six-year girl (case no. 6) in the series was diagnosed with ACC with

Table 1: Agenesis of corpus callosum neuroimaging diagnosed cases

Case No.	Age	Gender	Clinical Presentation	Dysmorphic features	Heart defect	Family h/o genetic disease	Natal history	MRI /CT	Extracallosal MRI /CT findings	Chromosomal analysis	Other tests
1	3yr	M	Developmental delay	Short stature coarse facies low set ears bilateral ptosis hepatosplenomegaly undescended testicle	atrial septal defect Valvular pulmonary stenosis	None	Nothing significant	CT agenesis of corpus callosum	Bilateral subdural effusion	46XY	T4 TSH - Within normal limits (wnl)
2	11mons	M	Seizure, developmental delay	Cleft lip /palate	Patent ductus arteriosus	None	Nothing significant	MRI dysgenesis of corpus callosum	Grey matter heterotopia around temporal horn of left lateral ventricle, Right frontal white matter signal abnormality with abnormal sulcal pattern	46XY	T4 TSH - wnl
3	3yr	F	Developmental delay	Facial dysmorphism low set ears hypertelorism flat occiput umbilical hernia inguinal hernia	Doppler Echo - moderate aortic regurgitation	None	Mother Chicken pox in 3rd trimester	MRI hypoplasia of splenium of corpus callosum	Parieto-occipital periventricular white matter volume loss (T2)	46XX	ABER -normal T4 TSH - wnl, VEP - wnl, ECG - wnl
4	2yr	F	Seizure started after one month of age, developmental delay	None	None	None	Perinatal Asphaxia	MRI brain agenesis of corpus callosum	Subependymal grey matter heterotopia bilateral, intraventricular subarachnoid cyst, Periventricular whitematter hypoplasia	46XX	TSH T4 T3 wnl
5	6mon	M	Developmental delay	Cleft lip cleft palate, lipoma at lumbosacral region suggestive of neural tube defect ambiguous genitalia	None	None	Nothing significant	CT agenesis of corpus callosum	None	46XY	TSH T4 T3 wnl
6	2yr	F	Atypical febrile convulsion developmental delay	None	None	None	Nothing significant	CT scan shows Colpocephaly with cc agenesis	None	46XX	T4 TSH - wnl
7	10mon	M	Developmental delay	Low set ears	Perimembranar ventricular septal defect	None	Nothing significant	MRI shows corpus callosum agenesis colpocephaly (Figure 1)	Sunependymal grey matter heterotopia on left side	46XY	TSH T4 T3 wnl EEG
8	1yr 11m	F	Global Development delay Seizure	None	None	None	Nothing significant	MRI splenium and corpus callosum Hypoplasia (Figure 2)	None	46XX	TSH - borderline raised

colpocephaly. She presented with an atypical febrile seizure but had a normal developmental assessment.

IHT occurs through an alternate route in the ACC brain.² These alternate pathways are (1) other physiological connecting fibers like anterior commissure, or (2) newly developed anatomical pathways in ACC fetal brain like Probst bundles, a misrouted interhemispheric axons to counterbalance social-adaptive functioning.⁴ Additionally, underdeveloped/diminished sized anterior commissures were found in 60%² to 73%⁴ ACC, and also non-developed/non-functioning new pathways were found in ACC.

IHT requires precise connection, whereas underdeveloped/nonfunctioning pathways in fetal ACC brain alter the cortical connectivity, consequently, the poor neurodevelopment was seen among ACC children. 'Fiber tracking' delineates the alternate pathways by diffusion tensor imaging and fiber tractography.² We could not perform 'fiber tracking' as it is not feasible in the center. Moreover, 'fiber tracking' is mainly used for research.² Therefore, only neuroimaging does not predict the final neurodevelopmental outcomes because this can not delineate alternate pathways.

In our series, four subjects had epilepsy (50%). Epilepsy was also frequently reported, 36%⁴ to 45.8 %,⁷ in ACC children.

Unterberger I et al., (2016)⁸ concluded that a malformation of cortical development (MCD) is the focus for epilepsy in ACC, not originating from ACC. Grey matter heterotopia is the most prevalent MCD in ACC neuroimaging.⁹ Grey matter heterotopia was found in two epileptic ACC in our series (case no. 2 and 4). MCDs are also responsible for the neurodevelopmental delay.⁴ The generalized tonic-clonic seizure was observed in every ACC of this series. Cases, serial number 2 and 4 were managed with phenobarbitone, and cases, serial number 6 and 8 were treated with valproate.

The extra-callosal malformations are reported frequently in ACC patients.^{3,4,9} The following extra-callosal malformation of the brain were found in our series: grey matter heterotopia, frontal white matter signal abnormality with the abnormal sulcal pattern, periventricular white matter hypoplasia, and intraventricular subarachnoid cyst. Hence, ACC is considered a part of a spectrum of generalized cerebral dysgenesis.⁹

Anatomically, ACC has two subtypes:¹ complete agenesis and partial (dysgenesis/hypoplasia). In this series, five ACC had the complete agenesis (57%) which was similar to another study (52%).⁴ Three had partial ACC agenesis. However, the clinical features do not differ in subtypes as alternate pathways are the most important determining factor.²

ACC is divided into nonsyndromic and syndromic.¹ A syndromic ACC was reported in Apert syndrome,

Aicardi syndrome,¹⁰ etc. The most common variety is nonsyndromic ACC.^{5,10}

Five ACC children in the present series had a somatic abnormality. However, we didn't find any specific features which is diagnostic of a syndrome. In the series, face dysmorphism (low-set ears, hypertelorism, congenital ptosis) were found in three ACC children. Cleft lip /palate, genitalia (ambiguous genitalia, undescended testicle), and abdominal hernia were found in two ACC children each. A similar incidence of somatic abnormalities in ACC was observed³ - gastrointestinal (7.5%), musculoskeletal (30.1%), and genitourinary (11.5%).

An array comparative genomic hybridization (aCGH) is a study to detect any imbalances in entire deoxyribonucleic acid sequence in genome,¹¹ and is used for ACC patients with somatic abnormalities to find out any associated genetic disorders. However, previous studies revealed that aCGH could not be significantly informative regarding clinical aspects of ACC.⁴ Al-Hashim AH et al. (2016)⁴ showed that 30% of genetically abnormal ACC had no clinical significance.⁴ Furthermore, a significant number ACC patients with systemic abnormalities had neither any identifiable syndrome nor a genetic etiology.⁴ Therefore, an aCGH to search out a genetic imbalances in an ACC with somatic abnormality might not be cost-effective from a clinical perspective. Hence, aCGH would be an advanced research tool.

Normal karyotypes in every subject were found in this study group. The aCGH could not be done due to non-feasibility.

Maternal infection of cytomegalovirus,¹² rubella,¹³ and influenza¹⁴ were conjectured as a causal association with ACC. A varicella non-immunized mother in the present series (case no 3) had clinically evident chickenpox during the third trimester which was diagnosed by two consultants. So serological or virological confirmation were not ordered. Of those, maternal rubella¹³ was diagnosed only by clinically similar to the index case here.

The reasoning behind the conjecture^{12–14} was a possible association between maternal infection and fetal brain malformation. Congenital varicella syndrome can cause brain anomalies mostly in the first trimester, but it is also found in the third trimester.¹⁵ Therefore, maternal chickenpox might be associated with the development of ACC. After PUBMED and Google Scholar search, we didn't find any case reported maternal chickenpox with fetal ACC. The index case, according to our knowledge, is the first report of maternal chickenpox associated with ACC.

The ACC patients with congenital heart disease were reported at 21%⁴ to 27.6%.³ Congenital heart disease was found in four subjects in this series which is higher 20.5%³ than in previous nonsyndromic ACC studies. Therefore, we emphasize echocardiographic routine screening in every nonsyndromic ACC.

In the series, neuroimaging revealed colpocephaly associated with two ACC children (cases, serial number no. 6 and 7). Colpocephaly is the disproportionate dilation of the posterior horns of the lateral ventricles in neuroimaging,² indicative of the persistence of fetal vesicular configuration in the brain.¹⁶ Colpocephaly is the most commonly found in ACC.¹⁷

One ACC child with colpocephaly (case no.7) presented with global neurodevelopment. Colpocephaly diminishes cortical association fibers, this would be the pathophysiology of neurodevelopmental delay in ACC.²

The girl child (case no 6) in the series has had an atypical febrile seizure, so CT brain was advised which revealed colpocephaly with ACC, and the cortical matter thinning around the occipital horns without any abnormality in brain parenchyma. It is inferred that an epileptic focus in colpocephaly originated from the disordered white matter of the occipital and posterior temporal region.^{2,18} Furthermore, she had a normal electroencephalogram, and normal neurodevelopmental assessment, without any neurological deficit or behavioral abnormalities. It is reported in the literature that colpocephaly was found in a normal person.¹⁹ Bodensteiner and Gay (1990)²⁰ demonstrated that neuroradiologically revealed structural change is colpocephaly; however, the white matter changes such as the diminished thickness/arrested development behind the colpocephaly could not be detected by neuroradiology. Therefore, the clinical presentation would be varied.²⁰

Finally, the knowledge of clinico-neuroradiological presentation ACC would help us to understand the CC function and neurocortical plasticity in poorly neurodeveloped children.²

5. Limitation of the Study

Retrospective study from a pediatric department.

6. Message/ Key points

A spectrum of clinical presentation of nonsyndromic ACC - from global developmental delay to asymptomatic, associated extra colossal anomaly and somatic abnormalities.

Seizure focus might be at coexisting cortical developmental malformation, not originating from ACC.

The study emphasizes echocardiographic screening of nonsyndromic ACC.

Maternal chickenpox could be an association of ACC.

7. Author Contributions

Corresponding authors (AC) and coauthors (SB,MKS) have conceptualized, designed the case series, and also analyzed, interpreted the data for the study. All authors have drafted, revised critically for important intellectual content. All authors did approve to publish the final version of the

proof. All authors agreed to be responsible for each aspect of the case study. Corresponding authors have confirmed that they will be answerable at any questions concerning accuracy or integrity related to any part of the study, and those will be investigated and answered.

8. Conflict of Interest

The authors have no conflicts of interest to declare.

9. Funding of Sources

None.

10. Acknowledgement

We are thankful to the patient and their families for giving us consent to publish those cases.

References

1. Das J, Geetha R. Corpus Callosum Agenesis. StatPearls [Internet]. Treasure Island (FL): StatPearls Publishing; 2020.
2. Paul LK, Brown WS, Adolphs R, Tyszka JM, Richards LJ, Mukherjee P, et al. Agenesis of the corpus callosum: genetic, developmental and functional aspects of connectivity. *Nat Rev Neurosci*. 2007;8(4):287–99.
3. Glass HC, Shaw GM, Ma C, Sherr EH. Agenesis of the corpus callosum in California 1983-2003: A population-based study. *Am J Med Genet A*. 2008;146A(9):2495–500.
4. Al-Hashim AH, Blaser S, Raybaud C, Macgregor D. Corpus callosum abnormalities: neuroradiological and clinical correlations. *Dev Med Child Neurol*. 2016;58(5):475–84.
5. Chacko A, Koul R, Sankhla DK. Corpus callosum agenesis. *Neurosciences (Riyadh)*. 2001;6(1):63–6.
6. Jeret JS, Serur D, Wisniewski K, Lubin RA. Clinicopathological findings associated with agenesis of the corpus callosum. *Brain Dev*. 1987;9(3):255–64.
7. Shevell MI. Clinical and diagnostic profile of agenesis of the corpus callosum. *J Child Neurol*. 2002;17(12):895–900.
8. Unterberger I, Bauer R, Walser G, Bauer G. Corpus callosum and epilepsies. *Seizure*. 2016;37:55–60.
9. Hettis SW, Sherr EH, Chao S, Gobuty S, Barkovich AJ. Anomalies of the corpus callosum: an MR analysis of the phenotypic spectrum of associated malformations. *AJR Am J Roentgenol*. 2006;187(5):1343–8.
10. Aicardi J. Abnormalities associated with migration disorders. In: Aicardi J, Bax M, Gillberg C, Ogler H, editors. *Diseases of the Nervous system in childhood*, 1st edn. London: Mac Keith Press; 1992. p. 164–202.
11. Theisen A. Microarray-based comparative genomic hybridization (aCGH). *Nat Educ*. 2008;1(1):45.
12. Chiappini E, Galli L, Paganelli S, De Martino M. Congenital cytomegalovirus infection associated with corpus callosum agenesis. *Pediatr Neurol*. 2007;36(4):277. doi:10.1016/j.pediatrneurol.2006.12.010.
13. Friedman M, Cohen P. Agenesis of corpus callosum as a possible sequel to maternal rubella during pregnancy. *Am J Dis Child*. 1947;73(2):178–85.
14. Conover PT, Roessmann U. Malformational complex in an infant with intrauterine influenza viral infection. *Arch Pathol Lab Med*. 1990;114(5):535–8.
15. Ahn KH, Park YJ, Hong SC, Lee EH, Lee JS, Oh MJ, et al. Congenital varicella syndrome: A systematic review. *J Obstet Gynaecol*. 2016;3(5):563–6.

16. Yakovlev PI, Wadsworth RC. Schizencephalies: A study of the congenital clefts in the cerebral mantle. I. Clefts with fused lips. *J Neuropathol Exp Neurol*. 1946;5:116–30. doi:10.1097/00005072-194604000-00003.
17. Noorani PA, Bodensteiner JB, Barnes PD. Colpocephaly: frequency and associated findings. *J Child Neurol*. 1988;3(2):100–4.
18. Ito Y, Oguni H, Funatsuka M, Osawa M. Clinical and EEG studies of symptomatic focal epilepsy in 7 patients with colpocephaly. *No To Hattatsu*. 2008;40(3):244–8.
19. Ciurea RB, Mihailescu G, Anton RM, Parvu D, Nica SM, Pavel G, et al. Corpus callosum dysgenesis and colpocephaly. *Rom J Neurol*. 2013;12(3):160–3.
20. Bodensteiner J, Gay CT. Colpocephaly: pitfalls in the diagnosis of a pathologic entity utilizing neuroimaging techniques. *J Child Neurol*. 1990;5(2):166–8.

Author biography

Anirban Chatterjee, Associate Professor

Subham Bhattacharya, Assistant Professor

Malay Kumar Sinha, Professor

Cite this article: Chatterjee A, Bhattacharya S, Sinha MK.

A case series of agenesis of the corpus callosum in children - Clinical and neuroimaging correlation with aspects of neuropathophysiology. *Panacea J Med Sci* 2023;13(3):852-857.