

Content available at: <https://www.ipinnovative.com/open-access-journals>

Indian Journal of Pathology and Oncology

Journal homepage: www.ijpo.co.in

Case Report

Xanthogranulomatous appendicitis: A medical marvel

Neda Ahsan^{1,*}, Bushra Siddiqui¹, Shahbaz Habib Faridi², Mohammad Feroz Alam¹,
Yahyaa Mansoor³

¹Dept. of Pathology, Jawaharlal Nehru Medical college & Hospital, AMU, Aligarh, Uttar Pradesh, India

²Dept. of Surgery, Jawaharlal Nehru Medical college & Hospital, AMU, Aligarh, Uttar Pradesh, India

³Government Medical College and Hospital, Chandigarh, India



ARTICLE INFO

Article history:

Received 18-07-2023

Accepted 09-09-2023

Available online 27-09-2023

Keywords:

Acute appendicitis

Inflammation

Laden macrophages

Xanthogranulomatous appendicitis

ABSTRACT

Xanthogranulomatous inflammation (XGI) is a rare but well- described type of chronic inflammation. It was in the genitourinary tract where it was first reported. Any organ can be involved but the most common sites are kidney followed by the gallbladder.

Histologically, it can be characterized by a collection of lipids- laden macrophages along with inflammatory infiltrate, with or without cholesterol clefts.

XGI is extremely uncommon in the appendix. Due to its atypical presentation, it is usually detected post-operatively. Sami Akbulut et al. published a comprehensive study in January 2021 and reported only 38 patients worldwide.

Here, we present a case of a 20 – year old female who came to the OPD with typical signs of Acute Appendicitis diagnosed histopathologically as Xanthogranulomatous appendicitis

This is an Open Access (OA) journal, and articles are distributed under the terms of the [Creative Commons Attribution-NonCommercial-ShareAlike 4.0 License](https://creativecommons.org/licenses/by-nc-sa/4.0/), which allows others to remix, tweak, and build upon the work non-commercially, as long as appropriate credit is given and the new creations are licensed under the identical terms.

For reprints contact: reprint@ipinnovative.com

1. Case Report

A twenty year-old nulliparous girl was brought to the surgical out Patient Department with complains of high grade fever, loss of appetite, abdominal pain, and vomiting for 8 days.

No remarkable past history or family history was present. No history of haemorrhage or any associated bleeding disorders were seen.

During the clinical examination, the patient displayed signs of potential appendicitis including rebound tenderness, pain over the McBurney's point and a positive Rovsing's sign. The laboratory results showed raised WBC counts and C – Reactive Protein. Her CBC was otherwise non-contributory.

Ultrasonography of the abdomen showed a dilated tubular, blind ended structure with gut signature arising

from caecum and an impression of inflamed Appendix was provided.

Based on the clinical presentation, physical examination, as well as findings from laboratory and radiological tests, a diagnosis of acute appendicitis was made. Consequently, an appendicectomy was performed. Per operatively, the appendix showed inflammation. No gangrenous change or perforation was noted. The excised specimen measured 4 x 0.5 cm in size (Figure 1). Grossly, the external surface was dull and congested (Figure 1).

Microscopically, Hematoxylin & Eosin (H&E) stained section from the appendix showed a partially ulcerated mucosal lining along with submucosal lymphoid aggregates, transmural mixed inflammatory infiltrate and numerous foci of aggregated foamy macrophages and few giant cells.

* Corresponding author.

E-mail address: drahsanjnmc@gmail.com (N. Ahsan).

Based on H&E examination, a diagnosis of Xanthogranulomatous Appendicitis was made.

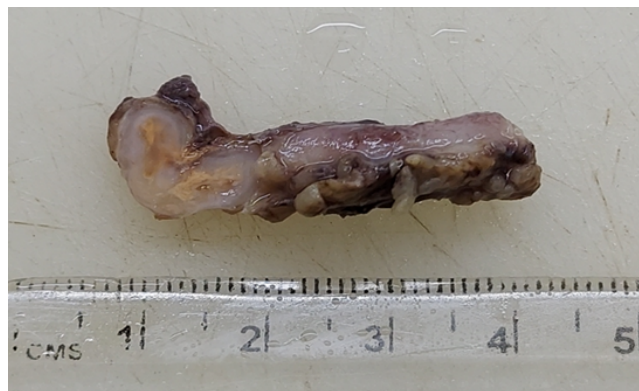

Fig. 1: Inflamed appendectomy specimen measuring 4x0.5cm. No perforation or gangrenous change notes. Outer surface is dull and congested

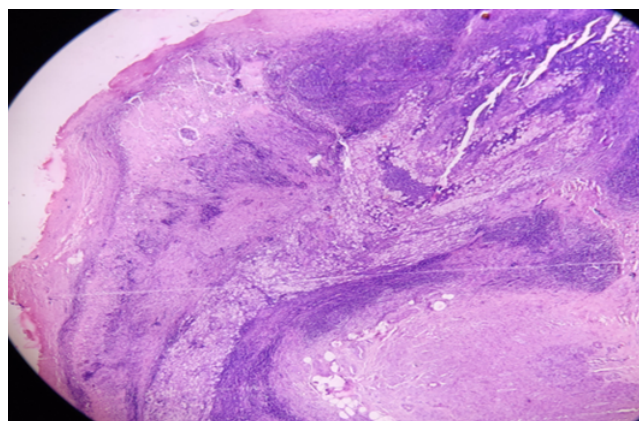


Fig. 2: Low power (4x) H&E stained section from appendix shows a partially ulcerated mucosal lining along with submucosal lymphoid aggregates and transmural mixed inflammatory infiltrate

2. Discussion

Acute Appendicitis ranks among the most prevalent acute surgical conditions affecting the abdomen. Most appendectomies usually show marked cellular infiltration on histology. Xanthogranulomatous inflammation (XGI) is an extremely rare form of chronic inflammation, indicated by the presence of predominantly lipid-laden macrophages.¹ Xanthogranulomatous Appendicitis shows prominent histiocytic clusters of Xanthoma – like cells. The exact etiopathogenesis is unknown but it occurs as a result of disturbance of fat and cholesterol metabolism due to defective lipid transport, immunologic disturbances, obstruction such as fibrosis and fecoliths.²

Cozzutto and Carbone conducted a comprehensive review of cases involving various organs extensive and

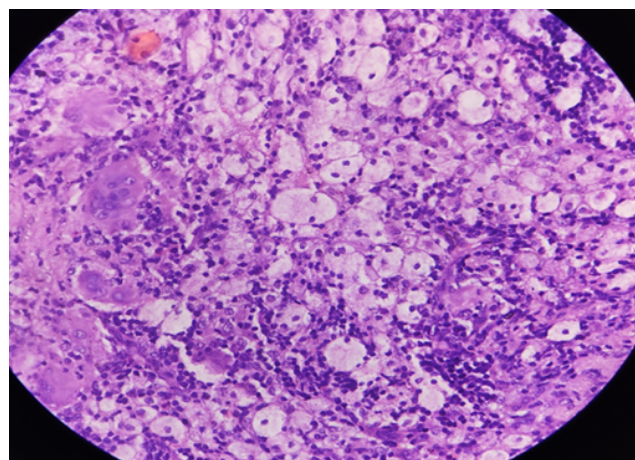


Fig. 3: High Power (40x) H & E stained section from an appendectomy specimen shows numerous foci of aggregated foamy macrophages, along with multinucleated giant cells and mixed inflammatory infiltrate predominantly lymphocytes along with neutrophils

noted that Xanthogranulomatous process is usually seen secondary to inflammation, haemorrhage, and necrosis.³ Amongst them, haemorrhage plays a crucial role in the formation of foamy macrophages. This phenomenon could be attributed to the ingestion of erythrocytes and platelets, overwhelming the lysosomal system of the macrophages, leading to the deposition of phospholipids, ultimately giving them a characteristic foamy appearance.⁴

The most common age of presentation is adults (mean age – 35 years, with 83% ranging from 21 – 78 years). This has shifted from the previous mean of 48 years due to increased incidence of cases in paediatric patients as well. No obvious sex predilection is noted.⁵ Clinical presentation of Xanthogranulomatous Appendicitis is quite variable, varying according to the spread of the disease. But most patients usually present with fever and abdominal pain.⁶

Grossly, it may present as a dull to congested brown to yellowish mass and may contain abscess cavities, or may present as an atypical growth mimicking a neoplasm.²

Microscopically, they show a diffuse mucosal to transmural collection of macrophages, predominantly foamy histiocytes, abundant hemosiderin, multinucleated giant cells, cholesterol clefts mixed with varying proportions of inflammatory cells. The most notable feature is the presence of foam cells that contain neutral fat, cholesterol and cholesterol esters.⁷

Based on the location, gross and microscopy showing granulomatous inflammation and foam cells, these can also be confused with other differentials such as Crohn's disease, Malakoplakia, tuberculosis colitis and malignancy.⁴

If transmural involvement by granulomas is absent, the likelihood of Crohn's disease can be ruled out. Similarly, the absence of Michaelis Gutmann bodies can exclude

malakoplakia which are von-kossa positive.

Distinguishing Xanthogranulomatous Appendicitis (XGA) from an infiltrative cancer can be difficult due to its aggressive nature. XGA may manifest as a mass accompanied by extensive fibrosis and inflammation, mimicking an infiltrative cancer.⁸

Other differentials can also include Mucinous epithelial neoplasm, non-mucinous epithelial and atypical acute appendicitis due to their variable presentation.

3. Conclusion

In summary, Xanthogranulomatous inflammation is a chronic and destructive inflammatory process affecting multiple organs. Xanthogranulomatous changes are extremely uncommon in the Appendix. They are identified retrospectively on pathological examination of appendiceal specimen. Sometimes it may mimic features of malignancy of the right colon. Therefore, careful clinicopathological correlation is necessary to come to a proper diagnosis.

4. Source of Funding

None.

5. Conflict of Interest

None.

References

1. Akbulut S, Demyati K, Koc C, Tuncer A, Sahin E, Ozcan M, et al. Xanthogranulomatous appendicitis: A comprehensive literature review. *World J Gastrointest Surg.* 2021;13(1):76–86.
2. Munichor M, Kerner H, Cohen H, Bickel A, Iancu TC. Xanthogranulomatous appendicitis-an incidental finding of localized pathology. *Ultrastruct Pathol.* 2000;24(1):33–9.
3. Jusoh AC, Ghani SA. Xanthogranulomatous lesion in recurrent appendicitis. *Formosan J Surg.* 2016;49(3):114–8.
4. Anindya A, Narayan R, Shail M, Chandra N. Xanthogranulomatous Appendicitis: Entity of Surprise. *Arch Med Health Sci.* 2018;6(1):120–1.
5. Laishram S, Shimray R, Pukhrabam GD, Sarangthem B, Sharma AB. Xanthogranulomatous inflammatory lesions: a 10-year clinicopathological study in a teaching hospital. *Bangladesh J Med Sci.* 2014;13:302–5.
6. Kulkarni MP, Sulhyan KR, Barodawala SM, Yadav DH. Histopathological study of lesions of the appendix. *Int J Health Sci Res.* 2017;7:90–5.
7. Daniels J, Montgomery E. Inflammatory disorders of the appendix. In: *Surgical Pathology of the GI Tract, Liver, Biliary Tract, and Pancreas.* Philadelphia, Pa, USA: Saunders; 2009. p. 395–404.
8. Singh V, John KM, Malik A, Pareek T, Dutta V. Xanthogranulomatous appendicitis: Uncommon histological variant of a common entity. *Med J Armed Forces India.* 2015;71(Suppl 1):19–21.

Author biography

Neda Ahsan, Resident  <https://orcid.org/0009-0003-7686-151X>

Bushra Siddiqui, Assistant Professor

Shahbaz Habib Faridi, Assistant Professor

Mohammad Feroz Alam, Assistant Professor

Yahyaa Mansoor, Student

Cite this article: Ahsan N, Siddiqui B, Faridi SH, Alam MF, Mansoor Y. Xanthogranulomatous appendicitis: A medical marvel. *Indian J Pathol Oncol* 2023;10(3):307-309.