

Content available at: <https://www.ipinnovative.com/open-access-journals>

Indian Journal of Clinical Anaesthesia

Journal homepage: www.ijca.in

Case Report

Anaesthetic management of post-PTCA cardiac tamponade from cath lab to cardiothoracic operating theater

Ameerunnisha Begum^{1*}, Niranjni Sivados¹, Lakshmi Ramakrishnan¹

¹Dept. of Anaesthesiology and Pain Medicine, Saveetha Institute of Medical and Technical Sciences, Thandalam, Tamil Nadu, India



ARTICLE INFO

Article history:

Received 26-03-2024

Accepted 30-04-2024

Available online 03-06-2024

Keywords:

Cardiac anaesthesia

Cath lab

Post PTCA

Percutaneous coronary interventions

ABSTRACT

Cardiac tamponade is a medical emergency characterized by the accumulation of fluid in the pericardial sac, exerting pressure on the heart and impairing its ability to pump blood effectively. This condition can result from various causes, including trauma, infection, malignancy, or complications of medical procedures such as percutaneous coronary interventions (PCI) like percutaneous transluminal coronary angioplasty (PTCA). The anaesthesiologists play a pivotal role as peri operative physicians in the catheterization laboratory and intensivists in the ICU in prompt recognition and intervention which is crucial to prevent hemodynamic collapse and improve patient outcomes. In this case, a female in her fifties with a history of previous PCI developed cardiac tamponade shortly after undergoing PTCA. Despite immediate stabilization attempts in the catheterization laboratory, the patient's condition deteriorated rapidly, necessitating emergency pericardiocentesis and subsequent thoracotomy for definitive management. The successful outcome of this case underscores the importance of early recognition, rapid intervention, and a multidisciplinary approach in managing cardiac tamponade post-PTCA.

This is an Open Access (OA) journal, and articles are distributed under the terms of the [Creative Commons Attribution-NonCommercial-ShareAlike 4.0 License](https://creativecommons.org/licenses/by-nc-sa/4.0/), which allows others to remix, tweak, and build upon the work non-commercially, as long as appropriate credit is given and the new creations are licensed under the identical terms.

For reprints contact: reprint@ipinnovative.com

1. Introduction

Cardiac tamponade following percutaneous transluminal coronary angioplasty (PTCA) is a rare but potentially life-threatening complication that demands prompt recognition and decisive management.¹ While PTCA procedures have revolutionized the treatment of coronary artery disease, the incidence of cardiac tamponade, though low, remains a significant concern. This case report sheds light on the intricate management of a patient who developed cardiac tamponade post-PTCA, detailing the collaborative efforts spanning from the catheterization laboratory (cath lab) to the cardiothoracic operating theater (OT). In the cath lab, meticulous procedural techniques and vigilant monitoring are paramount in preventing and promptly identifying

cardiac tamponade.² Despite adherence to stringent protocols, this complication can still manifest, underscoring the unpredictable nature of interventional cardiology. Once cardiac tamponade is suspected or confirmed, swift action is imperative to stabilize the patient's hemodynamics and avert catastrophic consequences.³

Transitioning from the cath lab to the cardiothoracic OT presents a unique set of challenges. Seamless communication and coordination among the multidisciplinary team are essential to ensure a smooth transfer and continuity of care. In the OT, the focus shifts to definitive management, typically involving pericardiocentesis or emergent surgical intervention, depending on the severity and etiology of the tamponade.⁴ This case report aims to highlight the intricacies involved in managing post-PTCA cardiac tamponade, emphasizing the critical role of teamwork, clinical acumen, and rapid

* Corresponding author.

E-mail address: manjumathesan91@gmail.com (A. Begum).

decision-making. By sharing our experience, we hope to contribute to the collective knowledge base and enhance awareness of this rare yet potentially fatal complication among healthcare providers involved in the care of cardiac patients undergoing interventional procedures.

2. Case Report

A female in her fifties presented to the ER with chest pain and ECG showing features of ST elevation in the chest leads. She had previous history of PCI to RCA done 3 months ago and was on oral antiplatelets. She was wheeled into the cathlab for PTCA to LAD. Procedure was completed successfully and was transferred to recovery room. Post-procedure, she developed sudden bradycardia and was given Inj. atropine 0.6 mg and transferred to the ICU. On arrival at the ICU, she was hemodynamically unstable with a blood pressure of 80/30mmhg and heart rate of 130/min and the ECG showed electrical alternans with severe hypotension and tachycardia. Inotropes (Inj.noradrenaline infusion) was started, patient was sedated with inj.fentanyl 100 mcg and paralysed with atracurium 50 mg, intubated with 7.5 size ETTube and the right Internal jugular vein central line with femoral arterial line was secured. A bedside echo was done which showed pericardial effusion with cardiac tamponade, an emergency pericardiocentesis was done and a catheter was placed, 600 ml of blood was drained through it, following a transfusion of 1 unit PRBC an urgent CT aortogram was done which showed features of suspicious of Aneurysm around the left circumflex artery, another 2 units of PRBC was transfused in the ICU. Following increased blood collection from the pericardial pigtail catheter drain and worsening hemodynamics, the decision to proceed for emergency thoracotomy was made. The patient was taken for the procedure under ASA 5E. The cardio thoracic OT was made ready with necessary blood products, emergency drugs and cardiopulmonary bypass circuit on standby. All invasive lines were connected. The patient was induced with fentanyl 200 mcg and midazolam 2mg and anaesthesia was maintained with an oxygen air mixture along with isoflurane and ionotropic supports. About 1000 ml of blood was gushing upon opening of the pericardial sac, intraoperatively 1-unit PRBC and 2 FFP were transfused. A rent in the Right ventricle was identified and tunneled Dacron grafts were used to close it and hemostasis was achieved.(Figures 1 and 2) Post procedure the patient was transferred to CT ICU on IPPV and inotropes were tapered slowly. The patient improved hemodynamically and there was no evidence of further bleeding. Post operative Chest x-ray and bed side ECHO were found to be fairly normal with only post operative changes. The patient was extubated on POD 2 and is currently discharged from the hospital with weekly follow-ups and on dual anti platelet therapy.

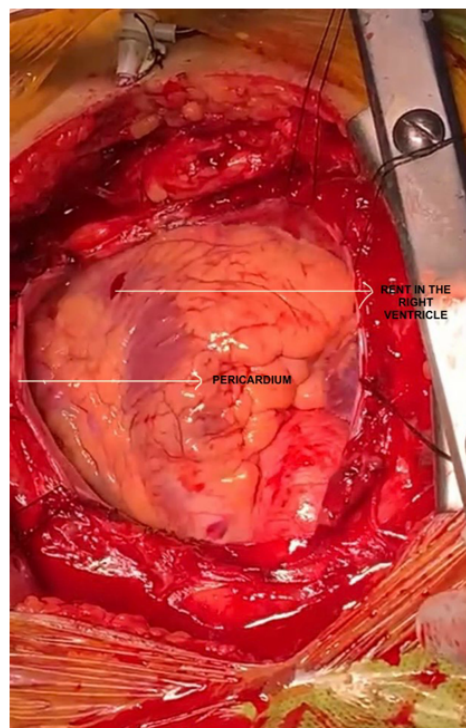


Figure 1: Rent in the right ventricle

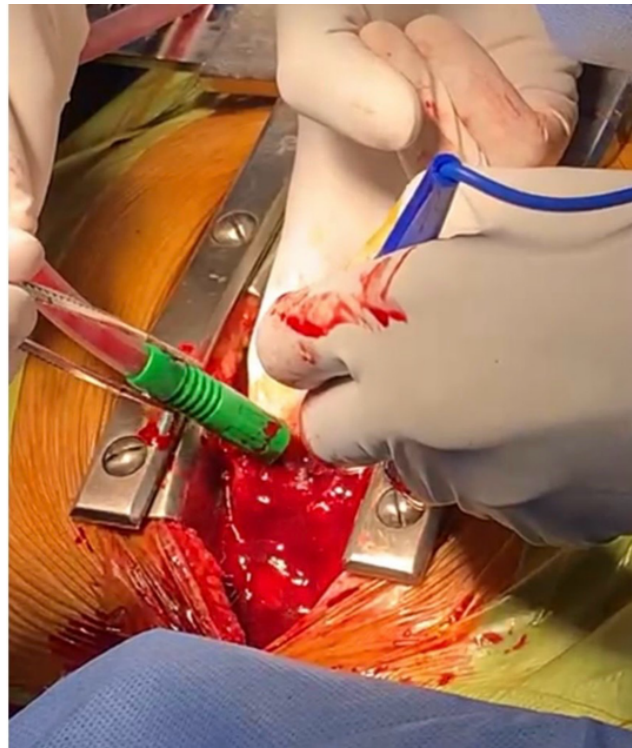


Figure 2: Opening of the Pericardium

3. Discussion

Cardiac tamponade following percutaneous transluminal coronary angioplasty (PTCA) is a rare but potentially life-threatening complication that requires prompt recognition and intervention. In this case, we encountered a patient who developed cardiac tamponade shortly after undergoing PTCA, highlighting the challenges associated with its management and the importance of a multidisciplinary approach. The development of cardiac tamponade post-PTCA can be attributed to various factors, including inadvertent injury to the myocardium or coronary vessels during the procedure, as well as the use of anticoagulant and antiplatelet medications. In our patient, the prompt onset of symptoms, including hypotension and tachycardia, raised suspicion for cardiac tamponade, prompting immediate evaluation and intervention.

The initial management of cardiac tamponade in the catheterization laboratory focused on stabilizing the patient's hemodynamics while preparing for definitive treatment. Bedside echocardiography and POCUS (point of care ultrasound) played a crucial role in confirming the diagnosis and guiding pericardiocentesis, allowing for the rapid removal of the accumulated pericardial fluid. However, it is important to note that pericardiocentesis may be challenging in the setting of acute coronary artery perforation, necessitating surgical exploration and repair. Transitioning from the catheterization laboratory to the cardiothoracic operating theater required seamless communication and collaboration among the interventional cardiology and cardiothoracic surgery teams. Once in the operating theater, the patient underwent emergent surgical intervention, which included exploration of the pericardial space, repair of the right ventricular rent, and evacuation of any remaining hematoma or effusion. This underscores the importance of a coordinated approach and the availability of resources to manage this critical complication effectively.

The successful outcome in this case can be attributed to several factors, including the prompt recognition of cardiac tamponade, the rapid initiation of appropriate interventions, and the expertise of the multidisciplinary team involved in the patient's care.

When compared to other studies, Mixon et al. described a case involving anterior myocardial infarction treated with thrombolytics, leading to postinfarction pericarditis.⁵ Bottner et al. highlighted a novel complication of stent implantation with adjuvant platelet IIb/IIIa receptor inhibitors, resulting in cardiac tamponade treated by pericardiocentesis and platelet transfusion.⁶ Kim et al. presented a case of ST-elevation myocardial infarction managed with PCI and intravenous glycoprotein IIb/IIIa inhibitor, resulting in cardiac tamponade and subsequent subacute stent thrombosis.⁷

Hashidomi et al. encountered a case where septal collateral artery dilation led to cardiac tamponade, managed

by pericardiocentesis and coil embolization.⁸ Chen KM et al. reported a case of cardiac tamponade which developed post right internal jugular vein central line placement during trauma resuscitation, managed with emergency median sternotomy, evacuation and internal jugular vein repair.⁹ Desikan reported a case of anaesthetic management of cardiac tamponade in peri arrest stage in cath lab, by giving procedural sedation for pig tail catheterisation and needle aspiration following which the patient improved hemodynamically.¹⁰

Yoshida et al. reported a case of cardiac tamponade developed post operatively after aortic arch replacement which was managed with emergency left thoracotomy.¹¹ Heo et al. describes the management of cardiac tamponade by proceeding to emergency left anterior thoracotomy with one lung ventilation with double lumen tube and induction with remimazolam but they had reported significant hemodynamic variations noted with remimazolam.¹² Wharton et al. have successfully diagnosed and managed a case of cardiac tamponade with the help of point of care ultrasound and pericardiocentesis guided by pocus in the ICU.¹³ Doniger SJ et al have presented 2 pediatric cases of pericardial effusion identified through point of care ultrasound and one patient was managed with pocus guided pericardiocentesis and the other patient had an additional mediastinal mass which was surgically explored. Pocus played a major role in identifying such life threatening conditions.¹⁴

Cameron E et al. have described the role of POCUS in diagnosing life threatening cardiac tamponade in a patient with JAK2 mutation myeloproliferative syndrome. Following which pericardiocentesis with removal of serosanguinous fluid was done.¹⁵ The management of post-PTCA cardiac tamponade requires a coordinated and multidisciplinary approach, with timely recognition, prompt intervention, and close monitoring being paramount for optimal patient outcomes. This case explains the importance of vigilance, knowledge of POCUS and preparedness in managing rare but potentially life-threatening complications associated with interventional cardiology procedures.

4. Conclusion

This case report emphasizes the most dangerous but rare complication of PTCA and the importance of early identification of cardiac tamponade through POCUS and its surgical intervention in improving patient outcomes. It highlights the importance of a proactive approach by anaesthesiologists in identifying and managing complications associated with PTCA. Continued vigilance, prompt recognition, and a coordinated multidisciplinary effort are essential for ensuring optimal outcomes in patients undergoing interventional cardiology procedures. This case also highlights the importance of the knowledge of POCUS for anaesthesiologists as they play the dual

role of perioperative physicians as well as intensivists, and therefore their paramount role in diagnosing critical events and making life saving decisions. This case contributes to the growing body of evidence aimed at improving the safety and efficacy of PTCA and underscores the need for ongoing research and education in this field.

5. Source of Funding

None.


6. Conflict of Interest

None.

References

- Adler Y, Ristić AD, Imazio M, Brucato A, Pankuweit S, Burazor I, et al. Cardiac tamponade. *Nat Rev Dis Primers*. 2023;9(1):36.
- Alvarez AAM, Bilal MA, Manasrah N, Chaudhary A. Iatrogenic Cardiac Tamponade Secondary to Central Venous Catheter Placement: A Literature Review. *Cureus*. 2023;15(4):e37695.
- Hoit BD. Pericardial Effusion and Cardiac Tamponade Pathophysiology and New Approaches to Treatment. *Curr Cardiol Rep*. 2023;25(9):1003–14.
- Alsenan AK, Dhneem HNA, Alfandi HA, Aldahan HA, Almadan HM, AlSaif HH, et al. Iatrogenic Causes of Cardiac Tamponade Resulting From Surgical Procedures: An Overview. *Cureus*. 2023;15(1):e33773.
- Mixon TA, Tak T, Lawrence ME. Cardiac tamponade complicating myocardial infarction in the era of thrombolytics and platelet IIb/IIIa: case report and literature review. *Am J Geriatr Cardiol*. 2001;10(3):133–8.
- Bottner RK, Hardigan KR. Cardiac tamponade following stent implantation with adjuvant platelet IIb/IIIa receptor inhibitor administration. *Cathet Cardiovasc Diagn*. 1997;40(4):380–2.
- Kim SS, Jeong MH, Sim DS, Park KH, Hong YJ, Kim JH. Sequential development of cardiac tamponade and subacute stent thrombosis after primary percutaneous coronary intervention for acute ST-segment elevation myocardial infarction: A case report. *J Cardiol Cases*. 2009;1(2):e75–9.
- Hashidomi H, Saito S. Dilation of the septal collateral artery and subsequent cardiac tamponade during retrograde percutaneous coronary intervention using a microcatheter for chronic total occlusion. *J Interv Cardiol*. 2010;24(1):73–6.
- Chen KM, Hasoon J, Nguyen A. Anesthetic Considerations for Cardiac Tamponade after Internal Jugular Central Line Placement during Trauma Resuscitation: A Case Report. *Vasc Specialist Int*. 2023;39:17.
- Desikan S. Abstract PR016: Anesthetic Management of A Patient with Cardiac Tamponade. *Anesth Analg*. 2016;123(3S):28.
- Yoshida K, Tanaka S, Watanabe K. Starting induction of general anesthesia after complete preparation for emergency surgical drainage in all patients with cardiac tamponade. *Ain-Shams J Anesthesiol*. 2021;13:69.
- Heo HJ, Mda, Kim G, Mda, Kim YY, Mda, et al. Can remimazolam be safely used in cardiac tamponade?: A case report. *Medicine*;102(32).
- Wharton RH, Greenstein SA. PMCID. 2022.
- Doniger SJ, Ng N. Cardiac point-of-care ultrasound reveals unexpected, life-threatening findings in two children. *Ultrasound J*. 2020;12:4.
- Cameron E, Istrail L. Diagnosing Early Cardiac Tamponade in Patient with JAK2+ Myeloproliferative Syndrome with Point of Care Ultrasound. *POCUS J*. 2021;6(1):13–5.

Author biography

Ameerunnisha Begum, Post Graduate  <https://orcid.org/0009-0008-3264-8860>

Niranjni Sivados, Post Graduate  <https://orcid.org/0000-0002-5776-5683>

Lakshmi Ramakrishnan, Professor  <https://orcid.org/0000-0003-4984-4688>

Cite this article: Begum A, Sivados N, Ramakrishnan L. Anaesthetic management of post-PTCA cardiac tamponade from cath lab to cardiothoracic operating theater. *Indian J Clin Anaesth* 2024;11(2):261-264.