



Case Report

Anesthetic management of broncho- alveolar lavage in pulmonary alveolar proteinosis: A case report

Sucheta Gaiwal¹, Abinav Sarvesh S P S^{1*}, Nimitha Prasad¹

¹Dept. of Anesthesiology, Liavati Hospital and Research Centre, Mumbai, Maharashtra, India



ARTICLE INFO

Article history:

Received 22-02-2024

Accepted 07-03-2024

Available online 03-06-2024

Keywords:

Pulmonary alveolar proteinosis

Whole lung lavage

One lung ventilation

ABSTRACT

Background: Pulmonary alveolar proteinosis (PAP) is a very rare, life threatening, noninflammatory, diffuse lung disorder characterized by dense accumulation of lipo-proteinaceous material within the alveoli causing hypoxemia, restrictive lung disease leading to respiratory failure. Whole lung lavage (WLL) is considered as the treatment of choice which includes infusing warm saline in the lungs and draining it out with the lipo-porteinaceous materials thereby clearing the obstruction. WLL requires good team co-ordination between the anaesthesiologists, pulmonologists and physiotherapists. The procedural course is challenging in many aspects like hypoxaemia and hemodynamic fluctuations. Post procedure short term mechanical ventilation is commonly required.

Case Presentation: A 45 year old female, diagnosed case of PAP presented with dyspnea at rest with increasing oxygen requirement. After clinical examination and investigations, due to severity of the disease, broncho-alveolar lavage (BAL) of left lung was planned with subsequent right lung BAL after few days. During the procedure, desaturation upto 78% was noted. With meticulous corrective measures, saturation picked up and the procedure was completed uneventfully. Post-operatively patient was mechanically ventilated and extubated after 32 hours.

Conclusions: WLL is the treatment of choice for PAP which involves multidisciplinary approach with multiple challenges. Pre-oxygenation, adequate lung isolation with left sided double lumen tube (DLT), one lung ventilation with positive end expiratory pressure (PEEP), vigilant intra-operative monitoring, cautious use of positional manoeuvres and recruitment manoeuvres with a good teamwork is the key for successful outcome.

This is an Open Access (OA) journal, and articles are distributed under the terms of the [Creative Commons Attribution-NonCommercial-ShareAlike 4.0 License](https://creativecommons.org/licenses/by-nc-sa/4.0/), which allows others to remix, tweak, and build upon the work non-commercially, as long as appropriate credit is given and the new creations are licensed under the identical terms.

For reprints contact: reprint@ipinnovative.com

1. Introduction

Pulmonary alveolar proteinosis (PAP) is a very rare yet life threatening lung disorder with an incidence rate of approximately 1 per million.¹ The disease process involves accumulation of lipo-proteinaceous material in the alveoli causing mechanical obstruction, disruption of surfactant homeostasis, severely impairing pulmonary gas exchange, leading to respiratory failure. In the late 1960s, a therapeutic procedure called as whole lung lavage (WLL) was first done

for PAP and is still considered as gold standard therapy. WLL includes infusing warm sterile saline in the lungs and draining it out with the lipo-porteinaceous materials thereby clearing the obstruction.² Studies show long term durable benefits of WLL for PAP but still few patients require repeated lavages.³ Patients who have autoimmune PAP, the most common type where auto-antibody against pulmonary granulocyte macrophage colony stimulating factor (GM-CSF) is found, can benefit from administration of GM-CSF along with WLL. WLL requires a well co-ordinated teamwork involving anesthesiologist, pulmonologist and physiotherapist, which also sets unique challenges to each

* Corresponding author.

E-mail address: asarvesh007@gmail.com (A. Sarvesh S P S).

one of them. During procedure oxygen saturation and hemodynamics are very unstable especially during one lung ventilation (OLV) and changes in blood gas parameters are noted. Post procedural course may be unpredictable as the washed lungs are unable to function normally immediately following lavage hence most patients require post procedure mechanical ventilation which can also help in correction of blood gas parameters.⁴

2. Case Presentation

A 45-year-old female with no known co-morbidities, a diagnosed case of PAP presented with dyspnea at rest, non-productive cough and increasing requirement of oxygen support. On pre-operative examination patient was tachypneic, hypoxaemic at rest (SpO₂ 87%, PaO₂ 62 mmHg on room air), requiring oxygen support 6 l/min by Hudson mask to maintain oxygen saturation of 95%. Her respiratory rate was 28 breaths/minute. On auscultation, bilateral crepitations were heard. Chest X-ray showed homogenous opacities with air bronchogram in bilateral lungs (Fig.1). Pre-operative HRCT showed crazy pavement pattern with ground glass opacities, consolidations in bilateral parenchyma with inter and intralobular thickening. Other routine lab investigations were normal. Her pre-operative ABG showed pH 7.2, pCO₂ 67mm Hg, po₂ 109mm Hg on 4 l/min oxygen support. Considering patient's poor oxygen reserve and increasing requirement of oxygen, it was planned to perform only left lung broncho alveolar lavage (BAL) since clinical examination and imaging modalities revealed more significant involvement of left lung. Informed written consent of patient was taken.

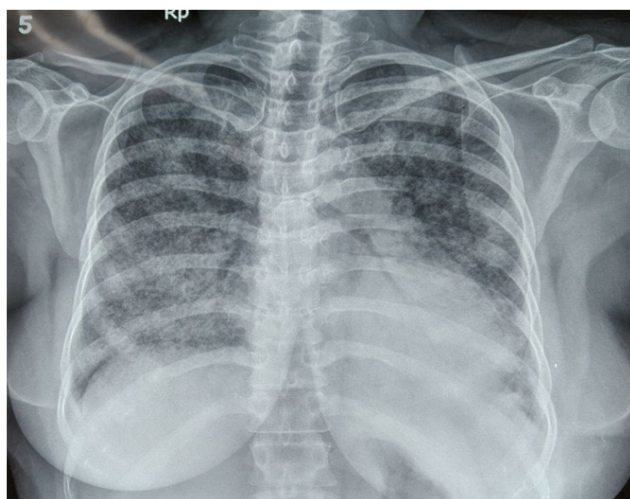


Figure 1: Chest X-ray AP view demonstrating diffuse PAP

On day of procedure, patient was shifted to operating room with 6 l/min oxygen via Hudson mask. Spo₂, ECG, NIBP monitors were attached. A 18 G IV line was secured. Right radial artery was cannulated for continuous arterial

pressure monitoring and arterial blood gas (ABG) analysis. Anaesthesia was induced with 100 mcg fentanyl, 80 mg propofol and 40 mg atracurium. Sevoflurane was used for maintenance of anesthesia. After 3 minutes of ventilation a 37 F left sided double lumen tube (DLT) was inserted and correct placement confirmed by fibre-optic bronchoscope. One lung ventilation (OLV) of right lung was initiated by clamping bronchial lumen. A Y –connector was attached to the bronchial tube; one limb for infusing saline and the other limb to drain it out.

The pulmonologist performed BAL by infusing aliquots of 400 ml warm 0.9% saline from a height of 30cm above the patient, a skilled physiotherapist performed manual chest vibration percussion positional manoeuvres to achieve optimum filling and drainage of all lung segments and the fluid is then drained out. Various positional manoeuvres were used: Trendelenburg position for inflow making left lung dependent and then reverse trendelenburg position making the lung nondependent to facilitate outflow of instilled fluid. Right and left tilt positions were provided to assist fluid distribution to all segments of the lung.

A total of 6.7 L fluid was infused in aliquots till the milky colored effluent changed to clear fluid. (Figure 2).



Figure 2: Effluent after BAL: Milky fluid clearing in subsequent bottles

Airway pressure, tidal volume, end tidal CO₂, ABG and the net positive balance of the lavaged fluid (difference of amount of fluid instilled and drained) were meticulously monitored. During the process whenever patient desaturated (maximum reduction in SPO₂ was 78%), double lung ventilation was provided. Patient required 2 doses of 20 mg furosamide because serial ABGs revealed a fall in haematocrit suggesting haemodilution. After the procedure, recruitment manoeuvres were applied to the lavaged lung to restore its expansion. Post procedure DLT was replaced with 8 mm cuffed single lumen endotracheal tube. Final fibre-optic bronchoscopy to confirm complete drainage of instilled fluid and also to make sure non spillage of fluid to right lung was done and patient was shifted to intensive care unit for assisted mechanical ventilatory support. Chest physiotherapy and ETT suctioning was repeated in ICU. Patient was later extubated after 32 hours. Low flow oxygen 4 L/hr was continued for 24 hours. After that patient was maintaining SPO₂ 97% on room air.

Fluid cytology revealed alveolar macrophages, periodic acid-schiff (PAS) stain positivity favoring PAP.

One week later patient underwent right lung lavage.

Serial chest radiographs revealed significant improvement.

Patient was discharged on post operative day 3 after right lung lavage.

3. Discussion

Pulmonary alveolar proteinosis is a rare disorder. The most common type being the autoimmune PAP where auto-antibodies are found against pulmonary granulocyte-macrophage colony stimulating factor (GM-CSF) causing macrophage dysfunction, disruption of surfactant homeostasis resulting in reduced surfactant clearance from alveoli. This causes alveolar obstruction due to deposition of lipo-proteinaceous materials. Investigatory findings commonly reveal patchy air-space infiltration in chest imaging, restrictive pattern with reduced diffusion capacity in pulmonary function test and broncho-alveolar lavage fluid rich in alveolar macrophages. The mainstay of treatment is WLL to remove the lipo-proteinaceous materials.⁵

Lung separation under general anaesthesia with DLT and lavage of the non ventilated lung require good co-ordination between the anaesthesiologist, pulmonologist and physiotherapist and it proposes different challenges to each. Monitoring of airway pressure, tidal volume and SPO₂ during OLV is crucial to detect fluid leakage in ventilated lung.

We preferred left sided DLT because right sided DLT tends to occlude right upper lobe bronchus.

Intra-operative hypoxemia is a commonly faced situation and few trouble shoots for it have been mentioned in Figure 3.

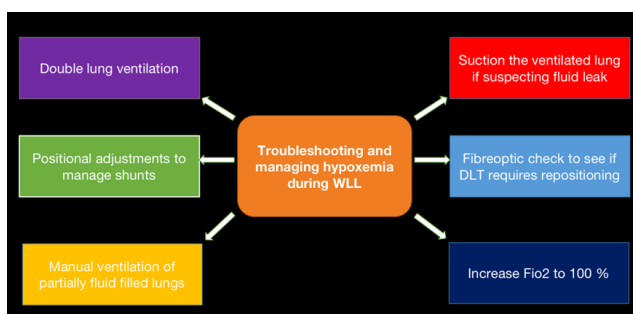


Figure 3: Troubleshooting and managing hypoxemia during BAL

Rising airway pressure and decreasing tidal volume may indicate fluid leak into the ventilated lung. Hence, aseptic suctioning of the ventilated lung is indicated in these cases followed by fibre-optic check to see if the DLT needs readjustment because adequate lung isolation is the key to success to prevent leakage of fluid into the ventilated lung

resulting in hypoxia.⁶

We needed repeated endobronchial suctioning and double lung ventilation intermittently to maintain saturation in our patient.

We changed position of our patient during inflow and outflow of fluid which could have helped us to reduce V/Q mismatch because keeping the lung being lavaged in dependent position during filling phase, the hydrostatic pressure created by column of saline above the patient decreased perfusion of the lavaged lung, activating hypoxic pulmonary vasoconstriction (HPV) and resulting in diversion of blood to the ventilated lung, prevention severe hypoxia. Whereas during drainage phase, we kept the lung to be lavaged in nondependent position, decreasing the shunt fraction by diverting blood flow towards the ventilated lung by gravity, improving oxygenation.⁷

This meticulous change in position helped in minimizing shunt and hypoxia during BAL.

We also tried cautiously increasing the limit of peak airway pressures from 40mmHg to 50mmHg for 15 seconds which provided us extra tidal volume thereby preventing severe hypoxemia.

Other strategies suggested to prevent hypoxemia during BAL include manually ventilating partially fluid filled lungs, concomitant use of inhaled nitric oxide, ipsilateral pulmonary artery occlusion of non ventilated lung, hyperbaric oxygen, extracorporeal membrane oxygenation.⁸

4. Conclusion

PAP is an uncommon yet life threatening disorder characterized by intra-alveolar accumulation of lipo-proteinacious material. The mainstay of treatment is WLL which involves multi-disciplinary approach with multiple challenges. Pre-oxygenation, adequate lung isolation with DLT, OLV with PEEP, meticulous ventilatory monitoring, cautious use of recruitment manoeuvres and positional manoeuvres for the lung to be lavaged and postoperative controlled ventilation with co ordination and teamwork involving pulmonologist, anaesthesiologist, physiotherapist and intensivist is the key for successful outcome.

5. Source of Funding

None.

6. Conflict of Interest

None.


References

1. Hadda V, Tiwari P, Madan K, Mohan A, Gupta N, Bharti S, et al. Pulmonary alveolar proteinosis: Experience from a tertiary care center and systematic review of Indian literature. *Lung India*. 2016;33(6):626–34.

2. Jung JW, Lee H, Oh J. Anesthetic management during whole-lung lavage using lung ultrasound in a patient with pulmonary alveolar proteinosis: a case report. *Yeungnam Univ J Med.* 2021;38(4):374–80.
3. Beccaria M, Luisetti M, Rodi G, Corsico AG, Zoia MC, Colato S, et al. Long-term durable benefit after whole lung lavage in pulmonary alveolar proteinosis. *Eur Respir J.* 2004;23(4):526–31.
4. Mata-Suarez SM, Castro-Lalín A, Loughlin SM, Domini JD, Bianco JC. Whole-Lung Lavage-a Narrative Review of Anesthetic Management. *J Cardiothorac Vasc Anesth.* 2022;36(2):587–93.
5. Manohar M, Bansal P. Whole lung lavage in pulmonary alveolar proteinosis: anesthetic management and challenges. *Ain-Shams Journal of Anesthesiology.* 2022;.
6. Abdelmalak BB, Khanna AK, Culver DA, Popovich MJ. Therapeutic Whole-Lung Lavage for Pulmonary Alveolar Proteinosis: A Procedural Update. *J Bronchology Interv Pulmonol.* 2015;22(3):251–8.
7. Misal US, Joshi S, Shaikh MM. Delayed recovery from anesthesia: A postgraduate educational review. *Anesth Essays Res.* 2016;10(2):164–72.
8. Nadeau MJ, Côté D, Bussi eres JS. The combination of inhaled nitric oxide and pulmonary artery balloon inflation improves oxygenation

during whole-lung lavage. *Anesth Analg.* 2004;99(3):676–9.

Author biography

Sucheta Gaiwal, Consultant Anaesthesiology  <https://orcid.org/0009-0001-3968-5364>

Abinav Sarvesh S P S, DNB Anesthesiology Resident

Nimitha Prasad, DNB Anaesthesiology Resident

Cite this article: Gaiwal S, Sarvesh S P S A, Prasad N. Anesthetic management of broncho- alveolar lavage in pulmonary alveolar proteinosis: A case report. *Indian J Clin Anaesth* 2024;11(2):251-254.