



## Original Research Article

# Efficacy of superficial cervical plexus block in the management of neck pain due to surgical positioning in patients undergoing burr-hole craniotomy for unilateral chronic subdural hematoma under scalp block: A prospective randomized control trial

Shekhar Anand<sup>1</sup>, Pragya Shukla<sup>2\*</sup>, Kavita Meena<sup>3</sup>, Rajesh Meena<sup>3</sup>

<sup>1</sup>Dept. of Anesthesiology, United Institute of Medical Sciences (UIMS), Prayagraj, Uttar Pradesh, India

<sup>2</sup>Dept. of Anesthesiology, Heritage Institute of Medical Sciences (HIMS), Varanasi, Uttar Pradesh, India

<sup>3</sup>Dept. of Anesthesiology, Institute of Medical Sciences, Banaras Hindu University, Varanasi, Uttar Pradesh, India



## ARTICLE INFO

## Article history:

Received 06-02-2024

Accepted 08-05-2024

Available online 03-06-2024

## Keywords:

Analgesia

Cervical plexus block

Subdural hematoma

Pain

## ABSTRACT

**Background:** Alternatives to general anesthesia technique, pain management of surgical sites have been discussed at length in various studies for burr-hole evacuation in geriatric patients. This is the first study addressing the management of pain that occurs due to extreme contra-lateral side neck rotation to access the surgical site.

**Materials and Methods:** This trial was conducted (from January 2021 to January 2022) on 60 patients of age  $\geq 18$  years with ASA grade II/III undergoing unilateral burr hole craniotomy for evacuation of chronic subdural hematoma (CSDH) under scalp block. Group D (n=30) received 5 ml of 0.5% bupivacaine by ultrasound-guided superficial cervical plexus block (SCPB), and group P (n=30) received SCPB with placebo (normal saline). The primary outcome was the numerical rating pain score (NRS) pain score during neck movement in the postoperative period. Secondary objectives were muscle spasm assessed by the modified Ashworth scale (MAS), consumption dosage of rescue analgesia, modified Ramsay sedation score (MRSS), and hemodynamic parameters.

**Result:** NRS scores were significantly lower at 8 hours in the SCPB with drug (D) group compared to the SCPB with placebo group (p-value = 0.019). MAS were higher in group P compared to group D until 12 (<0.001). Consumption of rescue analgesia was higher in group P than group D (<0.001). MRSS was significantly higher in group D compared to group P throughout the intra-operative period (<0.001).

**Conclusion:** Preoperative superficial cervical plexus block decreases postoperative neck pain and facilitates neck rotation.

This is an Open Access (OA) journal, and articles are distributed under the terms of the [Creative Commons Attribution-NonCommercial-ShareAlike 4.0 License](https://creativecommons.org/licenses/by-nc-sa/4.0/), which allows others to remix, tweak, and build upon the work non-commercially, as long as appropriate credit is given and the new creations are licensed under the identical terms.

For reprints contact: [reprint@ipinnovative.com](mailto:reprint@ipinnovative.com)

## 1. Introduction

Chronic subdural hematoma (CSDH) is more common in the geriatric age group.<sup>1</sup> Patients in the geriatric age group suffer from co-existing systemic diseases, which make the administration of general anesthesia (GA) very challenging. Alternative anesthesia techniques like monitored anesthesia

care (MAC) with conscious sedation and local anesthesia have been explored in the past for the evacuation of CSDH through burr hole craniotomy, and it has been concluded that MAC can provide adequate sedation and analgesia.<sup>2</sup> Though MAC is a safer option compared to GA, this also requires the administration of multiple drugs like benzodiazepines, opioids, ondansetron, dexamethasone, non-steroidal anti-inflammatory drugs, etc., which brings us

\* Corresponding author.

E-mail address: [shukla.pragya0509@gmail.com](mailto:shukla.pragya0509@gmail.com) (P. Shukla).

back to the problem of co-existing systemic disease, which may get worsened. More than ever, simple infiltration of local anesthetics is not sufficient to provide anesthesia and analgesia for burr-hole craniotomy.

Regional anesthesia like scalp block with conscious sedation using dexmedetomidine can be a better alternative than infiltration of local anesthesia for burr-hole craniotomy. Scalp block manages the surgical site pain, but craniotomy also requires extreme head rotation to the contra-lateral side for the surgical access, which causes intra-operative discomfort and post-operative neck pain. This pain that occurs due to extreme neck rotation can lead to muscle spasm, limit the neck rotation, and increase the morbidity and hospital stay of the patient. Pain that occurs due to the position of the surgery requires management to provide better patient satisfaction. Systemic opioids, NSAIDs, and pain patches can be used to manage the pain, but in geriatric patients, it will add to the morbidity of the patients. Regional blocks like superficial cervical plexus block (SCPB) have never been explored for this purpose. SCPB blocks the branches of the third and fourth cervical nerves. The branches of the third and fourth cervical plexuses supply sensory innervations to the levator scapula muscle, which is involved in pain.

The primary aim of this study was to assess the effect of unilateral superficial cervical plexus block on managing neck pain as assessed by the numerical rating scale (NRS). The secondary objective are to assess muscle spasm using the modified Ashworth scale (MAS), consumption of analgesics, sedation status by modified Ramsay sedation score (MRSS), hemodynamic parameters, and adverse events.

## 2. Materials and Methods

This study was registered with the Clinical Trial Registry India with CTRI No. CTRI/2021/01/030405, after institutional ethical board review. This was a randomized, double-blind, prospective, placebo-controlled trial that was conducted from January 2021 to July 2022.

The sample size was calculated based on  $\alpha = 0.05$ , and  $\beta = 0.20$ , with the help of a sealed envelope sample size calculator, including a minimum expected difference of 30% so that the results would be statistically significant. The total number of patients was distributed into two groups, each consisting of 30 patients. It was carried out on 60 patients older than 18 years. Both male and female patients were included in the study (Figure 1).

Apart from age, other inclusion criteria were unilateral chronic subdural hematoma posted for burr-hole craniotomy, a normal radiograph of the shoulders, and a cervical spine. Exclusion criteria for the study were: patients with a history of neck and shoulder pain radiating to the arm, radiculopathy, malignancy, hypothyroidism, myopathy, a high level of creatine phosphokinase, fibromyalgia,

duration of surgery greater than 2 hours, coagulopathy, history of allergy to local anesthesia, and history of autoimmune disease associated with subclinical myopathy. Written informed consent was obtained from all the patients before they were included in the study. On confirming the eligibility criteria, randomization was done using computer-generated random number tables. Patients were explained about the operative procedure and technique of anesthesia.

Group allocation was done using the sealed envelope technique, and patients were divided into two groups with 30 patients in each group. Scalp block was given to both groups. In group D (drug): superficial cervical plexus block with 5 ml of 0.5% bupivacaine plus 1 ml of dexmedetomidine (50  $\mu\text{g}/\text{ml}$ ) mixed in a single syringe. In group P (placebo): superficial cervical plexus block with 5 ml of normal saline.

On the day of surgery, after attaching standard monitors (electrocardiogram, non-invasive BP, and pulse-oximeter). Injection (inj.) of ondansetron 0.1 milligram per kilogram (mg/kg), inj. fentanyl 1 microgram ( $\mu\text{g}$ ) per kg, and inj. midazolam 0.03 mg/kg of body weight were given to the patients. In groups D and P, scalp blocks were given with a local anesthetic mixture of 6 ml of lignocaine 2% with adrenaline (1:200,000) and 6 ml of bupivacaine 0.5%. Scalp block was given to block the following scalp nerves: supra-trochlear, supraorbital, zygomatico-temporal, auriculotemporal, greater auricular, lesser occipital, and greater occipital—unilaterally. In group D, a superficial cervical plexus block was given under all aseptic precautions on the ipsilateral side of the scalp under ultrasound guidance.

A linear probe was selected, and this probe was placed at the midpoint of the attachment line between the mastoid process and the insertion of the head of the sternocleidomastoid muscle (SCM) at the sternal head. The probe was placed in the transverse plane. The goal was to guide the needle tip from a lateral to medial direction just under the tapering postero-lateral edge of the SCM to the facial plane under the SCM and just above the levator scapulae muscle. After placement of the needle, aspiration was done if no blood was spotted on aspiration; 5 ml of 0.5% bupivacaine plus 1 ml of injection dexmedetomidine (50  $\mu\text{g}/\text{ml}$ ) was injected into the plane between the sternocleidomastoid and levator scapulae muscles (Figures 2 and 3). In group P, 5 ml of normal saline was used for the superficial cervical block along with the unilateral scalp block.

Continuous intravenous infusion of injection dexmedetomidine (50  $\mu\text{g}/\text{ml}$ ) 0.5  $\mu\text{g}/\text{kg}$  was given during the intra-operative period in both groups with a dosage of 0.5  $\mu\text{g}/\text{kg}$ . All the blocks were performed by an expert anesthesiologist who was not participating in the study. The baseline characteristics, such as heart rate and

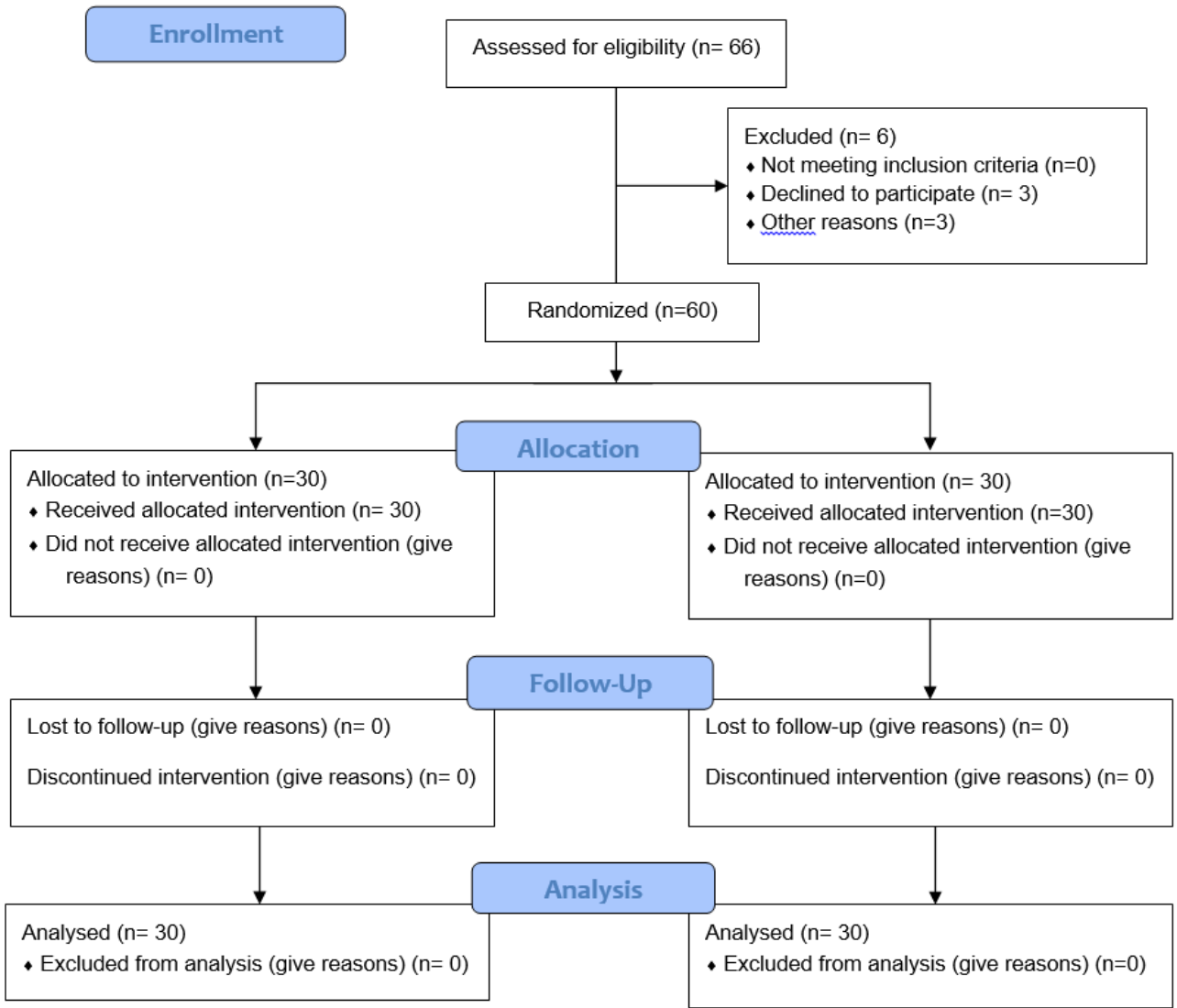


Figure 1: Study consort flow- from enrolment to assessment

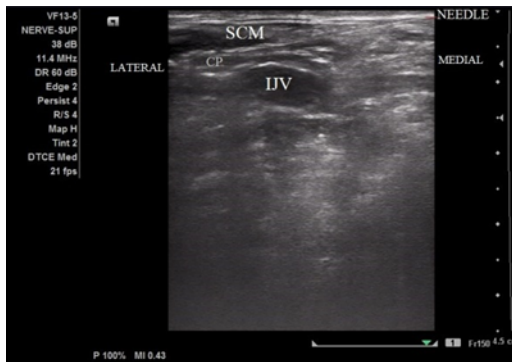

Figure 2: Superficial cervical block with needle

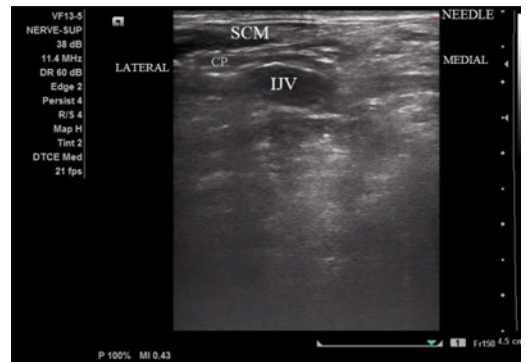

Figure 3: Superficial cervical plexus block after drug placement

mean arterial pressure, were recorded and repeated every 2.5 minutes for the first five minutes, every 5 minutes until the end of surgery, and post-operatively every 15 minutes. Intra-operative vitals and complications were observed. Sedation score (Table 1) was recorded every 10-minute interval for the first 30 minutes and then every 15-minute interval until the completion of the surgery.

**Table 1:** Modified Ramsay sedation score (MRSS)

Value	Description (level of sedation)
1	Awake: patient is anxious and agitated, or restless, or both.
2	Awake: patient is co-operative, oriented, and tranquil.
3	Awake: patient responds to commands only.
4	Asleep: patient reacts with a brisk response to a light glabellar tap or a loud auditory stimulus.
5	Asleep: patient reacts with a sluggish response to a light glabellar tap or a loud auditory stimulus.
6	Asleep: patient does not respond to pain.

Postoperatively, Numerical rating scores were recorded with neck movement. For neck movement, patients were asked to rotate the neck in flexion, extension, ipsilateral rotation, and contralateral rotation every 1, 2, 4, 6, 8, 12, and 24 hours of the surgery, and observations for NRS were made as 0-3 (mild), 4-7 (moderate), and 8-10 (high). To measure the incidence of muscle spasm, modified Ashworth scale score was used (Table 2). Injection Paracetamol injections were given for rescue analgesia after the assessment of patients according to the NRS score.

**Table 2:** Modified Ashworth Score (MAS)

Score labeled for the study	Original score	Description
0	0	No increase in muscle tone
1	1	Slight increase in muscle tone, with a catch and release or minimal resistance at the end of the range of motion when an affected part(s) is moved in flexion or extension
2	1+	Slight increase in muscle tone, manifested as a catch, followed by minimal resistance through the remainder (less than half) of the range of motion.
3	2	Marked increases in muscle tone throughout most of the range of motion, but affected part (s) are still easily moved.
4	3	Considerable increase in muscle tone, passive movement difficult.
5	4	Affected part(s) rigid in flexion or extension.

## 2.1. Statistical analysis

No previous such study was available, so a pilot study was performed with the hypothesis that there would be pain relief in at least 80% of the patients in the drug group with a 5% level of significance and 90% power. The data analysis was done using SPSS (Statistical Package of Social Sciences) version 23.0. Categorical descriptive data was expressed as a number and percentage, and continuous descriptive data was expressed as the mean  $\pm$  standard deviation (SD). A chi-square test was used for the analysis of categorical data. Normally distributed variables were analyzed using the Student's T-test, while continuous variables that were not normally distributed were analyzed using the non-parametric Mann-Whitney U-test. A value of  $p$ -value  $< 0.05$  was considered to be statistically significant.

## 3. Results

The patient's demographic profile was similar in group SCPB with drug (D) and in group SCPB with placebo (P) (Table 3). Mean Numerical Rating Scale pain scores (Table 4) were significantly less in D group (SCPB with drug) as compared to P group (SCPB with placebo) at 1hr ( $2.47 \pm 0.507$  vs  $2.90 \pm 0.305$ ), 2hr ( $2.70 \pm 0.466$  vs  $3.20 \pm 0.407$ ), 4 hr ( $3.32 \pm 0.540$  vs  $3.72 \pm 0.622$ ), 6 hr ( $3.62 \pm 0.542$  vs  $3.92 \pm 0.607$ ), 8 hr ( $3.94 \pm 0.640$  vs  $4.36 \pm 0.707$ ) and 12hr ( $4.25 \pm 0.642$  vs  $4.47 \pm 0.507$ ) postoperatively and 24 hrs ( $5.02 \pm 0.606$  vs  $5.17 \pm 0.747$ ) the difference in pain score was statically significant till 8 hours (0.019) stating that pain relief was better in group D compared group P.

Modified Ramsay sedation scores (Table 5) were higher in group D, drug in superficial cervical plexus block, compared to group P, placebo in superficial cervical plexus block, throughout the intra-operative period, and this difference in sedation score was statistically significant with a  $p$  value less than 0.001 from the beginning of surgery to the end of surgery.

Total analgesic consumption was higher in group P (290 mg) compared to group D (226.67), and this difference in the total dose of injection Paracetamol was statistically significant with a  $p$ -value  $< 0.001$  (Figure 4).

The modified Ashworth score (Table 6) was calculated in the postoperative period at the 1st, 2nd, 4th, 12th and 24th hour. In group D, it was 0 at 1st, 2nd and 4th hour and 1 at 12th and 24th hour whereas in group P it was 3 at 1st, 2nd, and 4th hour, 2 at 12th hour and 1 at 24th hour. Scores were labeled as 0, 1, 2, 3, 4, and 5.

## 4. Discussion

In clinical trials investigating pain, the emphasis is always on surgical site pain. It is the first ever randomized control trial, highlighting the need for the management of pain that occurs due to the position that has to be obtained for access to the surgical site for surgery rather than surgical pain in

**Table 3:** Demographic parameter, ASA grading and GCS in Group D and Group P

Parameter	Group D	Group P	p-value
Age (years)	69.63±9.583	69.10±9.604	0.830
Weight (kilograms)	72.27±7.139	70.43±8.295	0.363
Height (centimetre)	166.57±8.791	165.43±9.776	0.639
ASA grading	16	17	>0.05
Preoperative GCS	15	15	>0.05

Data for age, weight and height expressed as mean ± standard deviation. Data for ASA grading and GCS was expressed as percentage. SD: Standard deviation, ASA: American society of anaesthesiology, GCS: Glasgow coma scale, D: Drug group, P: Placebo group.

**Table 4:** Post-operative comparison of Mean Numerical rating scale (NRS) pain scores at different time intervals

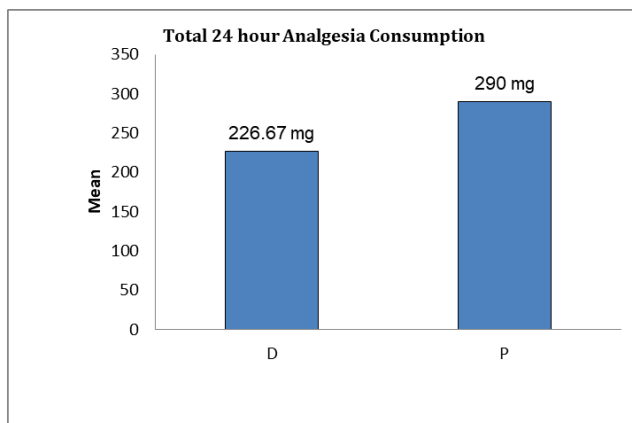
NRS (hours)	Group D (n=30)	Group P (n=30)	p-value
1	2.47±0.507	2.90±0.305	<0.001
2	2.70±0.466	3.20±0.407	<0.001
4	3.32±0.540	3.72±0.622	0.0081
6	3.62± 0.542	3.92±0.607	0.0477
8	3.94 ± 0.640	4.36±0.707	0.019
12	4.25±0.642	4.47±0.507	0.1454
24	5.02±0.606	5.17±0.747	0.3965

Data for mean numerical rating scale pain scores was expressed as mean ± standard deviation. NRS: Numerical rating scale, SD: Standard deviation, D: Drug group, P: Placebo group

**Table 6:** Comparison of Modified Ashworth scoring (MAS) in Group D and Group P

Time interval (hours)	Group D (n=30)	Group P (n=30)	p-value
1	0	3	<0.001
2	0	3	<0.001
4	0	3	<0.001
12	1	2	<0.001
24	1	1	0.833

Values expressed as median and statistical test used to compare group was Mann Whitney U test. D: Drug group, P: Placebo group

**Figure 4:** Comparison of total analgesic consumption over 24 hours in Group D and Group P**Table 5:** Comparison of Modified Ramsay sedation score in Group D and Group P

MRSS (minutes)	Group D (n=30)	Group P (n=30)	p-value
10	4	3	<0.001
20	4	3	<0.001
30	5	3	<0.001
45	5	4	<0.001
60	4	4	<0.001
75	4	3	<0.001
90	4	3	<0.001
105	4	3	<0.001
120	4	3	<0.001

Values expressed as median for Modified Ramsay sedation score. D: Drug group, P: Placebo group.

itself. In this RCT, a superficial cervical plexus block has been used to address the pain that occurs due to extreme neck rotation for burr-hole craniotomy.

In recent years conscious sedation using monitored anaesthesia care has been employed along with local anaesthesia in particular for patients undergoing surgical or

diagnostic procedures for which general anaesthesia carries a high risk.<sup>3–8</sup> Chronic subdural hematoma usually occurs in the geriatric population.<sup>1</sup> Evacuation for chronic subdural hematoma is done under scalp block to avoid complications that may occur due to general anesthesia in this patient population. Scalp blocks manage the surgical site pain, but muscular pain and spasm that occur due to extreme neck

rotation remain unaddressed.

Managing pain in the geriatric population can be challenging, as this population is vulnerable to complications due to age-related physiological changes, which can be worsened by systemic NSAIDs and opioids adding to the morbidity. Regional anesthesia techniques can address these issues. Ultrasound-guided superficial cervical plexus block can prevent the intra-operative pain and discomfort of the patient as well as provide postoperative analgesia.

In our study, superficial cervical plexus block effectively controlled pain. Pain scores were measured using the NRS. Mean numerical rating scale pain scores were significantly lower in the D group as compared to the P group at 1hr ( $2.47 \pm 0.507$  vs  $2.90 \pm 0.305$ ), 2hr ( $2.70 \pm 0.466$  vs  $3.20 \pm 0.407$ ), 4hr ( $3.32 \pm 0.540$  vs  $3.72 \pm 0.622$ ), 6 hr ( $3.62 \pm 0.542$  vs  $3.92 \pm 0.607$ ), and 8 hr ( $3.94 \pm 0.640$  vs  $4.36 \pm 0.707$ ) post operatively. This difference in pain scores was significant up to 12 hours, stating that pain was managed more effectively in group D compared to group P. A superficial cervical plexus block also reduced the requirement for rescue analgesia in group D ( $226.67 \pm 73.968$ ), which was higher in group P ( $290.00 \pm 30.513$ ).

The sternocleidomastoid muscle (SCM) rotates the head to the opposite side; it is innervated by the accessory nerve of the same side, which supplies the motor part. SCM receives its sensory input from the ventral primary rami of C2 and C3.<sup>2</sup> The superficial cervical plexus can block sensory innervation, effectively providing analgesia. USG-guided SCPB increases the safety of needle placement, and a larger volume of local anesthetics can safely be given for the blockade. SCPB has been used to address the issue of myofascial pain. In an ongoing trial, the role of bilateral superficial cervical plexus block has been explored to assess the recovery following anterior cervical spine surgery (ACSS) (ACTRN126190000281010).<sup>9</sup>

In existing literature, SCPB has been used for a variety of surgical procedures. Deepika et al. conducted a RCT on 30 patients undergoing modified radical mastoidectomy. In this study, superficial cervical plexus block was used for postoperative pain relief, and they concluded that superficial plexus block reduced the VAS scores.<sup>10</sup> The result of our study is similar to the mentioned study, but our study is different as it was not done for surgical site pain but for the pain that occurs due to surgical positioning.

A randomized control trial done by Syal et al. explored the difference in the efficacy of intermediate and subcutaneous cervical plexus block in 45 patients undergoing total thyroidectomy and concluded that ultrasound-guided intermediate CPB reduces post-operative pain scores, prolongs the duration of analgesia, and decreases demands for rescue analgesia compared to superficial CPB.<sup>11</sup> In contrast, this study done by

Ramchandran and colleagues for patients undergoing carotid endarterectomy found similar efficacy for superficial and intermediate CPB.<sup>12</sup>

A prospective cohort study done by Woldegerima et al. assessed the effect of bilateral superficial cervical plexus block for pain relief in thyroid surgery under general anesthesia on 74 patients and concluded that NRS-11 scores for pain were significantly lower in the block group.<sup>13</sup>

Parathyroidectomy has been done under superficial cervical plexus block in a patient with severe kyphoscoliosis.<sup>14</sup> Ultrasound-guided selective cervical nerve root block along with superficial cervical plexus block have been used for surgeries on the clavicle.<sup>15</sup>

Till now, there is no study done to analyse the effect of superficial cervical plexus block for postoperative neck pain and rigidity due to surgical positioning of neck for long time.

However, the present study had certain limitations also. It was conducted on a smaller number of patients. Therefore, its usefulness can be further confirmed by a randomized double-blind control trial on a larger sample size of patients.

## 5. Conclusion

In this study demonstrates that Preoperative superficial cervical plexus block decreases the neck pain and facilitates neck rotation in postoperative period. It also decreases the analgesic requirement in the post-operative period. This study adds to the body of evidence supporting the safe use of superficial blocks for this type of surgery.

## 6. Source of Funding

None.

## 7. Conflict of Interest

None.

## References

- Adhiyaman V, Asghar M, Ganeshram K, Bhowmick B. Chronic subdural haematoma in the elderly. *Postgrad Med J.* 2002;78(916):71–5.
- Naja AS, Madi N, Tfayli Y, Ziade F, Haber G, Kanawati S, et al. Deep Cervical Plexus Block for Neck and Shoulder Pain Due to Myofascial Pain. *Clin J Pain.* 2022;37(2):133–9.
- Alhashemi JA. Dexmedetomidine vs midazolam for monitored anaesthesia care during cataract surgery. *Br J Anaesth.* 2006;96(6):722–6.
- Jonghe BD, Cook D, Appere-De-Vecchi C, Guyatt G, Meade M, Outin H. Using and understanding sedation scoring systems: a systematic review. *Intensive Care Med.* 2000;26(3):275–85.
- Ernestus RI, Beldzinski P, Lanfermann H, Klug N. Chronic subdural hematoma: surgical treatment and outcome in 104 patients. *Surg Neurol.* 1997;48(3):220–5.
- Manninen PH, Balki M, Lukitto K, Bernstein M. Patient satisfaction with awake craniotomy for tumor surgery: a comparison of remifentanyl and fentanyl in conjunction with propofol. *Anesth Analg.* 2006;102(1):237–42.

7. Savoia G, Loreto M, Gravino E, Canfora G, Frangiosa A, Cortesano P, et al. Monitored anesthesia care and loco-regional anesthesia. *Minerva Anesthesiol.* 2005;71(9):539–42.
8. Stefanutto T, Ruttman T. Conscious sedation v. monitored anesthesia care - 20 years in the South African context. *S Afr Med J.* 2006;96(12):1252–4.
9. Mulcahy MJ, Elalingam T, Jang K, D'Souza M, Tait M. Bilateral cervical plexus block for anterior cervical spine surgery: study protocol for a randomised placebo-controlled trial. *Trials.* 2021;22(1). doi:10.1186/s13063-021-05377-4.
10. Deepika V, Ahuja V, Thapa D, Gombar S, Gupta N. Evaluation of analgesic efficacy of superficial cervical plexus block in patients undergoing modified radical mastoidectomy: A randomised controlled trial. *Indian J Anaesth.* 2021;65(Suppl 3):S115–20.
11. Syal K, Chandel A, Goyal A, Sharma A. Comparison of ultrasound-guided intermediate vs subcutaneous cervical plexus block for postoperative analgesia in patients undergoing total thyroidectomy: A randomised double-blind trial. *Indian J Anaesth.* 2020;64(1):37–42.
12. Ramachandran SK, Picton P, Shanks A, Dorje P, Pandit JJ. Comparison of intermediate vs subcutaneous cervical plexus block for carotid endarterectomy. *Br J Anaesth.* 2011;107(2):157–63.
13. Woldegerima YB, Hailekiros AG, Fitiwi GL. The analgesic efficacy of bilateral superficial cervical plexus block for thyroid surgery under general anesthesia: a prospective cohort study. *BMC Res Notes.* 2020;13:42.
14. Lee KH, Jeon SY. Parathyroidectomy under superficial cervical plexus block in a patient with severe kyphoscoliosis. *Indian J Anaesth.* 2014;58(3):355–6.
15. Shanthanna H. Ultrasound guided selective cervical nerve root block and superficial cervical plexus block for surgeries on the clavicle. *Indian J Anaesth.* 2014;58(3):327–9.

### Author biography

**Shekhar Anand**, Assistant Professor  <https://orcid.org/0000-0002-9042-8822>

**Pragya Shukla**, Assistant Professor  <https://orcid.org/0000-0003-2904-750X>

**Kavita Meena**, Associate Professor

**Rajesh Meena**, Associate Professor  <https://orcid.org/0000-0002-7803-7976>

**Cite this article:** Anand S, Shukla P, Meena K, Meena R. Efficacy of superficial cervical plexus block in the management of neck pain due to surgical positioning in patients undergoing burr-hole craniotomy for unilateral chronic subdural hematoma under scalp block: A prospective randomized control trial. *Indian J Clin Anaesth* 2024;11(2):152-158.