



Original Research Article

Perioperative management of patients with post Covid rhino-orbito-cerebral mucormycosis: Prospective observational study

Devyani Desai¹, Neha Shah¹, Neha Cheraya¹, Bhoomika Kalarthi^{1,*}, Sagar Baviseti¹, Parvathy D¹, Abhishek Zala¹, Kanchan Choube¹, Gaurav Cheraya²

¹Dept. of Anaesthesiology, Government Medical College, SSG Hospital, Vadodara, Gujarat, India

²Unipath Spl. Laboratory, Vadodara, Gujarat, India



ARTICLE INFO

Article history:

Received 06-12-2021

Accepted 04-04-2022

Available online 22-04-2022

Keywords:

COVID- 19

Delayed recovery

Difficult intubation

Rhino-orbito-cerebral mucormycosis

ABSTRACT

Background: Mucormycosis is a life-threatening, locally invasive, rapidly progressive, opportunistic fungal infection, associated with several anaesthetic challenges.

Aims: We aimed to study its relation with patient's comorbidities, covid treatment strategies, also to observe the intubation difficulties, changes in hemodynamic parameters, post anaesthesia recovery status and perioperative complications.

Materials and Methods: In this time bound study, total 160 patients were included. During pre-anaesthetic evaluation, presence of associated co-morbidities, course of Covid-19 disease, requirement of O₂ therapy were noted. On the day of surgery, premedications and sedation were given. Induction was done with propofol/etomidate along with sevoflurane/desflurane. Intubation was done with succinyl choline/ atracurium and difficulties in intubation were graded according to Modified Intubation Difficulty Scale. Anaesthesia was maintained with the mixture of Oxygen, Air and inhalation agent along with intermittent Atracurium. Hemodynamic parameters, intra operative and post operative outcome were noted. Unstable patients were shifted to intensive care unit.

Results: Among patients of rhino-orbito-cerebral mucormycosis, most common co morbidity found was diabetes mellitus (42%). Here, 61% were on room air, rest needed oxygen therapy. Total 52% patients required ≥ 2 intubation attempts, in which 9% were video laryngoscope assisted and 11% required additional maneuvers. 22% patients were started on intravenous nitroglycerin to manage intraoperative hypertension. 9.3% patients required ICU admission, of which 2.5% could not survive.

Conclusion: Possibilities of developing rhino-orbito-cerebral mucormycosis in patients having diabetes mellitus are high. The anaesthetic management requires eternal vigilance to encounter difficult intubation, delayed recovery, and higher rate of morbidity and mortality.

This is an Open Access (OA) journal, and articles are distributed under the terms of the [Creative Commons Attribution-NonCommercial-ShareAlike 4.0 License](https://creativecommons.org/licenses/by-nc-sa/4.0/), which allows others to remix, tweak, and build upon the work non-commercially, as long as appropriate credit is given and the new creations are licensed under the identical terms.

For reprints contact: reprint@ipinnovative.com

1. Introduction

Mucormycosis is a rare but lethal fungal infection, mostly occurring in immunocompromised patients. It is characterized by extensive angioinvasion that results in vessel thrombosis and subsequent necrosis, seen clinically as rhino-cerebral, gastrointestinal, pulmonary

and disseminated, burns wound, central nervous system, endocarditis, and vascular mucor mycosis.

Pre-existing diseases, such as diabetes mellitus, respiratory pathology, use of immunosuppressive therapy, hospital-acquired infections, and systemic immune alterations of Covid-19 disease are increasingly being recognized in view of their impact on morbidity and mortality.¹ We have seen steady rise in cases of

* Corresponding author.

E-mail address: bhoomikalarthi099@gmail.com (B. Kalarthi).

mucormycosis in patients with active SARS Cov-2 infection and in those who have recovered from Covid-19 disease.

Successful treatment of mucormycosis is dependent on four key principles: early diagnosis, treatment of underlying predisposing factors, surgical debridement of necrotic tissue, and administration of systemic Amphotericin B.² Amphotericin B acts by binding to ergosterol of the cell membrane of susceptible fungi, forming transmembrane channels leading to alterations in cell permeability. Hypokalemia, hypomagnesemia, fever, chills, dyspnoea, hypotension, allergic reactions, seizures, anaemia, and thrombocytopenia are reported side effects of Amphotericin B. Renal function is impaired in >80% of treated patients.³

The resultant vascular thrombosis prevents Amphotericin B from reaching the infected tissue. Therefore, the primary aim of surgical intervention is to debride all the necrotic tissues. On the other hand, drainage of paranasal sinuses and orbital exenteration can be lifesaving in the presence of active fungal infection.⁴

Surgical intervention in these patients is a challenge for the anaesthesiologist with possibilities of difficult airway management in the form of difficult mask ventilation and endotracheal intubation. We undertook this study to observe the challenging factors in perioperative anaesthetic management of rhino-orbito-cerebral mucormycosis at our centre, during second wave of Covid-19 disease. We tried to study the relationship of mucormycosis with comorbidities and covid treatment strategies like O₂ therapy or steroids as well as intubation difficulties, perioperative hemodynamic parameters, post anaesthesia recovery status and any undue complications.

2. Materials and Methods

After getting institutional ethical committee approval, this prospective observational study was held at our institute from June 2021 till we could get the cases of mucormycosis which required surgical intervention. This made us to include 160 cases in this study. Patients between age group 18-70 years of either sex with American Society of Anaesthesiologists (ASA) physical status I to IV with previous history of Covid-19 (confirmed with RT-PCR) and having confirmed diagnosis of rhino-orbito-cerebral mucormycosis on biopsy were included. Written, informed consent was taken and patients were thoroughly counselled and explained about the procedure and purpose of the study. Preoperatively patients were evaluated for any major illness like diabetes mellitus (DM), hypertension (HT), obesity, ischemic heart disease (IHD), solid organ or haematological malignancy, any other immunocompromised state, chronic respiratory disease, thyroid disease etc. And presence of any associated co-morbidities were noted down. The course and the therapy involved in the management of Covid-19 disease was documented with respect to; a) O₂ therapy (amount,

duration and different forms such as non-rebreathing mask (NRBM), non-invasive ventilatory therapy viz bi-level positive pressure ventilation (BIPAP) or high frequency nasal oxygenation (HFNO) or invasive ventilation), b) use of steroids, c) antiviral agents like Remdesivir and d) anticoagulants. Preoperatively, investigations like complete blood count, random blood sugar, renal function tests, liver function tests, serum electrolytes, chest X-ray and electrocardiogram (ECG) were checked and 2D echocardiography was done when indicated. Airway was assessed by mouth opening and mallampati grading. Blood sugar and serum K⁺ were optimized according to the requirement. If baseline oxygen saturation was <95%, required quantity of O₂ was provided through nasal prongs/face mask/ NRBM.

All the patients were kept nil per orally for 6 hours prior to operation. After arrival in the operation theatre, a good intravenous access with 18 g canula was secured. Airway instruments were checked and a difficult airway cart was kept ready. Multipara monitor was attached and baseline vital parameters such as pulse rate, mean arterial pressure, SpO₂ were noted. All patients were administered premixed infusion of paracetamol 1gm + lignocaine 1mg/kg + magnesium sulphate 1gm intravenously 15 minutes before induction and additionally premedicated with intravenous ondansetron 0.15mg/kg, glycopyrrolate 5mcg/kg, pantoprazole 40mg and fentanyl 1mg/kg 5 minutes prior to induction.

Patients were preoxygenated with 100% O₂ for 3 minutes with closed circuit using Drager GS Premium /Fabius Plus anaesthesia machine. Induction of anaesthesia was provided with intravenous propofol till loss of airway reflexes and after check ventilation, suxamethonium chloride 2 mg/kg was administered. After disappearance of fasciculations, patient was intubated with conventional laryngoscope or video laryngoscope if any difficulty in intubation was anticipated, and first effective ventilation was confirmed by capnography. If required to assist the intubation, either bougie and/or the maneuvers like external laryngeal pressure were used. Difficult intubation was graded according to Modified Intubation Difficulty Scale (MIDS). The score is derived from seven variables as follows-

N1 represents the number of additional intubation attempts; the score is 0 for a first attempt.

N2 represents the number of additional operators; the score is 0 if there is a successful intubation by the first operator.

N3 is the number of alternative intubation techniques used; the score is 0 if there is no alternative intubation technique, but each alternative intubation technique utilized, adds one point.

N4 represents the laryngoscopic view, as defined by Cormack and Lehane: grade 1 = score 0, grade 2 = score

1, grade 3 = score 2, and grade 4 = score 3.

N5 is the lifting force applied during laryngoscopy: score 0 if there is a normal lifting force, and score 1 if the force is considerable.

N6 relates to the necessity to apply external laryngeal pressure to optimize glottic exposure: score 0 if there is no external pressure or only the Sellick maneuver is applied, and score 1 if external laryngeal pressure is used.

N7 refers to vocal cord mobility: score 0 if they are abducted, and score 1 if they are adducted or not visible.

The IDS score is the sum of N1 through N7. The total IDS score ranges from zero to infinity.

MIDS Score	Degree of difficulty
0	Easy
$0 < \text{MIDS} \leq 5$	Slight Difficulty
$5 < \text{MIDS}$	Moderate to Major Difficulty
$\text{MIDS} = \infty$	Impossible intubation

Peri laryngeal packing was done with the sterile roller pack.

Intraoperatively, lung protective ventilation strategy applied utilizing pressure control mode of ventilation. The aim was to keep delivered tidal volume to be less than 6ml/kg and plateau pressure not to exceed 30 cm of H₂O. Intraoperatively, anaesthesia was maintained with a 50:50 mixture of oxygen and air along with inhalation agent (Desflurane/Sevoflurane) and intermittent use of atracurium besylate. SpO₂, pulse rate, mean arterial pressure (MAP), ECG were monitored throughout the procedure. Fluids and blood were replaced as per requirement. Anaesthetic agent and air were stopped 10 mins and 5 minutes before the end of procedure, and patient was ventilated with 100% oxygen. Reversal of residual neuromuscular block was achieved using neostigmine and glycopyrrolate. During this period patient was ventilated with 100% oxygen with fresh gas flow of 4-6 litres/min. Patient was extubated on establishing regular spontaneous breathing pattern, and was able to open eyes to command. Total duration of surgery and anaesthesia was noted. Perioperative complications like desaturation (SpO₂<95%) bronchospasm, oropharyngeal trauma, aspiration, arrhythmia, hypercarbia, or delayed recovery were noted and treated accordingly.

Postoperatively, all patients were shifted to post anaesthesia care unit (PACU). Modified Aldrete score was observed in all and patients were shifted to ward once they achieved score of >9. Patients who were having altered consciousness, hemodynamic instability, respiratory distress and/or SpO₂<90%, were shifted to intensive care unit (ICU) and provided ventilatory support. All patients were followed till their final outcome which was discharge or death.

The data was compiled and master charts were prepared in Microsoft Excel. Descriptive statistical values were expressed as mean ± SD (standard deviation) and

categorical data was represented as frequency/percentage. Student 't' test for quantitative data and Chi square test for the qualitative data were applied using Med Calc software (version 12.4.3.0) with p value <0.05 being considered significant.

3. Observation and Results

The study included total 160 patients with 78% nearly three quarters of them being males, with median age of 50 years (range; 27-80 years) and median body weight was 60 kg (range; 35-100 kg). Majority of the patients (n=76) were ASA physical status III. (Table 1)

Most common co morbidity was diabetes mellitus 42% (n=67), followed by DM +HT 18% (n=30). Others were having only hypertension 5% (n=8), IHD 3% (n=5), chronic respiratory disease 2.5% (n=4), obesity 2.5% (n=4), immune compromised status 3% (malignancy-3, myasthenia gravis-1, renal transplant-1) and thyroid disease 9% (n=15). (Table 1)

Most of the patients 61% (n=97) were on room air, while 21% (n=35) were on NRBM, 13% (n=20) were on nasal prongs and 5% (n=8) required NIV during hospital stay. 80% patients (n=128) received corticosteroid treatment for Covid-19 during their hospital stay. (Table 1)

Rhino-facial and rhino-orbital mucormycosis were the common presentation amongst all with 46% patients (n=74) and 41% patients (n=66) affected respectively. While, remaining patients had palatal, dental and/or cerebral involvements. (Table 1)

48% patients (n=77) were intubated at first attempt using direct laryngoscope. 9% patients (n=14) required video-laryngoscope for intubation. 11% (n=18) required additional manoeuvres like external laryngeal pressure or use of bougie. (Table 1)

Post-operative delayed recovery was observed in 9.3% patients (n=15) and required ICU admission. 5% patients (n=9) required post-operative ventilator support, out of them, 2.5% patients (n=4) did not survive. Median of post-operative modified aldrete score was 6 (4-10). (Table 1)

3.1. Haemodynamic parameters

Peri operatively, pulse rate, mean arterial pressure and spo₂ were recorded periodically. Mean pulse rate and mean arterial pressure were maintained throughout the surgery. (Figure 1) 22% patients (n=35) developed intraoperative hypertension which was managed by nitro-glycerine infusion. Contrast to that, 2% of patients required ionotropic support to manage intra operative hypotension.

3.2. Peri operative complications

Desaturation, oropharyngeal trauma, arrhythmia, delayed recovery were observed in 15 (9%), 5 (3%), 10 (6%), 6 (3.75%) and 15 (9.3%) patients respectively. (Figure 2)

Table 1: Demographic data

S.No.	Variable	Patients N=160	Percentage %
1	Age (years)	50 (27-80)	
2	Gender, (male/ female)	124/36	78%/ 22%
3	Weight, kg	60 (40-120)	
4	ASA Grading, II/ III/ IV	59/76/25	37% /48% /15%
5	Co morbidity		
	Diabetes mellitus (DM)	67	42%
	Hypertension (HT)	8	5%
	DM+HT	30	18%
	Obesity	4	2.5%
	IHD	5	3.12%
	Chronic respiratory disease	4	2.5%
	Immuno compromised status (Myasthenia gravis/ malignancy/ renal transplant	5 (1/3/1)	3.12%
	Thyroid disease	15	9%
	No co morbidity	22	13%
6	Covid treatment strategy		
	Room air	97	61%
	Nasal prongs	20	13%
	NRBM	35	21%
	NIV	8	5%
7	Steroids	128	80%
8	Involvement		
	Rhino facial	74	46%
	Rhino orbital	66	41%
	Rhino facio palatal	2	1.25%
	Rhino orbito cerebral	3	2%
	Ocular	8	5%
	Intra cerebral	3	2%
	Dental	4	2.5
9	Mallampati grading (I / II / III / IV)	20/ 90/ 48/2	
10	MIDS Score		
	0	77	48%
	1	30	19%
	2	16	10%
	3	5	3%
	4 - video laryngoscopy	10	6.25%
	5 - video laryngoscopy	4	2.5%
	Bougie guided intubation	10	6.25%
	External laryngeal pressure	8	5%
11	Duration of surgery (hours)	3 (2-7)	
12	Post-operative recovery		
	Delayed recovery	15	9.3%
	Ventilator support	9	5%
13	Modified Aldrete score	6 (4-10)	
14	ICU Stay	15	9.3%
15	Mortality	4	2.5%

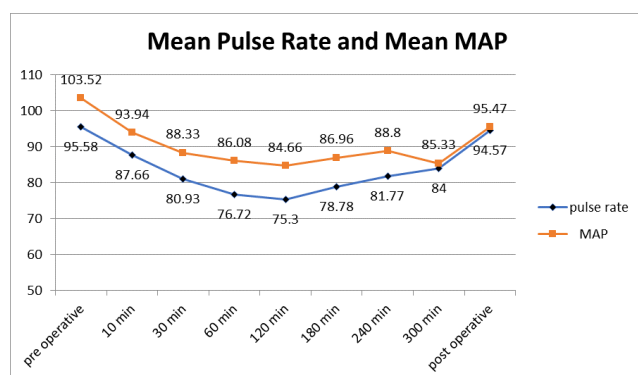


Fig. 1: Peri operative pulse rate and mean arterial pressure (MAP)

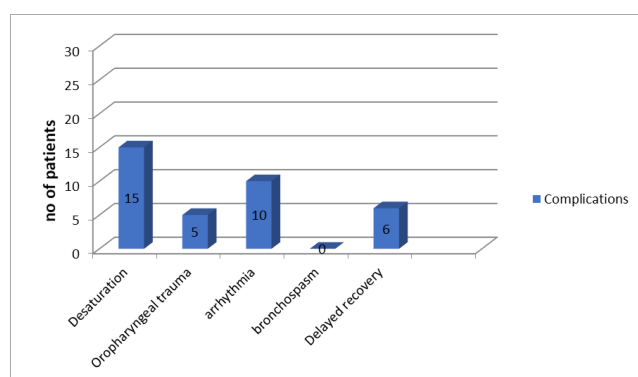


Fig. 2: Peri operative complications

4. Discussion

Mucormycosis is one of the most lethal, continuous, angio-invasive fungal infections having mortality of 70-100%. In our study male patients (78%) were affected more than female patients (22%) with median age of 50 years and median weight of 60 kg.

Mucormycosis typically occurs in patients with multiple co morbidities like diabetes mellitus, hypertension, IHD, obesity, organ transplantation, immune-compromised status, chronic respiratory disease, malignancy. We found majority of patients had DM (60%) among all other co morbidities, while 22% patients were healthy before having Covid-19. The high association of mucormycosis in diabetes mellitus may be due to the innate active ketone reductase system present in *Rhizopus* species which helps it to thrive in high glucose, acidotic environment. Also, there is increased availability of serum iron, decreased phagocytic and chemotactic activity of neutrophils in these conditions.⁵

Mucormycosis is most frequently located in para nasal sinuses (39%), followed by lungs (24%), skin (19%), brain (9%), gastro-intestinal tract (7%) and other organs (6%) of cases. The spores are inhaled into the naso-pharynx and tissue invasion, thrombosis and necrosis progresses

from the nose to the paranasal sinuses, orbit and central nervous system.⁶ Most common involvement in our study was rhino-orbito-facial followed by dental and intra cerebral mucormycosis.

Oxygen therapy was required in only 39% of the patients and majority (61%) patients were on room air during the course of Covid-19 infection.

The surgical procedure involves debridement, functional endoscopic sinus surgery, maxillectomy, mandibulectomy, exenteration, enucleation, palatal debridement, craniotomy for which general anaesthesia has to be administered.

The patients can have a difficult airway because of epiglottitis, sub and supra-glottic oedema, restricted mouth opening due to jaw erosion and pain, palatal ulcers which bleed on touch, palatal perforations, crusts in the nose, oroantral fistulas and DM induced joint stiffness. Facial swelling, proptosis and perioral wounds due to the use of tight fitting non-invasive ventilation masks during Covid treatment can hinder mask ventilation.^{2,7,8} In our study, difficulty in intubation was graded according to Modified Intubation Difficulty Scale (MIDS) and grading. 9% patients required video laryngoscope assisted intubation and 11% required different maneuvers.

In vitro studies have shown volatile anesthetic agents to possess antibacterial and antifungal activity.² Barodka et al reported that isoflurane inhibited the growth of *albicans*.⁹

However, there is little or no documentation on ideal intravenous and inhaled anesthetic agents in progressive active fungal infections. In our study, desflurane and sevoflurane were used.

The effects of Covid-19 and DM on multiple organ systems, along with the systemic effects (inclusive of decrease in renal function) of Amphotericin B and corticosteroid administration can result in serious perioperative complications. Sarkar et al. and Moorthy et al. found strong association of corticosteroid treatment with occurrence of rhino-orbito-cerebral mucormycosis in their studies.^{10,11} Injudicious use of corticosteroid and broad spectrum antibiotics to treat Covid-19, may be a predisposing factor leading to increase in incidence of fungal infection or exacerbation.¹² This might be one of the predisposing factors for mucormycosis in patients who were on room air or not having any co-morbidity during their course of treatment for Covid-19. Perioperative hypotension and arrhythmias due to Amphotericin B, post-Covid adrenal suppression and myocardial dysfunction, desaturation, bronchospasm, oropharyngeal trauma have been frequently reported. Maintaining adequate mean arterial pressure, cardiac output, normovolemia and avoiding further renal insults are of paramount importance. Electrolyte disturbances such as hypokalemia and hypomagnesemia due to Amphotericin B can interfere with neuromuscular blocking drugs, leading to delayed recovery. In our study, delayed recovery was observed in 9.3% cases and of which

5% ended up requiring post-operative ventilatory support.

Jeong et al. reported the serum creatinine level and thrombocytopenia are important factors affecting mortality in patients with mucormycosis.¹³ Spellberg et al. published a mortality rate of 70% in patients that received antifungal treatment alone as opposed to 14% that underwent antifungal and surgical treatment.¹⁴ Our patients underwent both medical and surgical treatment and mortality rate was 2.5%.

Our study was limited to a single centre with relatively small sample size. A large multi centric trial with more number of subjects maybe more relevant and would help corroborate our idea about the association of mucormycosis with Covid-19 disease.

5. Conclusion

Potentials of developing rhino-orbito-cerebral mucormycosis in patients having diabetes mellitus are more. The anesthesiologist must be vigilant while managing such cases as there are greater tendency for getting difficult intubation, delayed recovery, and higher rate of morbidity and mortality.

6. Source of Funding

Nil.

7. Conflict of Interest

None.

Acknowledgements

We want to acknowledge Dr. R G Aiyer, Superintendent and Head, Department of ENT, SSG hospital, Vadodara, for his constant support and DR. Swati Bhatt, Professor, Department of Anaesthesia, SSG hospital, Vadodara, for her help and guidance.

References

1. Mehta S, Pandey A. Rhino-Orbital Mucormycosis Associated With COVID-19. *Cureus*. 2020;12(9):e10726.
2. Karaaslan E. Anesthetic management of rhinoorbitocerebral mucormycosis; Focus on challenges. *J Mycol Med*. 2019;29(3):219–22.
3. Kulkarni PK, Reddy NB, Shrinivas B, Takkalki VV. Anesthetic considerations in the management of mucormycosis. *Int J Med Public Health*. 2015;5:387–90.
4. Pilmis B, Alanio A, Lortholary O, Lanternier F. Recent advances in the understanding and management of mucormycosis. 2018;doi:10.12688/f1000research.15081.1.
5. John NM, Anilkuma R, Ramya B, Satish HS. Management of sinonasal mucormycosis at a tertiary care center: Our experience. *Clin Rhinol Int J*. 2019;12(2):52–6.
6. Sen M, Honavar SG, Bansal R, Sengupta S. Epidemiology, clinical profile, management, and outcome of COVID-19-associated


- rhino-orbital-cerebral mucormycosis in 2826 patients in India - Collaborative OPAI-IJO Study on Mucormycosis in COVID-19 (COSMIC). *Indian J Ophthalmol*. 2021;69(7):1670–92.
7. Malhotra N, Bajwa SJS, Joshi M, Mehdiratta L, Kurdi M. Second wave of COVID-19 pandemic and the surge of mucormycosis: Lessons learnt and future preparedness: Indian Society of Anaesthesiologists (ISA National) Advisory and Position Statement. *Indian J Anaesth*. 2021;65(6):427–33.
 8. Gupta KK, Singh A, Kalia A, Kandhola R. Anaesthetic considerations of post COVID-19 mucormycosis surgery- A case report and review of literature. *Indian J Anaesth*. 2021;65(7):545–7.
 9. Barodka VM, Acheampong E, Powell G, Lobach L, Logan DA, Parveen Z, et al. Antimicrobial effects of liquid anesthetic isoflurane on *Candida albicans*. *J Transl Med*. 2006;9:46. doi:10.1186/1479-5876-4-46.
 10. Sarkar S, Gokhle T, Choudhari SS, Deb AK. COVID -19 and orbital mucormycosis. *Indian J Ophthalmol*. 2021;69:1002–4.
 11. Moorthy A, Gaikwas R, Krishna S, Hegde R, Tripathy K, Kale PG, et al. SARC Cov-2, Uncontrolled Diabetes and corticosteroids- An Unholy Trinity in Invasive Fungal infections of the Maxillofacial Region? A Retrospective, Multi-centric analysis. *J Maxillofac Oral Surg*. 2021;20(3):418–25. doi:10.1007/s12663-021-01532-1.
 12. Bhattacharyya A, Sarma P, Sharma DJ, Das KK, Kaur H, Prajapat M, et al. Rhino-orbito-cerebral-mucormycosis in COVID-19: A systemic review. *Indian J Pharmacol*. 2021;53(4):317–27.
 13. Jeong SJ, Lee JU, Song YG, Lee KH, Lee MJ. Delaying diagnostic procedure significantly increases mortality in patients with invasive mucormycosis. *Mycoses*. 2015;58(12):746–52.
 14. Spellberg B, Edwards J, Ibrahim A. Novel Perspectives on Mucormycosis: Pathophysiology, Presentation, and Management. *Clin Microbiol Rev*. 2005;18(3):556–69.

Author biography

Devyani Desai, Associate Professor

Neha Shah, Assistant Professor

Neha Cheraya, Assistant Professor

Bhoomika Kalarthi, Senior Resident  <https://orcid.org/0000-0003-1063-6646>

Sagar Bavisetti, 3rd Year Resident

Parvathy D, 3rd Year Resident

Abhishek Zala, 3rd Year Resident

Kanchan Choube, 2nd Year Student

Gaurav Cheraya, Consultant Pathologist

Cite this article: Desai D, Shah N, Cheraya N, Kalarthi B, Bavisetti S, Parvathy D, Zala A, Choube K, Cheraya G. Perioperative management of patients with post Covid rhino-orbito-cerebral mucormycosis: Prospective observational study. *Indian J Clin Anaesth* 2022;9(2):214-219.