



## Review Article

# Ankylosing spondylitis: what all should anaesthesiologist know?

Rajiv Lakhotia<sup>1,\*</sup>, Somnath Longani<sup>1</sup>, Rakhi Gupta<sup>1</sup>

<sup>1</sup>Dept. of Anaesthesiology, Hind Institute of Medical Sciences, Barabanki, Uttar Pradesh, India



### ARTICLE INFO

#### Article history:

Received 25-01-2022

Accepted 10-05-2022

Available online 13-08-2022

#### Keywords:

Ankylosing spondylitis

Awake fiberoptic intubation

Regional anaesthesia

Spondyloarthropathy

### ABSTRACT

Ankylosing Spondylitis (AS) may present significant issues to the anaesthesiologist as potential difficult airway, respiratory and cardiovascular complications, and the concomitant medication therapy to modify symptoms and disease. Awake fiberoptic intubation (AFOI) is a safe option in anticipated difficult airway, as it permits neurological monitoring throughout the attempt at achieving definitive airway. Central neuraxial blockade and peripheral nerve blocks may have good application for these cases. This morbidity renders the patients to greater risk of neurological complications in the peri-surgical period. Neurophysiological monitoring assists the clinician in timely diagnosis and intervention during surgery for cervical spine deformity correction. Addition of anti-tumour necrosis factor- $\alpha$  agents to the medical management has resulted in improved outcomes, however, with concomitant increased potential for wound infections in treated patients. Understanding of potential issues can pave the way for appropriate perioperative management.

This is an Open Access (OA) journal, and articles are distributed under the terms of the [Creative Commons Attribution-NonCommercial-ShareAlike 4.0 License](https://creativecommons.org/licenses/by-nc-sa/4.0/), which allows others to remix, tweak, and build upon the work non-commercially, as long as appropriate credit is given and the new creations are licensed under the identical terms.

For reprints contact: [reprint@ipinnovative.com](mailto:reprint@ipinnovative.com)

## 1. Introduction

Ankylosing Spondylitis also known as Marie Strumpell disease is a chronic painful inflammatory condition, a type of autoimmune seronegative spondyloarthropathy which is manifested by periods of exacerbations and remissions. Its main characteristic is the fusion of the bones in the spine, resulting in loss of flexibility of the back and neck clinically identified as bamboo spine. Disease spectrum may range from mild back stiffness to a totally fused ankylosed spine with variable peripheral arthritis and extra articular involvement.

Associated comorbidities include psoriasis, Reiter's syndrome, ulcerative colitis and Crohn's disease. AS affects usually men in the age group of 20 to 40 years, rarely after age of 50 years, with male: female ratio of 5:1 and higher incidence in HLA B 27 positive individuals. Ankylosing

Spondylitis (AS) may present significant issues to the anaesthesiologist as potential difficult airway, respiratory and cardiovascular complications, and issues pertaining to medication therapy to modify pain and disease.<sup>1</sup>

## 2. Relevant Epidemiology

Males have a predominance of more severe spinal and pelvic involvement, whereas peripheral joints are more affected in females viz. wrists, ankles, knees, hips. Juvenile onset AS is associated with severe clinical manifestations with observed incidence of 4% amongst AS patients.<sup>2</sup> It is commoner in whites due to higher prevalence of HLA-B27 alleles.

## 3. Pathogenesis

Triggering agent is unknown, however, susceptibility genes, age, gender, ethnicity and environmental factors play a role in clinical profile of disease presentation.<sup>3</sup> About 5% of HLA-B27 positive individuals are affected with AS,

\* Corresponding author.

E-mail address: [rajivlakhotia@gmail.com](mailto:rajivlakhotia@gmail.com) (R. Lakhotia).

however, 90 to 95% of affected patients are found to be HLA-B27 positive.<sup>4</sup> Synovial fluid mononuclear cells of AS patients substantiate this hypothesis.<sup>5</sup> Enthesitis is one of the pathological features of AS. New bone formation, bone erosion and inflammation starts at entheses. Enteses are sites of attachment of ligaments, tendons and joint capsules to bone and are present in vertebrae, sacroiliac as well as peripheral joints. New bone formation at entheses of vertebrae is called syndesmophyte which when bridge the vertebrae and fuse them across leads to the bamboo spine in AS.<sup>6</sup>

#### 4. Clinical Features

##### 4.1. Presentation

AS usually affects young adults who at presentation complain of low lumbar pain which characteristically improves with activity and exercise however worsens on rest and experiences prolonged rigidity on waking up after the night's rest. The juvenile pattern, initiated at less than 16 years of age, begins with arthritis and peripheral enthesopathies (inflammation of the insertion of tendons and ligaments in the bones) progressing over years to inflammatory lumbar pain. It is difficult to clinically differentiate many of them from juvenile rheumatoid arthritis. Early onset of disease and axial disease are more associated with hip joint involvement, signifying a bad prognosis due to the need of total hip prosthesis in many sufferers.<sup>7</sup>

##### 4.2. Histology

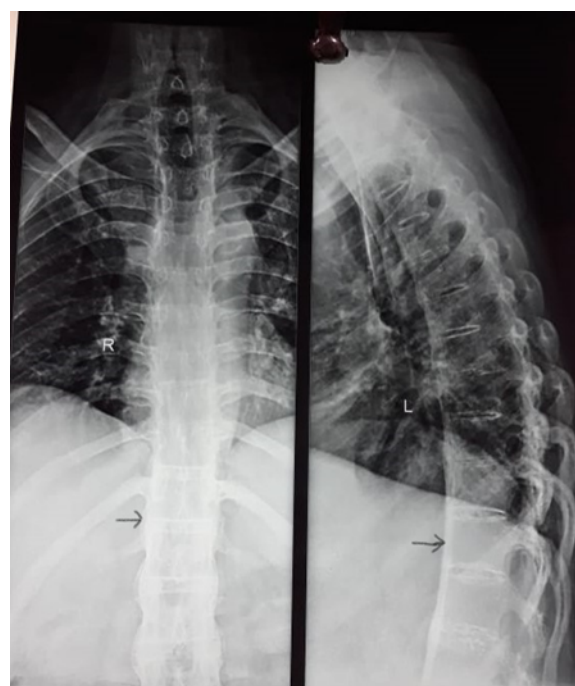
The affected joints are infiltrated by plasma cells, lymphocytes, mast cells, chondrocytes and macrophages, specifically the inflamed granulomatous tissues; which progressively are replaced by fibrocartilage and lead to fusion of bones in several patients.<sup>8</sup>

##### 4.3. Progression / Evolution

The disease process evolves cranially from the lumbar area, affecting the whole spine, characterized by loss of lumbar lordosis, increased dorsal kyphosis, straightening of cervical lordosis, forward head positioning leading to the skier posture. The calcification of interspinous ligaments forms bony bridges between the lumbar vertebrae manifesting as bamboo spine on radiograph (Figure 1). The affected cervical spine clinically varies from a functional limitation of neck movement to complete ankylosis.<sup>7</sup>

##### 4.4. Diagnosis

A decade long delay in the diagnosis since the first onset of symptoms is common observation in absence of any specific pathognomonic clinical feature or any specific laboratory test for diagnosis.



**Fig. 1:** Classical radiology of “bamboo spine” in PA view and ossification of anterior longitudinal ligament (black arrow) in the lateral view in a patient of AS. The orange coloured arrow indicates ankylosis of costo-vertebral joint which limits thoracic excursion

The modified New York criteria (combines clinical and radiologic criteria) are used to diagnose AS. The clinical criteria include: a) lumbar pain of more than three-month duration which characteristically reduces with activity and exercise but not with rest; b) functional limitation of movement of lumbar spine in the antero-posterior and lateral dimensions; and c) reduced thoracic expansibility. The radiological criteria include: a) grade 2 or > grade 2 bilateral sacroiliitis; b) grade 3 or 4 unilateral sacroiliitis. The occurrence of one clinical and one radiological criterion is mandatory to clinch the diagnosis of AS. The criteria required for diagnosis of AS is summarised in Table 1.<sup>9</sup>

**Table 1:** Modified New York criteria for AS. Diagnosis requires one radiological criterion with at least one clinical criterion.

##### Clinical criteria

Low back pain > 3 months duration, improves with exercise and is not relieved by rest

Limitation of motion of the lumbar spine in sagittal and coronal anatomical planes

Limitation of chest expansion relative to normal values corrected for age and sex

##### Radiological criteria

Bilateral sacroiliitis—grade 2 (sclerosis with some erosions) or higher

Unilateral sacroiliitis—grade 3 (severe erosions, pseudo dilatation of joint space and partial ankylosis) or grade 4 (complete ankylosis)

## 5. Complications & Clinical Implications

Widespread calcification resulting in syndesmophyte formation in the inflamed ligaments of vertebral column is complicated by osteoporosis in patients suffering from AS; which progressively leads to compression fractures causing hump deformity. Extension of spine related trauma may precipitate fractures through the calcified intervertebral disk spaces sometimes causing spinal transection. Risk of spinal cord injury is enhanced during patient transfers or fracture reduction manoeuvres. The deformities commonly result in an unsteady gait, with susceptibility to falls resulting in fractures.

A flexed immobile cervical spine, coupled with predisposition for fractures secondary to trauma caused by mild extension, along with coexisting limitation of mouth opening secondary to pathological changes in the temporomandibular joint, are definitive features to anticipate a difficult tracheal intubation. Significant atlanto-axial subluxation occurs in about 20% of patients of AS. Neurological issues ranging from paraesthesia to decrease in muscle strength are seen in about 47% patients with AS and history of vertebral fractures. Postures in flexion are preferred for stabilisation of these patients as neutral immobilisation manoeuvres predispose to increase in symptoms and neurological deficits.<sup>8,10–13</sup>

Massive epidural haemorrhages are a possibility, contributing to higher morbidity and mortality in patients of AS.<sup>14</sup> Peripheral joints affliction is characterised by development of oligoarthritis and enthesopathies affecting primarily large joints of the lower extremities viz. hip, knees and ankle joint. The other joints can also be involved viz shoulder, sternoclavicular and costochondral joints, presenting with pain and limited thoracic excursion. Enthesopathies present early in juvenile AS, usually affecting the insertion of Achilles tendon and plantar fascia.<sup>15</sup> Hip replacement is eventually required in about 20% of patients with juvenile onset AS, in about 10% of patients with delayed onset in late teens, and rare when the onset is late in the second or third decade of life. Patients of AS with coexisting psoriasis usually suffer with involvement of peripheral joints in upto 50% patients.<sup>16</sup> Temporomandibular joint affliction results in functional limitation of mouth opening in about 10% of patients which may increase to 30–40% in patients with long standing disease. Rarely it may affect cricoarytenoid joints leading to hoarseness, vocal cord fixation and dyspnoea. Pain during coughing and sneezing is observed due to affliction of costo-vertebral and costo-transverse joints. Achilles' tendonitis and planter fasciitis may be noted.<sup>17</sup> Findings of elevated erythrocyte sedimentation rate, mild normocytic, normochromic anaemia may be present and in advanced disease may be associated with increased alkaline phosphatase. Immunoglobulin A is usually elevated.<sup>15</sup>

Severe disease manifesting with cardio-respiratory complications includes aortic regurgitation commonly with occasional involvement of mitral valves; conduction defects may be observed by involvement of Purkinje fibres. Incidence of myocardial infarction is increased. The respiratory complications include reduced chest expansion, reduced vital capacity and reduced functional residual capacity due to fibrosis in upper lobes and disease of costovertebral joints. PFT may reveal a restrictive pattern in the lungs. The commonest extra-articular involvement is anterior uveitis (20% to 40%) presenting with sudden onset blurred vision, pain & redness of eyes and photophobia. Neurological complications are presented as cervical spine fracture, focal epilepsy, spinal cord compression, peripheral nerve lesions, vertebrobasilar insufficiency, etc. Features of prostatitis are observed in greater than 80% male patients during the course of disease.<sup>1</sup>

## 6. Management

While managing AS patients, objectives of clinician are pain relief, control of inflammation and maintenance of good posture and function. Use of non-steroidal anti-inflammatory medications (NSAIDs), relevant education, guide to physical therapy remain the essential elements of management. Anti-TNF- $\alpha$  agents are newer medications tried in subjects who do not respond to conventional pharmacotherapy. Spinal and joint reconstructive surgery are indicated in patients reporting with severe pain and disability.<sup>1</sup>

## 7. Pharmacotherapy

Inhibitors of prostaglandin E2 (which promote bone growth), viz. NSAIDs are prescribed to relieve spinal pain and limit the structural degenerative changes of spine.<sup>1</sup> For symptomatic relief of synovitis any antirheumatic agents (disease modifying agents) can be prescribed viz. sulfasalazine, leflunomide, methotrexate, etc.<sup>18</sup>

CT guided intra-articular injection of corticosteroid provides instant and prolonged relief.<sup>19</sup>

## 8. Novel Drugs

TNF- $\alpha$ , a cytokine which increases inflammation in AS, other spondyloarthropathies, inflammatory bowel disease, psoriasis, etc has been targeted through use of Anti-TNF- $\alpha$  agents viz. infliximab, adalimumab and etanercept with promising results and clinical improvement within two weeks.<sup>20</sup> These novel drugs improve physical function and may result in disease remission as revealed through MRI follow up.<sup>21</sup>

Precaution required prior to prescription of TNF- $\alpha$  blockers include screening for tuberculosis, status of chronic hepatitis B as these medications can reactivate TB or hepatitis B. They carry increased risk of perioperative

infections. They should be avoided in patients with CHF (NYHA class III-IV).<sup>1</sup>

## 9. Anaesthetic Implications

The anaesthesiologist should review the anaesthetic plan based on extent of disease focused in four main aspects: extent of upper airway involvement, pulmonary restrictive pathology, extent of cardiac dysfunction, and access to the neuroaxis.

The preoperative work up includes evaluation of range of movements of joints for appropriate patient positioning, lung function tests, cervical spine imaging and arterial blood gas analysis depending on the severity of manifestations of disease. The ECG to unmask any conduction defects and echocardiogram for any involvement of valves is performed.<sup>1</sup>

The jury is still not out on suspension of anti-TNF- $\alpha$  therapy prior to surgery. Further prospective studies are required to address this issue.

Respiratory involvement with restriction defects predisposes higher incidence of ICU ventilatory supports post-surgery. The hypotension associated with spinal anaesthesia is poorly tolerated in patients with defects in aortic valve, hence better avoided. External cardiac massage may be ineffective in a patient with rigid thoracic wall.<sup>7</sup> X-ray of lumbar spine is useful to evaluate the feasibility of sub arachnoid block. Nevertheless, neuroaxis blocks are technically difficult owing to decreased articular flexibility and ossification of interspinal spaces.<sup>22</sup> These difficulties concomitantly increase the risk of complications viz. spinal cord haematoma post epidural anaesthesia<sup>23</sup> as well as accidental intraosseous injection in caudal anaesthesia precipitating seizures.<sup>24</sup>

Precautionary steps should be undertaken for gastric protection due to rampant use of NSAIDs in patients of AS. Physiological changes of pregnancy in a patient with disease manifestations of AS render anaesthesia administration more challenging. AS with accentuated kyphoscoliosis and rigidity is a relative contra-indication for videolaparoscopic abdomino-thoracic surgery.<sup>25</sup>

## 10. Airway Management

Functional limitation of range of movement of neck in flexion hinders tracheal intubation compounded further when temporomandibular joint is involved. Evaluation of neck mobility, X-rays of cervical spine lateral and in maximal extension is mandatory. The criteria that predict difficult airways viz. Mallampati grading, Wilson index, thyromental distance, sternomental distance, and mouth opening should be reviewed.<sup>25</sup> Cricoarytenoid arthritis with dyspnoea, stridor and fixation of the vocal cords may rarely occur. Pre-operative indirect laryngoscopy can be helpful in assessing difficult intubation in affected cases. Risk of injury

is enhanced during neck extension for intubation of trachea in the setting of cervical kyphosis due to AS. Neck extension can also predispose vertebral artery insufficiency due to compromise of vertebral artery from bony encroachments. Serious complications viz. dislocation of C6 vertebra and quadriplegia may occur during emergency intubation. Fixed flexion deformities render tracheostomy treacherous. Neck supports under anaesthesia are advocated and forcible movements under neuromuscular blockade prohibited.<sup>1</sup>

Awake fiberoptic intubation (AFOI) is the safest option, whence on indirect laryngoscopy larynx is not visualised or in the presence of chin on chest deformity. AFOI is aided with instillation of local anaesthetic in the mucous membrane, infiltration of the superior laryngeal nerves, and trans-cricothyroid instillation of local anaesthetic. Retrograde intubation is another possible option if fiberoptic intubating scope is not available. Patients with severe flexion deformities make laryngeal mask airway (LMA) a difficult proposition as the angle of oropharynx axis may kink the LMA and obstruct positioning over trachea. The intubating laryngeal mask (ILM) may be a useful device in such patients. However, mouth opening of <1.2 cm or presence of fixed extension deformity or large cervical osteophytes preclude the use of LMA.<sup>1</sup> For facilitation of naso-tracheal intubation and enhanced visualisation of glottis in patients of AS videolaryngoscope has been suggested.<sup>26</sup>

## 11. Regional Anaesthesia

Regional Anaesthesia offers many advantages over general anaesthesia viz. excellent intra & postoperative analgesia. Two options are presented in the plan for lower limb surgery.

### 11.1. Central neuraxial block

Due to bamboo spine (loss of intervertebral space) central neuraxial block is very difficult but USG assisted central neuraxial blockade (continuous spinal epidural block) may lead to predictable success. Paramedian or Taylor approach may be used with greater success in patients of AS to assist lower limb surgeries.<sup>27</sup>

### 11.2. Peripheral nerve blocks

To minimise complications and unpredictable success of central neuraxial blocks, peripheral nerve blocks offer better options in patients of AS for lower limb surgeries. Peripheral nerve blocks can be used with good success for upper limb surgeries also viz. Interscalene and Supraclavicular brachial plexus block. Single shot or continuous posterior lumbar plexus block and parasacral block (USG or PNS guided) are good alternatives for intraoperative and post operative analgesia in these cases for lower limb surgeries viz. total hip arthroplasty, etc.<sup>28</sup>

## 12. Source of Funding

None.

## 13. Conflict of Interest

None.

## References

- Woodward LJ, Kam PCA. Ankylosing Spondylitis: recent developments and anaesthetic implications. *Anaesthesia*. 2009;64(5):540–8.
- Jimenez-Balderas FJ, Mintz G. Ankylosing spondylitis: clinical course in women and men. *J Rheumatol*. 1993;20(12):2069–72.
- Brophy S, Calin A. Ankylosing spondylitis: interaction between genes, joints, age at onset and disease expression. *J Rheumatol*. 2001;28(10):2283–8.
- Dakwar E, Reddy J, Vale F, Uribe J. A review of the pathogenesis of ankylosing spondylitis. *Neurosurg Focus*. 2008;24(1):E2. doi:10.3171/FOC/2008/24/1/E2.
- Gu J, Rihil M, Marker-Hermann E. Clues to pathogenesis of spondyloarthropathy derived from synovial fluid mononuclear cell gene expression profiles. *J Rheumatol*. 2002;29:2159–64.
- Ghosh A, Haldar S. Ankylosing Spondylitis – Clinical Features and Management. In: Manual of Rheumatology; 2014. p. 200–3.
- Popitz MD. Anesthetic implications of chronic disease of the cervical spine. *Anesth Analg*. 1997;84(3):672–83.
- Shaikh S. Ankylosing Spondylitis: recent breakthroughs in diagnosis and treatment. *J Can Chiropr Assoc*. 2007;51:249–60.
- Linden SVD, Valkenburg HA, Cats A. Evaluation of diagnostic criteria for ankylosing spondylitis. A proposal for modification of the New York criteria. *Arthritis Rheum*. 1984;27(4):361–8.
- Podolsky SM, Hoffman JR, Pietrafesa CA. Neurological complications following immobilization of cervical spine fracture in a patient with ankylosing spondylitis. *Ann Emerg Med*. 1983;12(9):578–80.
- Jacobs WB, Fehlings MG. Ankylosing spondylitis and spinal cord injury: origin, incidence, management and avoidance. *Neurosurg Focus*. 2008;24(1):12.
- Dave N, Sharma RK. Temporomandibular joint ankylosis in a case of ankylosing spondylitis anaesthetic management. *Indian J Anaesth*. 2004;48:54–6.
- Tico N, Ramon S, Garcia-Ortun F, Ramirez L, Castelló T, Garcia-Fernández L, et al. Traumatic spinal cord injury, complicating ankylosing spondylitis. *Spinal Cord*. 1998;36(5):349–52.
- Tetzlaff JE, Yoon HJ, Bell G. Massive bleeding during spine surgery in a patient with ankylosing spondylitis. *Can J Anaesth*. 1998;45(9):903–9.
- Linden SVD, Heijde DVD. Ankylosing spondylitis. Clinical features. *Rheum Dis Clin North Am*. 1998;24:663–76.
- Calin A. Ankylosing spondylitis. *Medicine*. 2006;34(10):396–400.
- Jimenez-Balderas FJ, Mintz G. Ankylosing spondylitis: clinical course in women and men. *J Rheumatol*. 1993;20(12):2069–72.
- Braun J, Sieper J. Ankylosing spondylitis. *Lancet*. 2007;369:1379–90.
- Dougados M, Dijkmans B, Khan M, Maksymowych W, Linden S, Brandt J. Conventional treatments for ankylosing spondylitis. *Ann Rheum Dis*. 2002;61(Suppl 3):40–50.
- Palladino MA, Bahjat FR, Theodorakis EA, Moldawer LL. Anti-TNF- $\alpha$  therapies: the next generation. *Nat Rev Drug Discov*. 2003;2(9):736–46.
- Braun J, Baraliakos X, Golder W, Brandt J, Rudwaleit M, Listing J, et al. Magnetic resonance imaging examination in patients with ankylosing spondylitis before and after successful therapy with infliximab: evaluation of a new scoring system. *Arthritis Rheum*. 2003;48(4):1126–36.
- Schelew BL, Vaghadia H. Ankylosing spondylitis and neuraxial anaesthesia a 10-year review. *Can J Anaesth*. 1996;43(1):65–8.
- Robins K, Saravanan S, Watkins EJ. Ankylosing spondylitis and epidural haematoma. *Anaesthesia*. 2005;60:624–5.
- Weber S. Caudal anesthesia complicated by intraosseous injection in a patient with ankylosing spondylitis. *Anesthesiology*. 1985;63(6):716–7.
- Oliveira CR, Degrandi. Espondilite anquilosante e anestesia. *Rev Bras Anesthesiol*. 2007;57(2):214–22.
- Lai HY, Chen IH, Chen A, Hwang FY, Lee Y. The use of the Glidescope for tracheal intubation in patients with Ankylosis Spondylitis. *Br J Anaesth*. 2006;97(3):419–22.
- Goyal R, Singh S, Shukla RN, Singhal A. Management of a case of ankylosing spondylitis for total hip replacement surgery with the use of ultrasound-assisted central neuraxial blockade. *Indian J Anaesth*. 2013;57(1):69–71.
- Imbelloni LE, Lucina N. Continuous posterior lumbar plexus and continuous parasacral and intubation with lighted stylet for ankylosing spondylitis. *Anesth Essays Res*. 2009;9(1):98–100.

## Author biography

**Rajiv Lakhotia**, Professor

**Somnath Longani**, Professor

**Rakhi Gupta**, Associate Professor

**Cite this article:** Lakhotia R, Longani S, Gupta R. Ankylosing spondylitis: what all should anaesthesiologist know?. *Indian J Clin Anaesth* 2022;9(3):374-378.