

Content available at: <https://www.ipinnovative.com/open-access-journals>

Indian Journal of Clinical and Experimental Ophthalmology

Journal homepage: www.ijceo.org

Case Series

Management and visual outcome of neovascular glaucoma in diabetes mellitus patients

Prashanth C N¹, Shamili S Nair^{1,*}¹Dept. of Ophthalmology, Dr. B. R. Ambedkar Medical College and Hospital, Bengaluru, Karnataka, India

ARTICLE INFO

Article history:

Received 19-11-2022

Accepted 21-12-2022

Available online 30-03-2023

Keywords:

NVG

Diabetic mellitus

Management

ABSTRACT

Aim of this study was to analyse the management of neovascular glaucoma (NVG) in patients with diabetes mellitus and assess the visual outcome. A retrospective case series was conducted. 20 diabetic patients with NVG who attended the retina clinic over a period of 1 year were taken for the study and were followed up for 6 months to 1 year. Among them, 15 patients had an effectively controlled intraocular pressure (IOP) after the treatment (16.68 ± 4.69 mmHg) as compared to the pre-treatment levels (42.59 ± 9.44 , $p < 0.05$). There was improvement in visual acuity to a certain extent in 12 eyes (62.7%) whereas visual acuity in 4 (23.5%) eyes was noted to be ≥ 0.1 , remained the same in 3 (17.6%) eyes, and became worse in 1 (5.8%) eye. Results showed that a comprehensive management with adequate number of pan-retinal photocoagulations (PRP), intravitreal/intracameral anti-vascular endothelial growth factor (VEGF) injections and early surgical interventions along with strict diabetic control can avert visual loss and improve the prognosis.

This is an Open Access (OA) journal, and articles are distributed under the terms of the [Creative Commons Attribution-NonCommercial-ShareAlike 4.0 License](https://creativecommons.org/licenses/by-nc-sa/4.0/), which allows others to remix, tweak, and build upon the work non-commercially, as long as appropriate credit is given and the new creations are licensed under the identical terms.

For reprints contact: reprint@ipinnovative.com

1. Introduction

Neovascular glaucoma (NVG) is a secondary glaucoma which occurs due to aggressive iris neovascularization (rubeosis iridis) that can cause progressive closure of anterior chamber angle along with rapid glaucomatous atrophy. The main underlying factor responsible for this condition is severe, diffuse and chronic ischemia of retina. Hence, the initial event in pathogenesis of NVG will be any condition that leads to hypoxia and ischemia of retinal tissues leading to production of angiogenic factors by the hypoxic retina in an attempt to revascularize the damaged areas. VEGF is the most important among these angiogenic factors. In NVG, the main cause for visual loss with elevated IOP is the ischemia of optic nerve head or retina or both combined.

According to population-based studies, the prevalence of NVG was estimated to be 0.20% - 0.55%.¹ Hospital based studies have estimated the prevalence of NVG to be 0.3%.² In a study conducted in Saudi Arabia, an increase in incidence of NVG in males as compared to females was found which was statistically significant.³

NVG can be caused by multiple ocular and systemic conditions. The most common among them are diabetic retinopathy (DR) (33%), followed by ischemic CRVO (33%) and ocular ischemic syndrome (13%).⁴ As compared to other diabetic retinopathies, patients with proliferative diabetic retinopathy (PDR) have higher prevalence of developing NVG (48.7%).⁵ NVG occurs as a complication of advanced PDR and it is correlated with the extent of retinal ischemia.

PDR patients presenting with NVG are often difficult to treat and hence they are a compromised population. In advanced diabetes, few antiglaucoma drugs have to

* Corresponding author.

E-mail address: shamalinair50@gmail.com (S. S. Nair).

be withheld due to the kidney status of the patient. The poor glycemic control in such patients can also cause undue delay in surgeries which can worsen the condition more. Also in certain conditions like PDR with vitreous hemorrhage (VH), optic disc cannot be visualised clearly due to which the ability to detect progression of disease and intervene accordingly will be hampered. However the basic management of NVG always depends on ablating the avascular retina so that angiogenesis factor formation can be prevented and IOP can be controlled either by medications or by surgery or both.

Management of NVG due to PDR basically involves systemic control of diabetes, pan-retinal photocoagulation (PRP), anti-vascular endothelial growth factor (VEGF) injections by ocular route, topical medications to control IOP and surgical interventions.⁶

This study is done with an aim to highlight the comprehensive management required for halting the progression of NVG in a PDR patient and the need for early diagnosis and aggressive treatment to gain a satisfactory visual outcome in such cases. This study aimed to study the management of neovascular glaucoma in patients with diabetes mellitus and evaluate the visual outcome.

2. Materials and Methods

In this retrospective case series medical records of 20 patients with neovascular glaucoma secondary to diabetes mellitus who attended retina clinic were taken for the study. Among 20 study subjects 11 were males (11 eyes) and 9 were females (9 eyes) belonging to an age group of 30-75 years. Comprehensive ocular examination and systemic investigations were: It included documentation of detailed ocular history, visual acuity testing with refraction, anterior segment examination with slit lamp biomicroscopy, IOP testing, gonioscopy with four mirror lens, dilated fundus examination with stereoscopic biomicroscopy and indirect ophthalmoscopy, spectral domain optical coherence tomography (SD-OCT) to assess retinal layers and fundus fluorescein angiography (FFA). Systemic investigations included FBS, PPBS, HbA1C, lipid profile and renal function test. Patient were selected according to following criteria

1. Inclusion criteria: Patients diagnosed with NVG caused secondary to diabetes mellitus, an IOP of ≥ 21 mmHg, neovascularisation of iris and angle with either open or closed angles.
2. Exclusion criteria: NVG patients who have undergone prior cyclocryotherapy / cyclophotocoagulation, NVG caused by ocular ischemic syndrome.

Following treatment modalities were adopted

2.1. Panretinal photocoagulation (PRP)

1. PRP was done in all patients with slit lamp using Double frequency Nd YAG Green laser with wavelength of 532nm.
2. The parameters used for photocoagulation was 1200–1600 burns, which are almost 500 μ m of spot size and with a distance of one spot from each other.
3. It was completed over 5-7 days of time period in 3 sessions.
4. 4 weeks following the first PRP sitting, OCT and FFA were performed in the patients to decide whether subsequent sittings of PRP were required.

2.2. Intraocular anti-VEGF injection

1. Intravitreal injection of bevacizumab was administered at a dose of 0.05ml/1.25mg.
2. I month following the initial injection, repeat injections of the same drug were given in required cases.

2.3. Medical management

1. In our study the patients were started on topical brimonidine (1% to 0.2%), timolol (0.5%), and dorzolamide (2%) as required.
2. Oral acetazolamide was given as a temporizing measure but was used with caution because of its risk of causing renal dysfunction in diabetes.⁷
3. Mannitol 20% was given intravenously in patients with significantly high IOP.
4. Topical atropine 1% was administered twice daily to resist synechiae formation and increase aqueous outflow via uveoscleral route.
5. Topical steroids and cycloplegics were given as a supportive treatment to reduce the inflammation.

2.4. Selective laser trabeculoplasty (SLT)

1. In our study, in refractory cases especially with closed angle, SLT was performed.
2. It was performed under slit lamp using Double frequency Nd YAG Green laser with wavelength of 532nm.
3. Before starting the procedure, 1 drop of brimonidine eyedrops (0.1%) was instilled in the eye and patient was made to wait for 20 minutes. The eye was then anesthetised with 1 drop of proparacaine (0.5%). Latina 1X lens along with the coupling fluid was then placed in contact with the cornea to visualise trabecular meshwork. Size of the laser spot was set to 400 micrometers and the duration of treatment was 4 nanoseconds. The lens was rotated until 360 degrees of trabecular meshwork was lasered. Non-overlapping shots, approximately 100 in number were given.

2.5. Glycemic control

A thorough systemic workup and appropriate interventions were taken by the endocrinologist to ensure tight glycemic control.

3. Results

1. The follow-up period for our study patients was around 6 months to 1 year
2. All 20 patients had received PRP, intravitreal anti VEGF injections and medical management to control IOP along with measures for glycemic control.
3. SLT was received by 15 (79.6%) eyes whose IOP could not be controlled even after all the above mentioned measures and by the end of treatment all these 15 eyes had an effectively controlled IOP of <21mmHg.
4. IOP of the other 5 eyes (11.4%) was between 21 and 28 mmHg.
5. The mean of pre-treatment IOP was 42.59 ± 9.44 mmHg and mean of post-treatment IOP was 16.68 ± 4.69 mmHg. Hence, the difference was statistically significant ($t = 17.07$, $P < 0.05$).
6. Improvement in visual acuity was noted in 12 (62.7%) eyes to various extent.
7. Among the rest, v4 (23.5%) eyes was noted to be ≥ 0.1 , 3 (17.6%) eyes became worse in 1 (5.8%) eye.
8. There were 5 eyes with only perception of light positive at the time of diagnosis. Among them, 3 had regained the visual acuity by the completion of treatment and their visual acuity values was noted to be 0.03, 0.05 and 0.01.

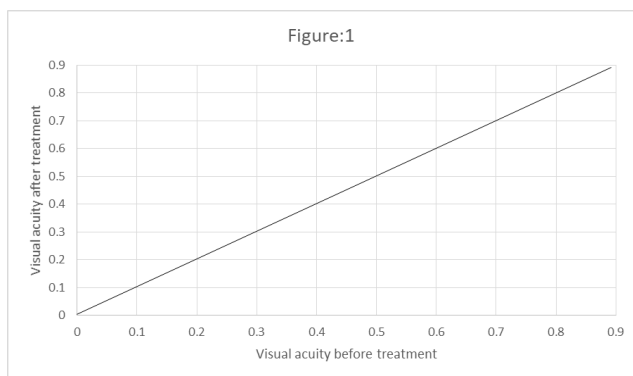


Fig. 1: Visual acuity before and after treatment

4. Discussion

Neovascular glaucoma is a common occurrence in patients with diabetic retinopathy and retinal vein occlusion.⁸ This

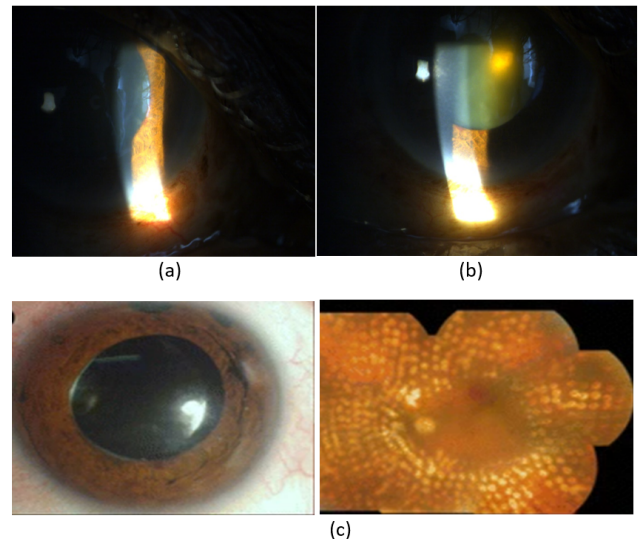


Fig. 2: (a) and (b) shows a patient who presented with rubeosis iridis in left eye with PDR with history of 10 years of diabetes mellitus; (c) shows the left eye of the same patient 10 months after treatment. Her IOP was recorded to be 20mm Hg in left eye with a visual acuity of 0.05

retrospective case series establishes a treatment strategy as follows. In all cases, the core aim of the management has to be lowering of IOP and preserving the visual acuity of the patient. Following this, intraocular anti-VEGF injections can be given which will regress NVI and reduce intraocular inflammation. Once it is achieved, PRP has to be done in order to avoid any further new vessel formation. Following these measures, if adequate results are not achieved in terms of visual acuity or IOP control, anti-glaucoma surgery can be considered.

In this study, 62.7% of the patients gained a stable or better visual acuity, and only 1 eye was reported to have a decreased visual acuity. After treatment, 16 eyes were reported to have a visual acuity of ≥ 0.1 which was a satisfactory result. Also, IOP was effectively controlled in majority of the patients in our study group.

Based on the underlying reason for NVG and the characteristics of its presentation, a conscious treatment strategy must be designed. The preliminary concern in any case of NVG should be IOP control followed by preservation of patient's existing visual acuity.⁹ For this, the ophthalmologists have to keep in mind the following points.

To start with, IOP of the patient should be decreased as early as possible to reduce the damage caused to visual status of the patient. It can be performed by administration of IOP lowering medications. Secondly the regression of new vessels can be done by anti-VEGF injections as and when required.¹⁰ Anti-glaucoma surgery can be performed in refractory cases.

Yaoyao Sun et al. in 2016 had done a study to claim anti-VEGF as the key strategy for NVG management in short term. Among 44 eyes in their study, 39 eyes displayed controlled IOP (≤ 21 mmHg) after treatment. Visual acuity improved, to some extent, in 32 eyes (72.9%), and 12 eyes (27.3%) had a visual acuity better than 0.1. They came to the conclusion that a comprehensive therapy for NVG can effectively control IOP and preserve visual function in patients by anti-VEGF injection.¹¹

All the measures taken to lower the IOP has to be continued throughout the completion of treatment. IOP has to be monitored closely till it becomes normal and it has to be kept stable. These measures along with lowering IOP and thereby saving visual acuity, can also help in creating an ideal condition for completing PRP. PRP is the utmost effective treatment, which improves the circulation of retina along with preventing it from releasing VEGF.¹² Throughout the management, patient has to be maintained in a state of glycemic control and it should be continued lifelong.

The outcomes of visual acuity and control of IOP will be usually poor in patients who present with angle closure stage as compared to open angle stage. All the patients in our study had open angles which might have aided to the satisfactory visual prognosis in our study.

Also, arguably the most critical factor for effective treatment outcome in NVG in long run is reducing the drive of retinal ischemia and for this invariably PRP is the mainstay. All our patients had received ≥ 1 sitting of PRP within 1 week of presentation and ≥ 3 sittings of PRP within 6 months of presentation.

In 2020, Putera I et al. had done a case report to describe the complex management of NVG, resulting from diabetic retinopathy, to achieve the best visual outcome. According to his study, comprehensive management should be implemented in NVG cases. Besides the administration of glaucoma and retinal care, blood glucose level should be carefully controlled during the follow-up period. Ahmed valve implantation, anti-VEGF injection (intravitreally and intracamerally), as well as PRP offer an effective method to halt NVG progression.¹³

In 2018, Abramowitz B et al. had conducted a study to compare the efficacy of selective laser trabeculoplasty and micropulse trabeculoplasty in NVG. They had come to the conclusion that micropulse trabeculoplasty has demonstrated similar efficacy to SLT over a 52-week follow-up period with less discomfort experienced both during and after the procedure.¹⁴

Our study is done with the purpose of highlighting the comprehensive management required in NVG. Although the treatment of NVG is complex, it can be achieved to a certain extent effectively if we focus on 2 main factors which include

1. Treatment of underlying disease process responsible for rubeosis.

2. Treatment of elevated IOP.

Through careful and strict follow-ups, we were able to detect the NVG cases at the earliest and an aggressive mode of treatment was started along with the help of our diabetologist.

5. Conclusion

1. Our study concludes that a comprehensive management strategy has to be followed for NVG.
2. It should basically include complete pan-retinal photocoagulation as its target, intraocular anti-VEGF injections and SLT as the key measures along with strict diabetic control.
3. This study has some limitations. Firstly, this is a retrospective study. This study doesn't have control group for comparison.
4. Number of patients in this study was small and follow up period was short as there was lack of sufficient data.

6. Source of Funding

None.

7. Conflict of Interest

None.

References

1. Fiebai B, Onua AA. Prevalence, Causes and Management of Neovascular Glaucoma: A 5-Year Review. *J Ophthalmol*. 2019;9:1–8.
2. Liao N, Li C, Jiang H, Fang A, Zhou S, Wang Q. Neovascular glaucoma: a retrospective review from a tertiary center in China. *BMC Ophthalmol*. 2016;16:14. doi:10.1186/s12886-016-0190-8.
3. Al-Bahlal A, Khandekar R, Rubaie KA, Alzahim T, Edward DP. Changing epidemiology of neovascular glaucoma from 2002 to 2012 at King Khaled Eye Specialist Hospital, Saudi Arabia. *Indian J Ophthalmol*. 2017;65(10):969–73.
4. Liang X, Zhang Y, Li YP, Huang WR, Wang JX, Li X. Frequency and Risk Factors for Neovascular Glaucoma After Vitrectomy in Eyes with Diabetic Retinopathy: An Observational Study. *Diabetes Ther*. 2019;10(5):1801–9.
5. Gange WS, Lopez J, Xu BY, Lung K, Seabury SA, Toy BC. Incidence of Proliferative Diabetic Retinopathy and Other Neovascular Sequelae at 5 Years Following Diagnosis of Type 2 Diabetes. *Diabetes Care*. 2021;44(11):2518–26.
6. Ramji S, Nagi G, Ansari AS, Kailani O. A systematic review and meta-analysis of randomised controlled trials in the management of neovascular glaucoma: absence of consensus and variability in practice. *Graefes Arch Clin Exp Ophthalmol*. 2023;261(2):477–501.
7. Senthil S, Dada T, Das T, Kaushik S, Puthuran G, Philip R, et al. Neovascular glaucoma - A review. *Indian J Ophthalmol*. 2021;69(3):525–34.
8. Maurya RP. Diabetic retinopathy : My brief synopsis. *Ind J Clin Exp Ophthalmol*. 2015;1(4):189–90.
9. Karpilova MA, Durzhinskaya MH. Anti-VEGF-preparaty v lechenii neovaskuliarnoi glaukomy [Anti-VEGF drugs in the treatment of neovascular glaucoma. *Vestn Oftalmol*. 2019;135(5):299–304.
10. Takayama K, Someya H, Yokoyama H, Kimura T, Takamura Y, Morioka M, et al. Potential bias of preoperative intravitreal anti-VEGF

injection for complications of proliferative diabetic retinopathy. *PLoS One*. 2021;16(10):e0258415.

11. Sun Y, Liang Y, Zhou P, Wu H, Hou X, Ren Z, et al. Anti-VEGF treatment is the key strategy for neovascular glaucoma management in the short term. *BMC Ophthalmol*. 2016;16(1):150.
12. Ehlers JP, Spirn MJ, Lam A, Sivalingam A, Samuel MA, Tasman W. Combination intravitreal bevacizumab/panretinal photocoagulation versus panretinal photocoagulation alone in the treatment of neovascular glaucoma. *Retina*. 2008;28(5):696–702.
13. Putera I, Suryono AN, Artini W. Challenging Management of Neovascular Glaucoma to Achieve the Best Visual Outcom. *Case Rep Ophthalmol*. 2020;11(1):85–91.
14. Abramowitz B, Chadha N, Kouchouk A, Alhabshan R, Belyea DA, Lamba T. Selective laser trabeculoplasty vs micropulse laser trabeculoplasty in open-angle glaucoma. *Clin Ophthalmol*. 2018;12:1599–1604.

Author biography

Prashanth C N, Professor and HOD  <https://orcid.org/0000-0001-8190-9256>

Shamili S Nair, Junior Resident  <https://orcid.org/0000-0002-1488-798X>

Cite this article: Prashanth C N, Nair SS. Management and visual outcome of neovascular glaucoma in diabetes mellitus patients. *Indian J Clin Exp Ophthalmol* 2023;9(1):112-116.