

Content available at: <https://www.ipinnovative.com/open-access-journals>

Indian Journal of Clinical and Experimental Ophthalmology

Journal homepage: www.ijceo.org

Original Research Article

Effects of SARS-Cov-2 infection and rhino-orbital mucormycosis on concentrations of inflammatory biomarkers in Indian populations

Ajay Kumar Yadav¹, Shivam Tiwari¹, Bhupendra Kumar², Abhay Kumar Yadav¹, Ashish Ashish³, Nitish Kumar Singh¹, Manpreet Kaur¹, Shivani Mishra¹, Shani Vishwakarma¹, Surendra Pratap Mishra⁴, Rajendra Prakash Maurya^{5,*}, Nargis Khanam¹, Pooja Dubey¹, Janhavi Yadav¹, Royana Singh¹, Sayeed Mehbub UL Kadir⁶

¹Dept. of Anatomy, Institute of Medical Sciences, Banaras Hindu University, Varanasi, Uttar Pradesh, India

²Dept. of Zoology, Institute of Science, Banaras Hindu University, Varanasi, Uttar Pradesh, India

³Multidisciplinary Research Unit, Institute of Medical Sciences Banaras Hindu University, Varanasi, Uttar Pradesh, India

⁴Dept. of Biochemistry, Institute of Medical Sciences, Banaras Hindu University, Varanasi, Uttar Pradesh, India

⁵Regional Institute of Ophthalmology, Institute of Medical Sciences, Banaras Hindu University, Varanasi, Uttar Pradesh, India

⁶Sheikh Fazilatunnesa Mujib Eye hospital and Training Institute, Gopalganj, Bangladesh



ARTICLE INFO

Article history:

Received 25-10-2022

Accepted 19-11-2022

Available online 29-12-2022

Keywords:

Fungal infection

SARS- Cov -2

Mucormycosis

Inflammatory markers

ABSTRACT

Rhino-orbital mucormycosis is a rare life threatening invasive fungal infection that has recently shown a very high mortality rate in India during COVID-19 pandemic. We have designed the present study to find out associations between COVID-19 induced rhino-orbital mucormycosis and concentrations of inflammatory markers, i.e. D-dimer, Ferritin, IL-6, CRP and PCT, in blood serum of Indian population.

There were four groups in the study, viz. control group with healthy subjects, treatment group-1 with patients suffering from SARS-COV-2 infection, treatment group-2 with patients suffering from both SARS-COV-2 infection and rhino-orbital mucormycosis, and treatment group-3 with patients suffering from rhino-orbital mucormycosis after SARS-COV-2 infection recovery. Inflammatory markers were quantified with standard protocols, and recorded data were subjected to statistical analyses.

We found that patients suffering from SARS-COV-2 infection were more susceptible to rhino-orbital mucormycosis, as they had higher concentrations of inflammatory markers in their blood than the other subjects. Diabetes mellitus, hypertension, cardiovascular diseases and renal disorders were the associated comorbidities with the patients. We also found higher concentrations of inflammatory markers in males than the females, indicating towards their higher susceptibility in developing rhino-orbital mucormycosis than females.

Present study therefore suggests that the frequent occurrence of rhino-orbital mucormycosis in India during second wave of COVID-19 was possibly due to indiscriminate use of corticosteroids by COVID-19 patients. Subjects with previous history of comorbidities like diabetes mellitus, hypertension, cardiovascular disorders and renal diseases are the most susceptible population groups for developing infection. Moreover, males are at higher risk of developing mucormycosis than the females.

This is an Open Access (OA) journal, and articles are distributed under the terms of the [Creative Commons Attribution-NonCommercial-ShareAlike 4.0 License](https://creativecommons.org/licenses/by-nc-sa/4.0/), which allows others to remix, tweak, and build upon the work non-commercially, as long as appropriate credit is given and the new creations are licensed under the identical terms.

For reprints contact: reprint@ipinnovative.com

1. Introduction

Rhino-orbital mucormycosis is a rare life threatening invasive fungal infection that has recently shown a very high

* Corresponding author.

E-mail address: mauryarp_bhu@yahoo.com (R. P. Maurya).

mortality rate in India. The infection is caused by *Rhizopus Oryzae* (Mucorales: Zygomycetes), a ubiquitous fungi that causes 90% of the global rhino-orbital mucormycosis.¹ The infection occurs through the inhalation of fungal spores that occur naturally in the environment, the body surface, and the orifices. The spores inoculate the paranasal sinuses and nasopharynx, and spread to the orbit and intracranial cavity in humans with reduced cellular and humoral defenses.² The infiltrating fungus keeps on destroying the surrounding bone and soft tissue through vascular thrombosis and tissue infarction, and subsequently reaches the brain with fatal complications.³ Being an opportunistic infection, the rhino-orbital mucormycosis preferentially affects immunocompromised individuals suffering from diabetes mellitus, neutropenia, malignancy, chronic renal failure, acquired immunodeficiency syndrome, and those who have received organ or hematopoietic stem cell transplants.^{4,5}

The second wave of severe acute respiratory syndrome coronavirus-2 (SARS-COV-2) infection in India has witnessed a huge resurgence in cases of rhino-orbital mucormycosis. The researchers are still exploring the possible reasons for such an upsurge in cases of rhino-orbital mucormycosis during COVID-19 pandemic. Henceforth, we have designed the present study to find out associations between rhino-orbital mucormycosis and SARS-COV-2 infection by using certain inflammatory markers, viz. D-dimer, Ferritin, Interleukin-6 (IL-6), C-reactive protein (CRP) and Procalcitonin (PCT). The D-dimer is a specific metabolite of cross-linked fibrin formed by plasma fibrinolytic enzyme; and its increased concentration reflects the secondary fibrinolysis.⁶ In a normal person its concentration is < 500 ng/ml.

Ferritin is a cellular means of storing iron and is widely measured as an indicator of iron status.⁷ It is involved in iron metabolism. When serum ferritin leaks from damaged cells, it leaves the stored iron in an unliganded form that further causes the cellular damage.⁸ Hence, ferritin is a potential biomarker in inflammatory diseases such as COVID-19, cancer, neurodegeneration or other infections. Its normal range is between 20 - 250 ng/ml in males and 10 -120 ng/ml in females. Interleukin-6 is closely associated with the severity of diseases like COVID-19, avian-origin H₇N₉ influenza infections, and common seasonal H₁N₁ influenza. Its normal range in human blood is < 7 pg/ml.

The C-reactive protein is a member of pentraxin family of innate immune response proteins. It is mainly produced in liver in response to IL-6, plays a direct role in atherogenesis,⁹ and is a potent predictor of type II diabetes,¹⁰ myocardial infarction, neoplastic diseases¹¹ and SARS-CoV-2 infection.¹² The normal range for blood CRP concentration in blood is <10 mg/L. However, PCT is a 116-amino acid precursor of the hormone calcitonin. Several studies have found a close association between elevated PCT levels and the severity of SARS-CoV-2 infection.¹³

While the normal range for blood PCT concentration in blood is <50 pg/mL, a recent study has reported that increased PCT values are related to a ~5-fold higher risk of severe SARS-CoV-2 infection.¹⁴

We anticipate that the findings of present study may be helpful in quantifying the associations between SARS-COV-2 infection and the upsurge in rhino-orbital mucormycosis during second wave in India. The findings may also be helpful in identifying the most susceptible patient groups, which are at higher risks of COVID-19 associated rhino-orbital mucormycosis amongst the patients with different comorbidities.

2. Materials and Methods

The study was conducted in MRU lab, Sir Sunderlal Hospital and Department of Anatomy of Institute of Medical Sciences, Banaras Hindu University, Varanasi (India) from May 2021 2017 to June 2021. The study screened 245 subjects, but considered 126 subjects based on inclusion and exclusion criteria. Both females (n=55) and males (n=71) of variable ages (females=between 38.8±2.3 and 45.14±3.2; males=between 45.5±2.0 and 56.0±3.8 years) were considered in the study. All subjects were of Indian ethnicity from eastern Uttar Pradesh and Bihar, the two states of northern India. The study was approved by the Institutional Medical Ethical Committee No.2021/EC/2677. All subjects were informed about the study and their consents were taken prior to the start of the study.

2.1. Study design

For all subjects included in the study, reverse transcription PCR (RT-PCR) test was conducted for the detection of SARS-CoV-2 infection. The results of the test, the subject history, the clinical presentation and course, and the radiological findings were recorded. The patients with rhino-orbital mucormycosis were identified on the basis of the guideline designed for the diagnosis and management of mucormycosis,^{14,15} which includes patients having the following symptoms: (i) nasal stiffness and discharge, headache, facial pain or swelling, proptosis, ptosis, ocular motility restriction, diplopia or sudden decreased vision, etc., (ii) radiological evidence of angioinvasion, presence of bone destruction and necrosis in involved structures (paranasal sinus, orbit/brain),¹⁶ and (iii) tissue biopsy with pathological evidence of tissue invasion, vessel occlusion, and non-pigmented non-/pauci-septate hyphae with variable width (6–16 μm) or the same typical fungal appearance in microbiological culture (Figure 1).

There were four groups in the study, viz. (i) control group with healthy subjects (females=5; males=8), (ii) treatment group-1 with patients suffering from SARS-COV-2 infection (females=20; males=23), (iii) treatment group-2 with patients suffering from both SARS-COV-2 infection

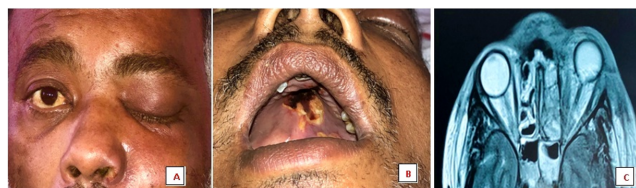


Fig. 1: Clinical photograph of a male patient of rhino-orbital mucormycosis showing (A): Left eye ptosis, proptosis and periocular & facial swelling (B): Palatal ulcer/eschar (C): Axial MRI (T₂) showing involvement of the left medial orbit, infiltrating muscle and orbital fat in posterior orbit along with involvement of the left ethmoid sinus

and rhino-orbital mucormycosis (females=24; males=34), and (iv) treatment group-3 with patients suffering from rhino-orbital mucormycosis after SARS-COV-2 infection recovery (females=6; males=6). The patients of treatment group-3 were those that were tested negative for COVID-19 at the time of diagnosis but had a prior positive test record and were admitted for treatment, with symptoms of rhino-orbital mucormycosis appearing few days following discharge. Disease severity was categorized according to proposed staging of Rhino-Orbito-Cerebral Mucormycosis (ROCM) by Honavar (2021).¹⁵ All patients concurrently positive for SARS-CoV-2 infection and had moderate to severe rhino-orbital mucormycosis were treated for COVID-19 protocol in accordance with the national guidelines issued by Indian Council of Medical Research, New Delhi, India.

The healthy subjects that were negative to both the rhino-orbital mucormycosis and SARS-CoV-2 infection were considered in the control group. The blood samples of patients were taken at Sir Sunderlal hospital, Institute of Medical Sciences, Varanasi (India). However, the blood samples of healthy subjects were taken either at MRU lab or Department of Anatomy, Institute of Medical Sciences, Varanasi. About 4-5ml of blood was taken out by venepuncture method from the subjects for serum isolation. The blood was collected in citrate coated vials, which were centrifuge (REMI, R-8C) at 3000 rpm for 5 min and the isolated serum was collected in 1.5 ml Eppendorff tube for the determination of serum concentrations of D-Dimer, Ferritin, IL-6, CRP and PCT inflammatory markers.

2.2. Determining concentrations of D-Dimer, Ferritin, IL-6, CRP and PCT biomarkers

The concentrations of D-dimer and ferritin in the blood serum were determined as per the protocols of ichromax kit (Boditech Med Incorporated, Korea; www.boditech.co.kr). However, the concentrations of IL-6, CRP and PCT inflammatory markers in the blood serum were determined by Diaclone human IL-6 ELISA kit (Diaclone SAS, France, www.diaclone.com). The data were recorded for further

statistical analysis.

2.3. Statistical analyses

Distributions of data sets obtained in the study were checked for normality using Kolmogorov-Smirnoff test and homogeneity of variances using Bartlett's test for equal variances. All dependent variables (inflammatory markers), viz. concentrations of D-dimer, Ferritin, IL-6, CRP and PCT were subjected to Kruskal-Wallis test, considering health status of subjects (viz. normal healthy subjects, SARS-COV-2 infected patients, rhino-orbital mucormycosis with SARS-COV-2 infected patients, and patients with rhino-orbital mucormycosis post SARS-COV-2 infection recovery) as independent variable.

Dependent variables were also subjected to regression analysis and regression graphs were extrapolated. In addition, Chi-Square (χ^2) test was performed to analyse the level of significance in comorbidities (i.e. diabetes mellitus, hypertension, cardiovascular disorders, renal disorders and cancer) in males and females, within the samples under consideration. All statistical analyses were performed using MINITAB 16 (Minitab Inc., State College, Pennsylvania, USA).

3. Results

Kruskal-Wallis test revealed significant effect of the health status of males and females on the concentrations of their inflammatory markers. In females, the concentration of D-dimer (H=19.09; P<0.0001; df=3) and ferritin (H=8.75; P=0.033; df=3) varied significantly with the health status of subjects. However, the concentration of IL-6 (H=6.59; P=0.086; df=3), CRP (H=5.27; P=0.153; df=3) and PCT (H=2.31; P=5.11; df=3) did not vary significantly with the health status of subjects (Table 1). Post-hoc comparison of means and regression graphs further exposed that female suffering from SARS-COV-2 infection had higher concentrations of D-dimer, and those suffering from both rhino-orbital mucormycosis and SARS-COV-2 infection had higher concentrations of ferritin in their blood serum than the other females. The concentrations of IL-6 and CRP were similar in blood serum of all the infected females. Except for the concentration of PCT which was similar in all females, the healthy females had lowest concentrations of inflammatory biomarkers in their blood serum (Figures 2 and 3).

In males, except for the concentration of CRP (H=6.70; P=0.082; df=3) that did not vary significantly with the health status of subjects, the concentration of D-dimer (H=43.91; P<0.0001; df=3), ferritin (H=8.79; P=0.032; df=3), IL-6 (H=16.84; P=0.001; df=3) and PCT (H=8.89; P=0.031; df=3) varied significantly with the health status of subjects (Table 1). Post-hoc comparison of means and regression graphs further exposed that male suffering from SARS-

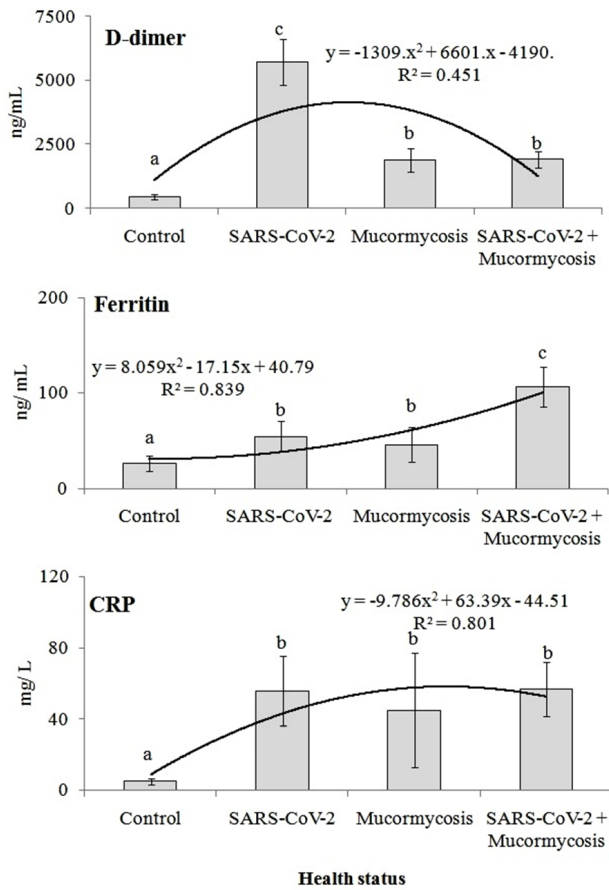


Fig. 2: Concentration of inflammatory markers in blood serum of females with different health status (Values are Mean±SE; small letters represent comparison of means amongst the four treatment groups)

COV-2 infection had higher concentrations of D-dimer, ferritin, CRP and PCT levels in their blood than the other males. However, those suffering from both rhino-orbital mucormycosis and SARS-COV-2 infection had higher concentrations of IL-6 in their blood than the other males. Except for the concentration of PCT which was similar in majority of the males, the healthy males had lowest concentrations of inflammatory biomarkers in their blood serum (Figure 3; Figure 4).

We observed that the disease severity was more marked in male patients with higher concentrations of serum biomarkers (Table 1). The comorbidity data has further revealed that majority of the patients were having no previous history of comorbidity, but were either COVID-19 positive or had a previous history of SARS-COV-2 infection. Others were suffering from diabetes mellitus, followed by hypertension and cardiovascular disorders. Few patients were suffering from renal disorders and cancer. The comorbidities were equally affecting ($\chi^2=3.89$; $P=0.566$; $df=5$) both the male and female patients (Figure 3).

Table 1: Effect of health status of males and females on the concentrations of inflammatory markers in blood serum (All values are Mean±SE; Degree of freedom=3; Different letters represent significant differences amongst mean values of health status of subjects)

Gender	Health status	D-Dimer	Ferritin	IL-6	CRP	PCT
Female	Control (Normal)	453.94±116.01 ^a	26.39±8.20 ^a	4.55±1.35 ^a	4.89±1.51 ^a	44.16±25.42 ^{ab}
	SARS-COV-2 positive	5713.26±906.24 ^c	54.62±16.20 ^b	11.80±3.00 ^b	55.76±19.49 ^b	52.68±13.54 ^b
	Mucormycosis with SARS-COV-2 infection	1883.43±455.79 ^b	45.96±18.13 ^b	13.23±2.76 ^b	44.97±32.28 ^b	23.68±8.00 ^a
	Mucormycosis post SARS-COV-2 infection recovery	1903.29±323.34 ^b	106.42±21.13 ^c	16.35±4.36 ^b	56.70±15.32 ^b	32.69±7.90 ^a
Male	Control (Normal)	241.98±49.01 ^a	75.30±31.40 ^a	6.99±2.65 ^a	8.17±4.62 ^a	46.28±22.92 ^{ab}
	SARS-COV-2 positive	8899.38±485.73 ^d	310.61±64.86 ^c	21.01±4.85 ^b	92.69±16.20 ^c	59.91±13.18 ^b
	Mucormycosis with SARS-COV-2 infection	4627.35±1618.79 ^c	128.60±75.84 ^b	28.86±8.86 ^{bc}	55.54±27.14 ^b	25.80±11.28 ^a
	Mucormycosis post SARS-COV-2 infection recovery	2177.77±455.56 ^b	155.57±39.19 ^b	55.74±23.64 ^c	64.05±16.58 ^b	38.58±16.34 ^a
Kruskal-Wallis Test		H=19.09; P<0.0001	H=8.75; P=0.033	H=6.59; P=0.086	H=5.27; P=0.153	H=2.31; P=0.511
Kruskal-Wallis Test		H=43.91; P<0.0001	H=8.79; P=0.032	H=16.84; P=0.001	H=6.70; P=0.082	H=8.89; P=0.031

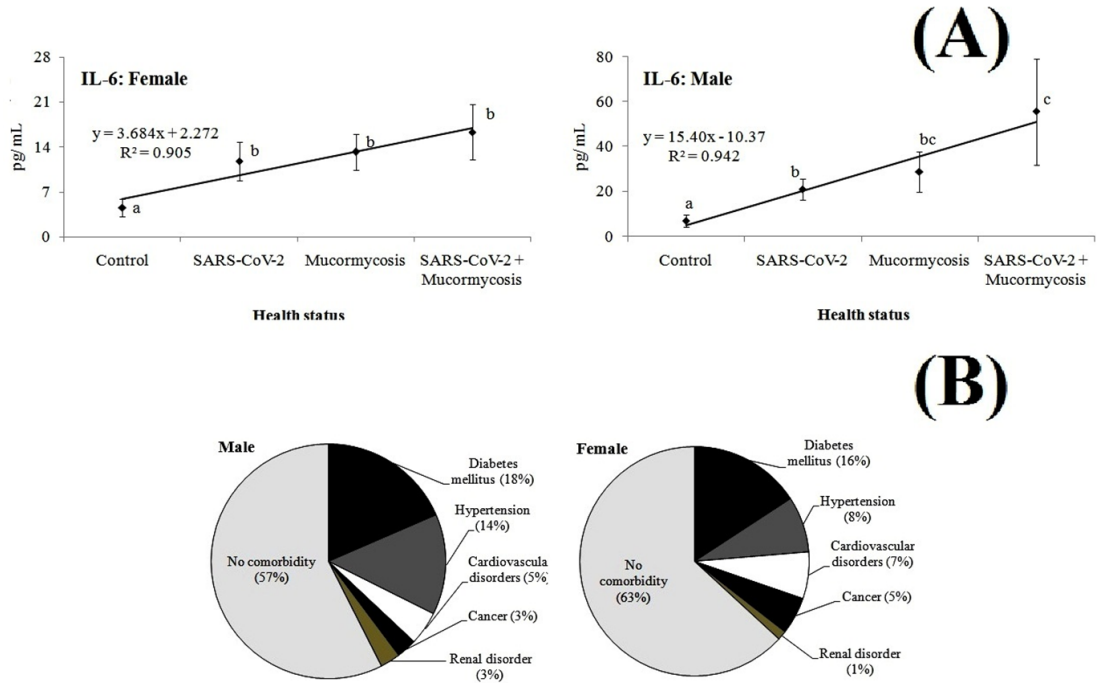


Fig. 3: (A): Concentration of IL-6 in blood serum of females and males with different health status (Values are Mean±SE; small letters represent comparison of means amongst the four treatment groups).; (B): Comorbidities associated with male and female patients suffering from SARS-CoV-2 infection and/or rhino-orbital mucormycosis

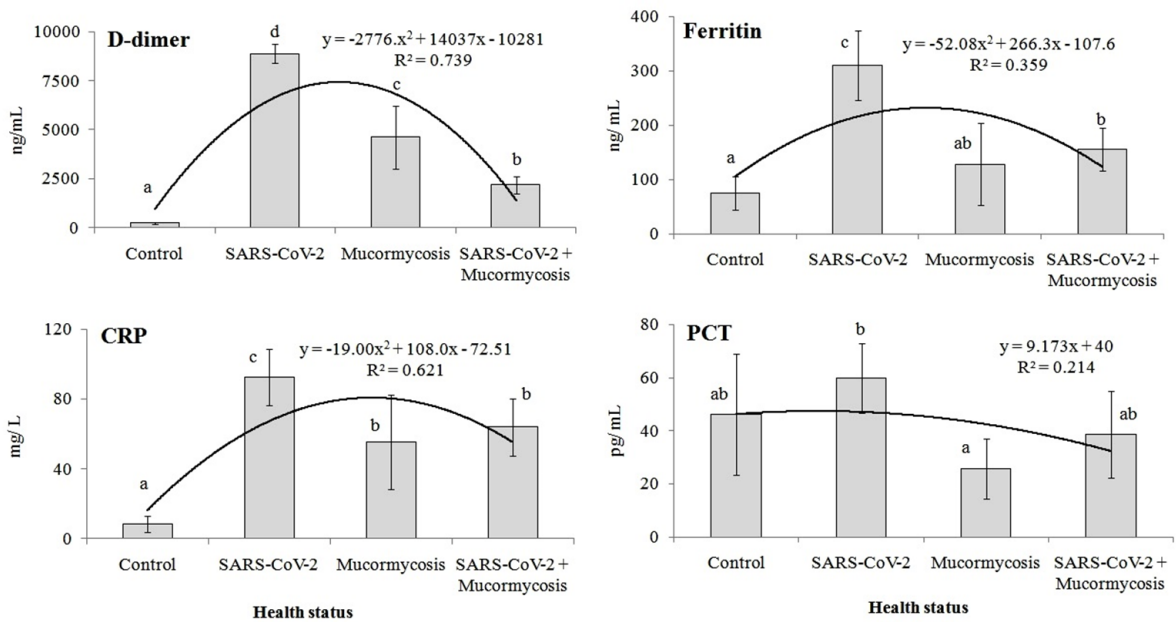


Fig. 4: Concentration of inflammatory markers in blood serum of males with different health status (Values are Mean±SE; small letters represent comparison of means amongst the four treatment groups)

4. Discussion

Rhino-orbital mucormycosis is an opportunistic infection that affects the immune-compromised and debilitated patients. Microbiological diagnosis, control of underlying systemic conditions and antimicrobial therapies with debridement of necrotic tissues are some of the possible strategies to overcome the infection.^{17,18} During the screening of patients for the study, we found that patients recovered from SARS-CoV-2 infection were more susceptible to rhino-orbital mucormycosis than the patients with active SARS-CoV-2 infection. The possible reasons may be the correlation between SARS-CoV-2 infection, the concurrent steroid use and decreased immunity in patients suffering COVID-19, as reported earlier by Sarkar.¹⁹ SARS-CoV-2 infection causes viral-induced lymphopenia and allows therapeutic use of corticosteroids and/or hydroxychloroquine, which are likely to impair the phagocytic immune-cell response, the major defense mechanism against mucormycosis.¹⁷ This ultimately leads to impairment of bronchoalveolar macrophages migration, ingestion, and phagolysosome fusion, making a diabetic patient highly vulnerable to mucormycosis.²

The infection of SARS-CoV-2 virus also causes endothelialitis, endothelial damage, thrombosis, lymphopenia, and reduction in CD4+ and CD8+ levels, leading to secondary or opportunistic fungal infections.² Thus, there are huge possibilities that the extended use of corticosteroids may have weakened the immune system of patients recovered from SARS-CoV-2 infection, thereby making them more prone to rhino-orbital mucormycosis.

While females suffering from SARS-CoV-2 infection had higher concentrations of D-dimer, the males had higher concentrations of D-dimer, ferritin and CRP levels in their blood serum than the other subjects. In addition, the females suffering from both rhino-orbital mucormycosis and SARS-CoV-2 infection had higher concentrations of ferritin, and the males had higher concentrations of IL-6 in their blood serum than the other subjects. The higher concentration of D-dimer and ferritin in blood serum of patients suffering from SARS-CoV-2 and/or mucormycosis indicate the severity of the infection. As previously reported, the availability of free iron is an ideal resource for mucormycosis,^{2,20} Physiological conditions like hyperglycemia causes glycosylation of transferrin and ferritin, and reduces iron binding thereby allowing increased free iron. Moreover, increased cytokines in patients with COVID-19 also increases the availability of free iron by increasing the ferritin levels due to its increased synthesis and decreased iron transport. The concomitant acidosis due to SARS-CoV-2 infection also increases the abundance of free iron in blood by reducing the ability of transferrin to chelate iron. As a result, the availability of high glucose, low pH, free iron, and ketones in presence of decreased phagocytic activity of WBC enhances the growth of mucor

leading to mucormycosis.²⁰

Similar to our findings, the availability of higher concentrations of inflammatory biomarkers (D-dimer, ferritin and CRP) in patients suffering from SARS-CoV-2 and/or mucormycosis has also been reported earlier by Selarka²¹ in Indian population. Their laboratory investigations reported mean D-dimer, CRP and ferritin levels to be 305±335.9 ng/ml, 76.4 ±55.6 mg/L and 357.0±280.3 ng/mL, respectively. The healthy subjects (males and females) had lowest concentrations of inflammatory biomarkers in their blood than the infected subjects.

Although, in our study the concentration of PCT was similar in majority of the subjects; however, contrary to our findings previous studies have reported that serum PCT levels increase as SARS-CoV-2 infection worsens.^{22,23} As patients recover from the infection, both high-normal and abnormal PCT levels decrease.¹³ However similar to our findings, Roques reported no increase or only a slight increase in PCT, which remained well below the threshold range in patients suffering from mucormycosis.

Our study has further revealed that half of the patients suffering from rhino-orbital mucormycosis were having no previous history of comorbidity. They were either COVID-19 positive or had a previous history of SARS-CoV-2 infection. Perhaps, the corticosteroid therapy, history of pulmonary infection due to COVID-19 and use of broad-spectrum antibiotics may have been the possible factors for the emergence of frequent invasive fungal infections in patients without any previous comorbidity history.^{24,25}

The other affected patients were found to be suffering from diabetes mellitus, followed by hypertension and cardiovascular disorders. Some patients were also suffering from renal disorders and cancer. The most common underlying disease in our study was diabetes mellitus. Since diabetes mellitus causes impaired neutrophil function, microvascular insufficiency, and other metabolic abnormalities in case of ketoacidosis, the disease therefore promotes the fungal growth.^{26,27} Members of *Rhizopus* species contain an active ketone reductase system and thrive in high glucose and acidotic conditions. While the normal serum inhibits the growth of *Rhizopus* species, serum of diabetic ketoacidosis patients stimulates its growth.²⁸ Hence, patients with diabetes mellitus are more prone to develop rhino-orbital mucormycosis in presence of SARS-CoV-2 infection.

Patients with hypertension, cardiovascular disorders and renal diseases are simultaneously associated with diabetes mellitus. Consequently, such patients are at a higher risk of developing rhino-orbital mucormycosis. Patients with hematological malignancies have also been reported to develop rhino-orbital mucormycosis^{26,29} have reported that COVID-19 accompanied with immune-compromised states such as long-standing diabetes, HIV or tumors are more

likely to develop fungal coinfections.

Results of present study have further shown that between the male and female subjects, males are at higher risk of developing rhino-orbital mucormycosis. Although comorbidities like diabetes mellitus, hypertension, cardiovascular or renal disorders have not shown any gender-specific variation, but we found higher concentrations of inflammatory markers in males than the females in our study. The differences may arise due to variations in body architecture and basic physiology, hormone profiling, stress tolerance capacity and general immunity of males and females. The occupational and life-style differences in Indian males and females may also be responsible for the males to have higher chances of infections than the females. Hence, more studies are needed in such directions.

Our results are in conformity with those reported earlier by Selarka^{2,19} and Singh, whereby they found a higher prevalence of rhino-orbital mucormycosis in males, both in active or recovered from COVID-19. However, contrary to our findings,³⁰ have reported no gender-specific differences in patients suffering from rhino-orbital mucormycosis. In addition, previous studies have also reported no association between age and severity of rhino-orbital mucormycosis.¹⁷

5. Conclusion

The present study therefore suggests that the frequent occurrence of rhino-orbital mucormycosis in India during the second wave of COVID-19 was possibly due to the indiscriminate use of corticosteroids by COVID-19 patients. Poor dietary control and lack of medical care during lockdown phase were the other possible factors for the quick development of the infection. Subjects with previous history of comorbidities like diabetes mellitus, hypertension, cardiovascular disorders and renal diseases are the most susceptible population groups for developing the infection. In addition, males are at higher risk of developing mucormycosis than the females. Although we are still exploring the other possible reasons for upsurges in cases of rhino-orbital mucormycosis during COVID-19 pandemic; however, future studies are highly needed to quantify the safe doses of corticosteroids against COVID-19 induced mucormycosis, their modes of administration and associated risks in both male and females of variable age groups and with different comorbidities.

6. Ethical Clearance

The study was approved by the Institutional Medical Ethical Committee No.2021/EC/2677. All subjects were informed about the study and their consents were taken prior to the start of the study.

7. Author Contribution

RS, SPM, RPM, and AA Conception or design of the work. ST, AKY, SM, SV, AKY, NKS, MK contributed to the data collection and interpretation and the initial draft of the manuscript. BK carried out the statistical analysis and contributed to the draft and revision of the manuscript. BK contributed to the data collection and analysis. RS design of the study and the patient recruitment and critically revised the manuscript. All authors provided and approved for the final manuscript.

8. Source of Funding

Multi-Disciplinary Research Units (MRUs) and DST, a grant by ICMR-Department of Health Research [Grant No: 6004].

9. Conflict of Interest

The authors declare no competing interests.

Acknowledgments

This research was sponsored by Multi-Disciplinary Research Units (MRUs) and DST, a grant by ICMR-Department of Health Research [Grant No: 6004].

References

1. Sugar AM, Liu XP. Combination Antifungal Therapy in Treatment of Murine Pulmonary Mucormycosis: Roles of Quinolones and Azoles. *Antimicrob Agents Chemother*. 2000;44(7):2004–6.
2. Singh AK, Singh R, Joshi SR, Misra A. Mucormycosis in COVID-19: A systematic review of cases reported worldwide and in India. *Diabetes Metab Syndr*. 2021;15(4):102146.
3. Spellberg B, Edwards J, Ibrahim A. Novel perspectives on mucormycosis: pathophysiology, presentation, and management. *Clin Microbiol Rev*. 2005;18(3):556–69.
4. Camara-Lemarroy CR, González-Moreno EI, Rodríguez-Gutiérrez R, Rendón-Ramírez EJ, Ayala-Cortés AS, Fraga-Hernández ML. Clinical features and outcome of mucormycosis. *Interdiscip Perspect Infect Dis*. 2014;2014:562610.
5. Chakravarti J, Gupta MK, Tilak R, Kumar R, Maurya RP, Kumar NK, et al. COVID-19-associated Mucormycosis : Aclínico-epidemiological study. *J Diabetes Complications*. 2022;36(9):108284.
6. Tita-Nwa F, Bos A, Adjei A, Ershler WB, Longo DL, Ferrucci L. Correlates of D-dimer in older persons. *Aging Clin Exp Res*. 2010;22(1):20–3.
7. Mehta S, Pandey A. Rhino-Orbital Mucormycosis Associated With COVID-19. *Cureus*. 2020;12(9):e10726.
8. Kell DB. Towards a unifying, systems biology understanding of large-scale cellular death and destruction caused by poorly liganded iron: Parkinson's, Huntington's, Alzheimer's, prions, bactericides, chemical toxicology and others as examples. *Arch Toxicol*. 2010;84(11):825–89.
9. Ridker PM. Evaluating novel cardiovascular risk factors: can we better predict heart attacks? *Ann Intern Med*. 1999;130(11):933–7.
10. Pradhan AD, Manson JE, Rifai N, Buring JE, Ridker PM. C-reactive protein, interleukin 6, and risk of developing type 2 diabetes mellitus. *JAMA*. 2001;286(3):327–34.
11. Vashist SK, Venkatesh AG, Schneider EM, Beaudoin C, Luppá PB, Luong J. Bioanalytical advances in assays for C-reactive protein. *Biotechnol Adv*. 2016;34(3):272–90.
12. Chen X, Zhao B, Qu Y, Chen Y, Xiong J, Feng Y, et al. Detectable Serum Severe Acute Respiratory Syndrome Coronavirus 2 Viral Load (RNAemia) Is Closely Correlated With Drastically Elevated

- Interleukin 6 Level in Critically Ill Patients With Coronavirus Disease 2019. *Clin Infect Dis*. 2019;71(8):1937–42.
13. Hu R, Han C, Pei S, Yin M, Chen X. Procalcitonin levels in COVID-19 patients. *Int J Antimicrob Agents*. 2020;56(2):106051.
 14. Lippi G, Plebani M. Procalcitonin in patients with severe coronavirus disease 2019 (COVID-19): A meta-analysis. *Clin Chim Acta*. 2020;505:190–1.
 15. Cornely OA, Alastruey-Izquierdo A, Arenz D, Chen SCA, Dannaoui E, Hochhegger B, et al. Global guideline for the diagnosis and management of mucormycosis: an initiative of the European Confederation of Medical Mycology in cooperation with the Mycoses Study Group Education and Research Consortium. *Lancet Infect Dis*. 2019;19(12):405–21.
 16. Honavar SG. Guidelines for the Diagnosis, Staging and Management of Rhino-Orbito-Cerebral Mucormycosis in the Setting of COVID-19. *Indian J Ophthalmol*. 2021;69(6):1361–5.
 17. Ravani S, Agrawal G, Leuva P, Modi P, Amin K. Rise of the phoenix: Mucormycosis in COVID-19 times. *Indian J Ophthalmol*. 2021;69(6):1563–8.
 18. Maurya RP. Indications for orbital exenteration in COVID-19 associated Rhino-orbito-cerebral Mucormycosis. *IP Int J Ocul Oncol Oculoplast*. 2021;7(2):105–8.
 19. Sarkar S, Gokhale T, Choudhury S, Deb A. COVID-19 and orbital mucormycosis. *Indian J Ophthalmol*. 2021;69(4):1002–4.
 20. Baldin C, Ibrahim AS. Molecular mechanisms of mucormycosis—The bitter and the sweet. *PLoS Pathogens*. 2017;13:1–5.
 21. Selarka L, Sharma S, Saini D, Sharma S, Batra A, Waghmare VT. Mucormycosis and COVID-19: An epidemic within a pandemic in India. *Mycoses*. 2021;64(10):1253–60.
 22. Guan W, Ni Z, Hu Y, Liang W, Ou C, He J, et al. Clinical Characteristics of Coronavirus Disease 2019 in China. *N Engl J Med*. 2020;382(18):1708–20.
 23. Lu R, Zhao X, Li J, Niu P, Yang B, Wu H, et al. Genomic characterisation and epidemiology of 2019 novel coronavirus: implications for virus origins and receptor binding. *Lancet*. 2020;395(10224):565–74.
 24. Ahmadikia K, Hashemi SJ, Khodavaissy S, Getso MI, Alijani N, Badali H, et al. The double-edged sword of systemic corticosteroid therapy in viral pneumonia: A case report and comparative review of influenza-associated mucormycosis versus COVID-19 associated mucormycosis. *Mycoses*. 2021;64(8):798–808.
 25. White PL, Dhillon R, Cordey A, Hughes H, Faggian F, Soni S, et al. A National Strategy to Diagnose Coronavirus Disease 2019-Associated Invasive Fungal Disease in the Intensive Care Unit. *Clin Infect Dis*. 2021;73(7):1634–44.
 26. Lanternier F, Dannaoui E, Morizot G, Elie C, Garcia-Hermoso D, Huerre M, et al. A global analysis of mucormycosis in France: The RetroZygo study. *Clin Infect Dis*. 2005;54(Suppl 1):S35–43.
 27. Sen M, Lahane S, Lahane TP, Parekh R, Honavar SG. Mucor in a Viral Land: A Tale of Two Pathogens. *Indian J Ophthalmol*. 2021;69(2):244–52.
 28. Gale GR, Welch AM. Studies of Opportunistic Fungi. I. Inhibition of *Rhizopus oryzae* by Human Serum. *Am J Med Sci*. 1961;241(5):604–12.
 29. Song G, Liang G, Liu W. Fungal Co-infections Associated with Global COVID-19 Pandemic: A Clinical and Diagnostic Perspective from China. *Mycopathologia*. 2020;185(4):599–606.
 30. Sreshta K, Dave TV, Varma DR, Nair AG, Bothra N, Naik MN, et al. Magnetic resonance imaging in rhino-orbital-cerebral mucormycosis. *Indian J Ophthalmol*. 2021;69(7):1915–27.

Author biography

Shivam Tiwari, Research Scholar

Bhupendra Kumar, Assistant Professor

Abhay Kumar Yadav, Research Scholar

Ashish Ashish, Scientist

Nitish Kumar Singh, Research Scholar

Manpreet Kaur, Research Scholar

Shivani Mishra, Research Scholar

Shani Vishwakarma, Research Scholar

Surendra Pratap Mishra, Research Scholar

Rajendra Prakash Maurya, Associate Professor
 <https://orcid.org/0000-0001-9343-6003>

Nargis Khanam, Research Scholar

Pooja Dubey, Research Scholar

Janhavi Yadav, Research Scholar

Royana Singh, Professor

Sayed Mehabub UL Kadir, Assistant Professor

Cite this article: Yadav AK, Tiwari S, Kumar B, Yadav AK, Ashish A, Singh NK, Kaur M, Mishra S, Vishwakarma S, Mishra SP, Maurya RP, Khanam N, Dubey P, Yadav J, Singh R, UL Kadir SM. Effects of SARS-Cov-2 infection and rhino-orbital mucormycosis on concentrations of inflammatory biomarkers in Indian populations. *Indian J Clin Exp Ophthalmol* 2022;8(4):450-457.