

Content available at: <https://www.ipinnovative.com/open-access-journals>

Indian Journal of Obstetrics and Gynecology Research

Journal homepage: www.ijogr.org

Case Report

20 weeks pregnancy with COVID-19 infection during second wave of pandemic: A case report

Juhi Deshpande^{1,*}, Pulkit Gupta²

¹Maa Vindhyavasini Autonomous State Medical College, Mirzapur, Uttar Pradesh, India

²Dept. of Respiratory Medicine, Government Medical College, Azamgarh, Uttar Pradesh, India



ARTICLE INFO

Article history:

Received 03-06-2022

Accepted 14-07-2022

Available online 08-11-2022

Keywords:

COVID 19

Pregnancy

Second wave

Pandemic

ABSTRACT

Novel corona virus (SARS-COV-2) is a new strain of corona virus causing COVID-19, first identified in Wuhan City, China. It was declared as a pandemic by the WHO on 11 March 2020. Pregnancy alters the body's immune system and response to viral infections, therefore, pregnant females are related with more severe symptoms as compared to general population. Not much studies and guidelines are clearly available for the management of pregnant females with COVID-19. We are presenting a case of 20 weeks pregnancy with COVID -19 POSITIVE and how we managed the patient, during the second, deadly wave of pandemic. We hope this case report would be helpful for the clinicians to deal with pregnant patients with COVID 19, keeping in mind two lives are at risk.

This is an Open Access (OA) journal, and articles are distributed under the terms of the [Creative Commons Attribution-NonCommercial-ShareAlike 4.0 License](https://creativecommons.org/licenses/by-nc-sa/4.0/), which allows others to remix, tweak, and build upon the work non-commercially, as long as appropriate credit is given and the new creations are licensed under the identical terms.

For reprints contact: reprint@ipinnovative.com

1. Case Report

A 26 years old pregnant female (Primigravida and 20 weeks pregnant), doctor by profession presented to us with chief complaints of fever, cough, shortness of breath and chest pain since 5 days at L2 COVID Hospital, Government Medical College, Azamgarh. Fever was high grade, insidious in onset, continuous, no diurnal variation and was relieved on medication. Patient also complained of cough since 5 days. It was dry in nature and was not associated with diurnal or postural variation. She also had shortness of breath since 5 days. It was insidious in onset, mMRC (modified Medical Research Council scale) grade 2 initially but gradually became grade 3. Dyspnea aggravated on exertion and was relieved with rest. She had chest pain since 5 days, which was insidious in onset and dull aching in nature. It was bilateral, non-radiating and non-migratory. No relieving or aggravating factors were present.

No complaints of hemoptysis, loss of weight, loss of appetite, orthopnea, abdominal pain, nausea, vomiting, trauma, altered sensorium or loss of consciousness was there.

No history of tuberculosis/Diabetes Mellitus/Hypertension/Coronary Artery Disease/thyroid disorders/asthma or inhaler use in the past. Patient is non-smoker, non-alcoholic and takes vegetarian diet.

2. Investigations

At the time of admission

SPO2- 91% at room air.

Blood pressure- 98/66 in right arm supine position.

Respiratory rate- 24 per second.

X-ray chest- PA view (abdominal guarding) - No abnormality was detected.

ABG- showed type 1 respiratory failure.

CBC- Total leukocyte count (TLC) was 5900 (N52 L45 E3) on day of admission.

* Corresponding author.

E-mail address: juhidesh@gmail.com (J. Deshpande).

LFT, RFT, RBS, ECG, Cardiac profile, d-dimer, Serum Ferritin and CRP was normal RTPCR for COVID 19 - positive.

3. Diagnosis

Based on history, signs, symptoms and investigations, patient was diagnosed to be a case of Primigravida with 20 weeks gestation, COVID -19 positive with moderate severity.

4. Treatment

Patient was admitted in ward. Moist nasal O₂ was given through non-rebreathing mask at 15 litres/minute to maintain target saturation at and above 92%. Nebulisation with budesonide was done. Antibiotic including ceftriaxone and azithromycin was given. Intravenous fluids were given. Patient's blood pressure became normal following fluid infusion. Multivitamins and minerals including vitamin C, D and calcium, iron and folic acid were given. Blood anticoagulant (low molecular weight heparin) was given subcutaneously. Intravenous steroid methylprednisolone was given at 125mg loading dose followed by 80 mg for 5 days and there after tapered to minimum dose by day 15.

On day 3 of admission or day 8th of illness patient's condition began to deteriorate with respiratory rate 32 per minute. SPO₂ falling to 87% with non-rebreathing mask at 15 litres / minute. Patient was immediately shifted to ICU. Investigations were repeated. Chest X-ray PA view showed bilateral patchy infiltration in middle and lower zone. TLC was found to be increased. CRP, d-dimer and serum ferritin were found to be significantly raised indicating worsening of infection.

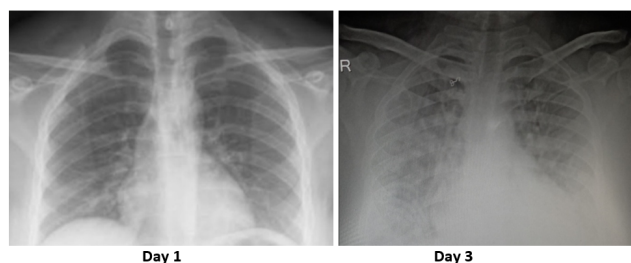


Fig. 1: Left- Normal X-Ray chest findings on the day of admission; Right -X- Ray chest showing bilateral patchy infiltration in middle and lower zone on Day 3 of admission

Inj amoxicillin and Inj clindamycin was started. Also patient was shifted to HFNC (high flow nasal cannula) support at 50 litres/minute and target saturation was maintained at or above 92%. Injection Remdesivir (200 mg loading dose on day 1 followed by 100 mg on day 2-5) and hydroxychloroquine (loading dose 800 mg in 2 divided doses on day 1 followed by 400 mg daily for day 2-5) was

given. Inj N-acetyl cysteine was also started.

Following above treatment patient's condition improved. Investigations were repeated every alternate day which also improved. SPO₂ improved over the period of time and symptoms got better. Repeat RTPCR was negative on day 15 following which patient was discharged with advice of home isolation for 7 days.

5. Follow-Up

Patient's follow up was done in non COVID hospital. Obstetric ultrasound was done on 7th day which showed single 23 weeks pregnancy with severe oligohydramnios (AFI-2.5cm).

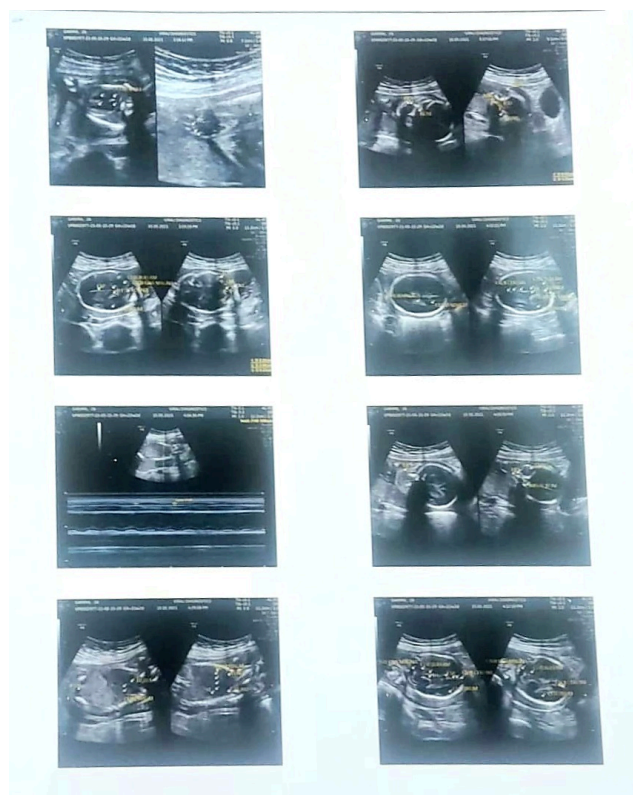


Fig. 2: Obstetrics ultrasound – showing single intrauterine pregnancy of 23 weeks with severe oligohydramnios (Amniotic fluid index=2.5cm)

In her blood investigations, patient's random blood sugar was raised and following further investigations she was diagnosed with gestational diabetes mellitus and was put on treatment with insulin.

Patient was kept on weekly follow up. Her ultrasound 15 days later showed moderate oligohydramnios (AFI- 6.5) and blood sugars were also within normal range.

Her obstetric ultrasound was repeated every 15 days and her ultrasound at 36 weeks showed AFI- 9.

At 37 weeks of gestation patient spontaneously passed into labour and delivered vaginally an alive, healthy male

Table 1: Showing the blood investigation findings during treatment

Day of admission	Day 3	Day 5	Day 7	Day 10
TLC (normal= 4000-10000)	21200	16090	12000	8900
LFT	WNL	WNL	WNL	WNL
RFT	WNL	WNL	WNL	WNL
Serum Ferritin	1500	600	300	WNL
CRP (normal= 0-6mg/l)	92	36	12	WNL
DDIMER	4.2	2.2	WNL	WNL

baby of 2.9kg.

6. Discussion

Rates of severe coronavirus disease 2019 (COVID-19),^{1,2} ICU admission, and maternal mortality increased among pregnant and postpartum women admitted for COVID-19 in the second wave compared with the first wave in India. Pregnancy itself being immunocompromised state, pregnant females were greatly affected by coronavirus with fatal maternal and fetal outcome. In our case, the patient's symptoms worsened on day 3 of admission and had to be shifted to ICU immediately and aggressive management was started in terms antibiotics (amoxycilin and clindamycin),³ HFNC was started, and antiviral inj Remdesevir was given. Because of timely and aggressive management of the patient with strict monitoring, we were able to save the life of both the mother and fetus.

7. Conclusion

We observed that the key to management of second wave COVID 19 pandemic is timely and aggressive treatment without delay. Special care needs to be taken for immunocompromised individuals. Pregnant females who were affected with COVID 19 in early stages of pregnancy were observed to develop gestational diabetes mellitus in later stages of pregnancy. Therefore, COVID 19 in second wave not only had immediate consequences but also led to medical complications in later days. More research needs to be done on post COVID-19

complications among the survivors.

8. Source of Funding

None.

9. Conflict of Interest

None.

References

1. The epidemiological characteristics of an outbreak of 2019 novel coronavirus diseases (COVID-19) in China. *Zhonghua Liu Xing Bing Xue Za Zhi.* 2020;41(2):145–51.
2. World Health Organization. [Online] [Cited: March 28, 2020.]. Available from: <https://www.who.int/dg/speeches/detail/whodirector-general-s-opening-remarks-at-the-media-briefing-on-covid-19>.
3. Favre G, Pomar L, Qi X, Nielsen-Saines K, Musso D, Baud D. Guidelines for pregnant women with suspected SARS-CoV-2 infection. *Lancet Infect Dis.* 2020;20(6):652–3.

Author biography

Juhi Deshpande, Assistant Professor  <https://orcid.org/0000-0001-8727-7237>

Pulkit Gupta, Assistant Professor

Cite this article: Deshpande J, Gupta P. 20 weeks pregnancy with COVID-19 infection during second wave of pandemic: A case report. *Indian J Obstet Gynecol Res* 2022;9(4):565-567.