

Case Report

COMBINE PROSTHESIS WITH PRECISION ATTACHMENT FOR DISTAL EXTENSION KENNEDY CLASS II ARCH- A CASE REPORT

Anjali Dutta¹, Madhurima Sharma², Shalabh Kumar³, Pratik Bumb⁴, Anusheel Sharma⁵

¹PG Student, Teerthanker Mahaveer Dental College and Research Centre, Moradabad, India.

²Professor, Teerthanker Mahaveer Dental College and Research Centre, Moradabad, India.

³Professor & Head, Teerthanker Mahaveer Dental College and Research Centre, Moradabad, India.

⁴Private Practitioner, Teerthanker Mahaveer Dental College and Research Centre, Moradabad, India.

⁵PG Student, Teerthanker Mahaveer Dental College and Research Centre, Moradabad, India.

Abstract:

Background: A prosthodontic rehabilitation's success depends critically on striking a balance between new and traditional treatment modalities.

These prosthodontic treatment options include partial dentures with attachments. The majority of conventional RPD are adequately designed, but they are rarely utilised by patients because they don't like how they look or how well they retain information. This article describes a modified extended precision attachment for removing metal display to improve the aesthetics and preservation of a long-span partial edentulous arch restored using prosthodontic rehabilitation.

A 68-year-old male patient was referred to the prosthodontics department for the purpose of replacing lost teeth. Kennedy's class I mode 1 in the mandibular arch with a worn out dentition were identified during clinical testing. Maxillary and mandibular arches were precisely planned for fixed and removable partial denture.


The underlying residual alveolar ridge and the retentive components are both necessary for the RPD to be successful. In this case study, the use of precision attachments results in a more aesthetically pleasing end and enhanced retention on the mandibular partial dentures.

Clinical significance: By applying precision attachment, the treatment plan adequately described restores the appearance, masticatory function, and enhances the prosthesis' retention.

Key-words: Fixed Partial Denture, Flexible Denture, Precision Attachment, Cast Partial Denture.

1. Introduction:

It has always been difficult for prosthodontists to create a full or partial denture that gives the patient with comfort and satisfaction while also providing enough retention, support, and stability.² In today's society, the older population is more worried about their oral health care and is more demanding of the treatment they receive from clinicians, thus the physicians should be informed of all forms of prosthodontic treatment choices accessible for this demographic. It is usually difficult to restore patients who have few surviving natural teeth, as in Kennedy's class I and II instances where the distal abutment is absent.³ The placement of an implant-supported prosthesis is possible in fixed options, but the possibilities are limited by the conditions of underlying bone and the high cost of the implant procedure. The only treatment available in this case is a partial denture made of acrylic or cast metal. This form of therapy offers affordable options for care and gives the patient a renewed hope. Dentures with attachments can restore lost teeth in a way that is both aesthetically pleasing and functional.

 This work is licensed under a [Creative Commons Attribution 4.0 International License](https://creativecommons.org/licenses/by/4.0/).

DOI:
<https://doi.org/10.58935/joas.v2i1.21>

Received date: 01/02/2023

Accepted date: 22/03/2023

Published date: 25/04/2023

Male patient of 68 year age came to Department of Prosthodontics complaining about worn-out dentition and multiple missing teeth. Intra oral examination revealed that complete wear-out dentition, multiple root stumps, missing molars. Patient oral prophylaxis status was satisfactory. Radiographic examination reveals moderate level of bone loss. 31, 32, 34 and 35 worn out teeth in the lower anterior region needed endodontic treatment.

Interdisciplinary approach was done endodontically, periodontically and prosthodontically. Mandibular arch was categorised as Class I modification 1 in accordance with Applegate's rule and Kennedy's categorization. In order to replace lost teeth, the first option given to the Patient was to insert implants. As the patient was not physically fit as he was a cardiac patient. His cardiologist rejected the request for authorization to have an invasive surgery. Therefore, other best course of treatment was carried out. For the unilateral, a combined prosthesis held by extracoronary castable precision attachment was envisaged, together with a fixed partial denture on the anterior and left sides of the mandible and a distal extension on the right side. In addition to a three unit fixed partial denture for the right maxilla. Finally, it was decided that the patient had long span edentulous area and was unable to undergo any invasive procedure, making a flexible removable partial denture the best option for the left maxillary arch.

The male section of the extracoronary castable precision attachment used metal ceramic crowns with attachment devices that were waxed up and cast. Porcelain was made after firing clay. Denture base with attachment made of acrylic fabrication (female section). A vertical strut in the male portion of the attachment runs into the base of the device and provides the prosthesis with lateral stability and distal support. The female section of the castable housing is a single piece that entirely encloses the male section. The acrylic prosthesis was attached using the supplied connection after the crown was secured with glass ionomer cement. In centric and eccentric orientations, occlusal connections were evaluated. A post-insertion examination was scheduled for the patient after one day. On how to practise good dental hygiene, the patient received instructions.

Discussion:

Rehabilitation of a patient with a distal extension who is partially denuded becomes challenging if the patient refuses implants or a removable prosthesis. The only option to manage such a critical condition is to prepare for a combined prosthesis. In comparison to fixed prostheses that do not require surgical intervention, a mixed prosthesis, which keeps an acrylic prosthesis attached to the tooth extracoronally, also has a number of advantages.

Precision attachment is often suggested for distal extension bases, non-parallel abutments, and long span edentulous arches. Precision attachments are referred to as connectors that have two or more parts. Where the prosthesis is joined to one component is by an implant, tooth, or root that is attached to it. The extracoronary castable attachment method used extends the crown's distal surface.

During the wax-up stage, crowns can be used to quickly create the castable male component. The female piece of the acrylic partial denture entirely encloses the male portion. Dr. James Andrews created the fixed removable prosthesis for the first time^{9,10}. Precision attachment dentures are a practical therapeutic option when used in conjunction with the right case selection, diagnostic strategy, and treatment strategy. This attachment needs to be assembled by skilled lab employees, and as it ages, individual parts need to be replaced due to wear and tear¹¹.

Flexible resins' ability to adhere to both hard and soft tissue undercuts and their inherent flexibility are the foundation of the concept behind them. Therefore, the flexible dentures provide good retention for clinical scenarios like Kennedy's Classes I & II, which include

distal extension, by engaging the severe soft tissue undercuts and clasping the surrounding teeth.

Flexible dentures absorb a small amount of water, which increases their suppleness and tissue compatibility. They won't warp or get delicate. These dentures are more comfortable and appealing than other types of dentures. Biocompatibility can be established because typical denture materials' primary allergens, metal and monomer, aren't present. 5

Since the material is translucent, tissue tones beneath the surface are picked up by it, making it practically hard to see within the mouth. Clear clasps enhance aesthetics because there is no clasping visible on the tooth surfaces. The material is incredibly versatile and durable. The substance is robust and highly flexible.

Conclusion:

In situations when the distal abutment is absent and the patient refuses to accept implants, this case report illustrates how challenging it is to provide either a permanent or removable prosthesis (due to fear of surgery). A combined prosthesis is the solution for placing a prosthesis without surgery in circumstances of distal extension. A combination prosthesis is composed of an attachment mechanism that connects a fixed prosthesis (a crown) and a detachable prosthesis (an acrylic partial denture). The success of prosthesis depends on careful treatment planning. Precision attachments save the function of retention, stress distribution and aesthetics successfully.

References

- ¹Prosthetic rehabilitation of distal extension with fixed- removable partial denture prosthesis using custom made semi-precision attachment-case report. European journal of molecular & clinical medicine, 2022; 9(3): 4967-4973.
- ²Roessler DM. Complete denture success for patients and dentists. International dental journal. 2003 Nov;53(S5):340-5.
- ³Mc Craken's Removable partial denture prosthodontics 12th edition. Pg 12
- ⁴Howlader TH, Alam MK, Sultana A. An in vivo comparison of different impression materials for reproduction of intra-radicular surface anatomy using injection technique. International Medical Journal 2013; 20(1): 95-9
- ⁵Prashanti E, Jain N, Shenoy VK. Flexible dentureA flexible option to treat edentulous patient. J of Nepal Dental Association 2010; 11(1) : 85-87
- ⁶Gupta N., Bhasin A., Gupta P. and Malhotra P., 2013. Combined prosthesis with extracoronal castable precision attachments. Case Rep Dent.
- ⁷Ferro J.K., 2017. The glossary of Prosthodontic Terms. 9 edition. J. Prosthet Dent., 117(5S):71.
- ⁸Jain R. and Aggarwal S., 2017. Precision attachments- an overview. Annals of prosthodontics and restorative dentistry, 3(1):6-9
- ⁹Munot V.K., Nayakar R.P. and Patil R., 2017. Prosthetic rehabilitation of mandibular defects with fixed RPD prosthesis using precision attachment: a twin case report. Contemp Clin. Dent., 8(3):473- 478.
- ¹⁰ Walid S., 1995. Bone anchored Andrew's bar system a prosthetic alternative. Cairo Dent. J., 11:11-5.

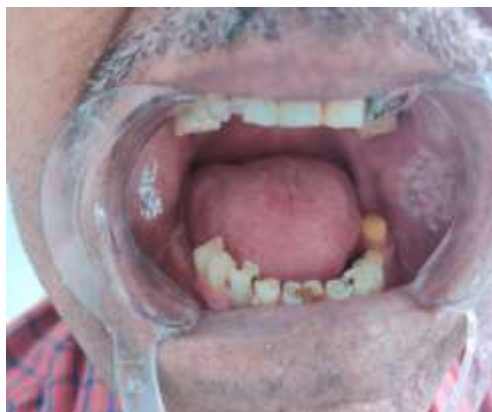

FIG1-PRE-OPERATIVE INTRAORAL VIEW

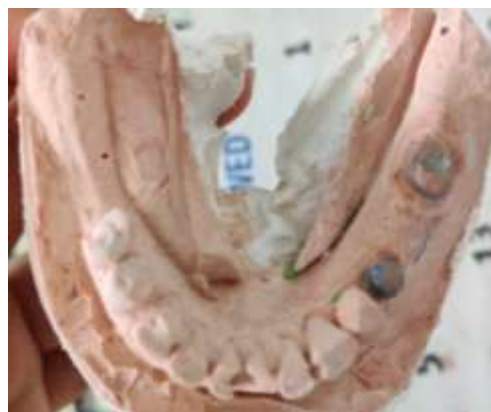

FIG 2- DIAGNOSTIC CAST

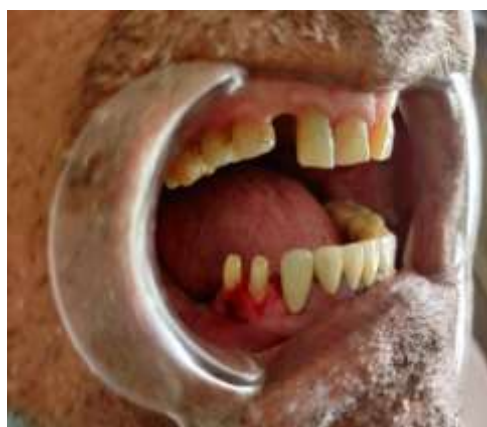

FIG 3- ABUTMENT PREPARATION IN 44,45

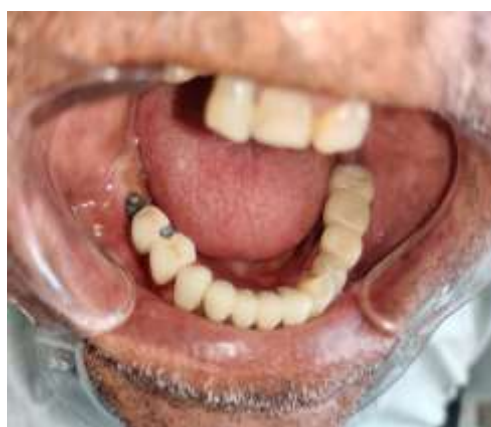

FIG 4-TRY IN OF THE MALE SECTION

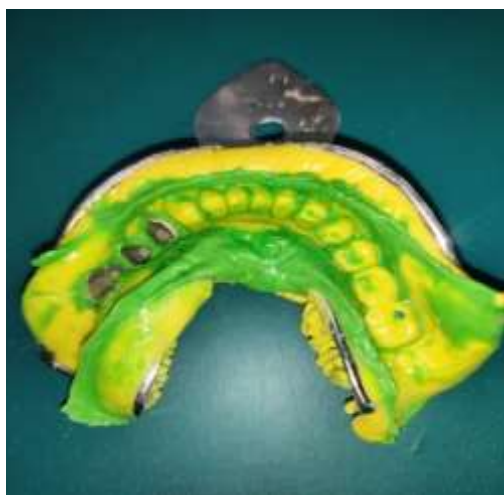


FIG 5- PICK UP IMPRESSION OF THE MALE SECTION

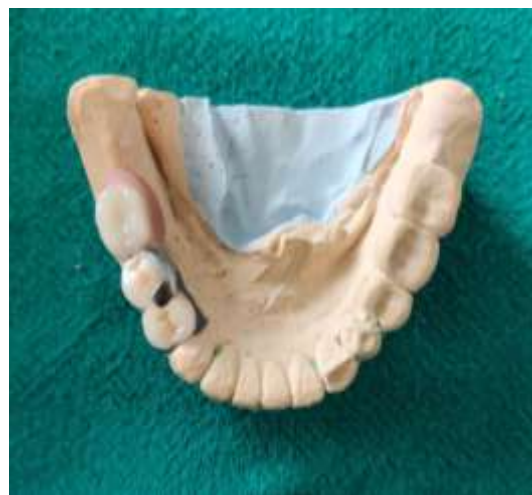

FIG 6- BOTH MALE AND FEMALE SECTION IN THE CAST

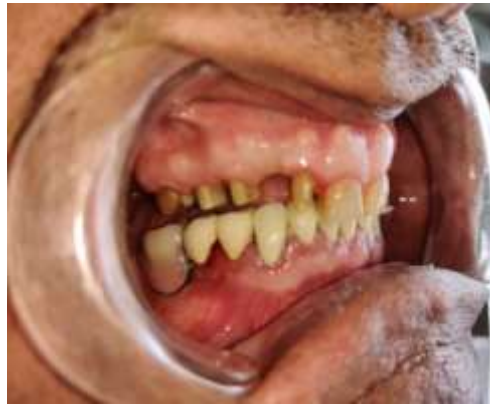

FIG 7- MAXILLARY TOOTH PREPARATION

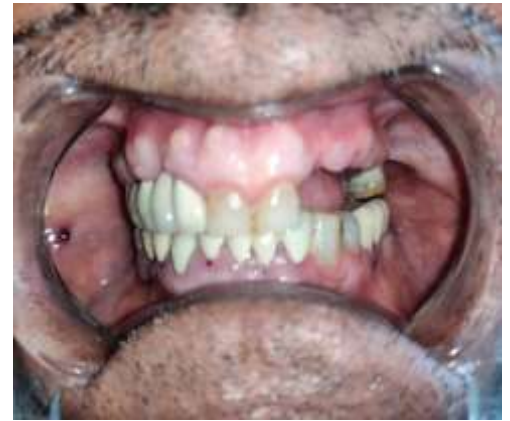

FIG 8- CEMENTED FPD AND CROWNS

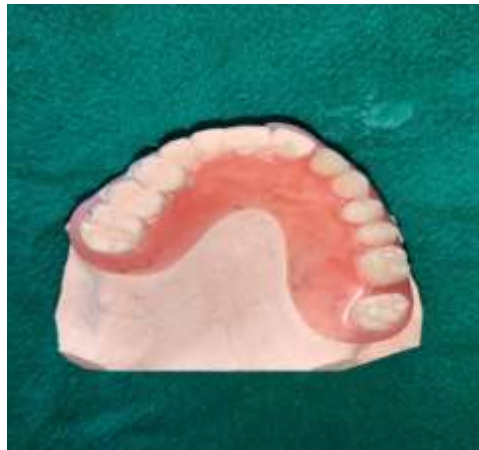

FIG 9- FLEXIBLE DENTURE

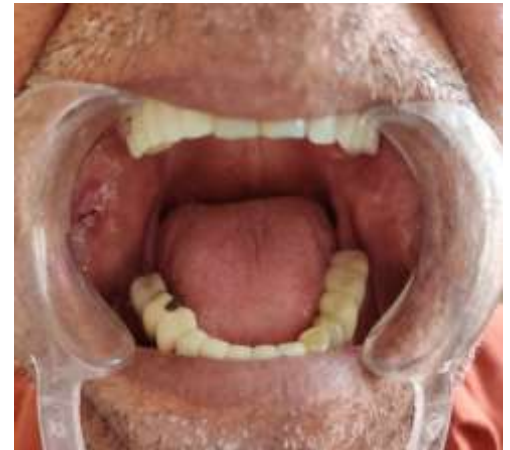

FIG 10-POST OPERATIVE

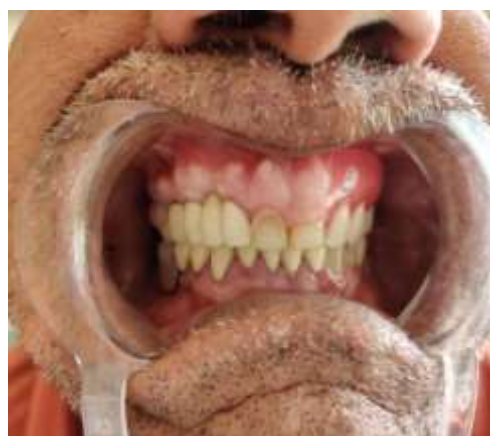

FIG 11- IN OCCLUSION