

Case Report

UNILATERAL EXTRACTION: A CASE REPORT

Dr. Gaurav Sharma, Rajasthan University of Health Science, drgouravs1983@gmail.com

Dr. Neeta Singh, Rajasthan University of Health Science, neetasingh0511@gmail.com

Dr. Athira Muralidharan, Rajasthan University of Health Science, athiramurali124@gmail.com

Dr. Rashmi Puri, Rajasthan University of Health Science, rashmipuri38@gmail.com

Dr Jitendra Soni, Rajasthan University of Health Science, soni.zeet@gmail.com

Abstract:

Crowded teeth have a major negative influence on the dentomaxillary system. This article reports on the treatment of crowding with unilateral premolar extraction. A 22-year-old male presented with crowding of the upper and lower anterior teeth and buccally placed 13. The patient had a chief complaint of irregular upper and lower front teeth. Clinical examination showed a Class I relationship for the teeth, and cephalometric measurements showed a Class I skeletal tendency. The right upper and lower first premolars were extracted for anterior crowding correction, and a segmented T loop was used for canine retraction in the right upper arch. It is concluded that upper-first premolar extraction is one of the options in the treatment of crowding. Unilateral premolar extraction treatment can be performed to achieve a functionally stable occlusion and an aesthetically pleasing appearance for the patient.

Keyword: unilateral extraction, crowded, T loop, orthodontic treatment

INTRODUCTION:

The treatment for dental crowding varies according to the magnitude of the problem. This therapy may involve follow-up to develop and correct the occlusion. However, this is not always the case, and correction may occur spontaneously in patients with slight crowding (up to 2 mm); cases of severe crowding (>9 mm) may require more extensive therapy with tooth extractions. Severe crowding caused by tooth size and arch length deficiency may be treated at an early stage with serial tooth extractions in the early mixed dentition (first transitory period) or with late extraction of the premolars in the permanent dentition.¹

The main goal of orthodontic treatment is to obtain a positive relationship between the teeth and facial structures. Preservation of all dental units was mandatory to achieve facial balance, harmony, and esthetics. However, some studies related to the stability of treatments pointed out the necessity of tooth extractions in order to correct malocclusions.²

Therefore, asymmetric extractions would be necessary and important to correct midline deviation for unilateral movement of the posterior teeth, reduce treatment time and tooth movement, facilitate orthodontic mechanics, and obtain more stable and functional results. Segmented T-loops favored the buccally placed canine.

CASE REPORT**DIAGNOSIS AND AETIOLOGY**

A 22-year-old male patient had reported to the Department of Orthodontics with the chief complaint of irregular upper and lower front teeth. A facial photograph showed a straight profile. On intraoral examination, it was observed that the maxillary midline and mandibular midline were coinciding; the patient had a Class I molar relationship on both sides, and the canine relationship was Class III. Anterior crossbite was seen in 12 and 43. The maxillary arch was symmetric and U-shaped, and the mandibular arch was wide, symmetric, and U-shaped. The cephalometric findings revealed a hypodivergent growth pattern with a Class I skeletal base [Figure 2]. An orthopantomogram was also recorded [Figure 2].

FIGURE 1: EXTRAORAL AND INTRAORAL PRE-TREATMENT PHOTOGRAPHS

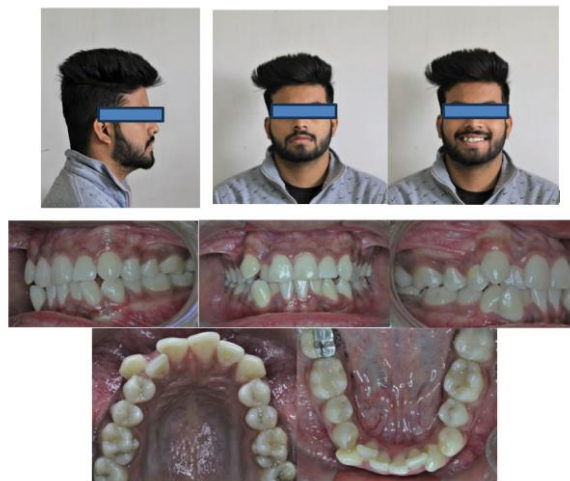
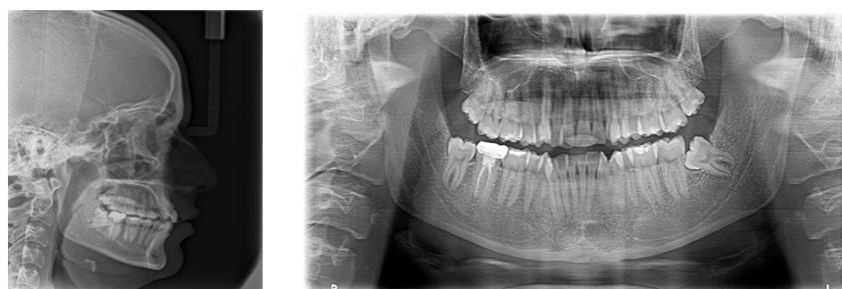
FIGURE 2: PRE-TREATMENT RADIOGRAPHS

**Treatment plan**

On considering the diagnostic criteria, a decision was made for unilateral first premolar extractions on the right side, alignment of the dentition into the arches, and retraction of the right upper canine with a segmented T loop (with a 0.017 x 0.025 TMA wire).

Treatment progress

Preadjusted edgewise MBT.022 slot brackets were bonded in the upper and lower arches, and initial alignment using 016 NiTi wire was done without involving the blocked-out canine in the continuous wire. The extraction of the maxillary right first premolar was carried out. After sufficient space had been created, the right maxillary canine was bonded and aligned within the arch using a segmented T-loop. The mandibular right first premolar was

extracted to maintain the canine relationship and the overbite. The mandibular left canine was retracted into the extraction space using an active tieback. Space created was used for the correction of crowding of the mandibular incisors and midline correction.

FIGURE 3: SEGMENTED T-LOOP GIVEN FOR 13 RETRACTIONS

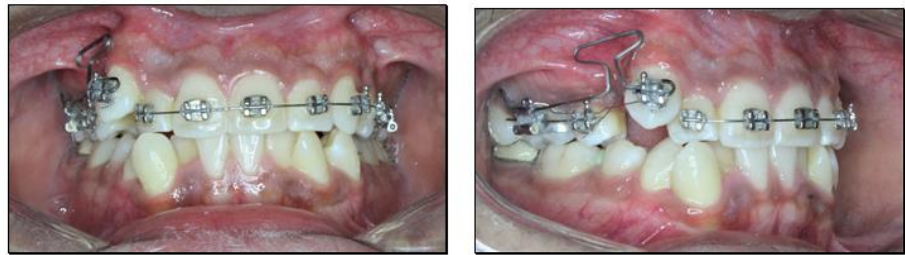
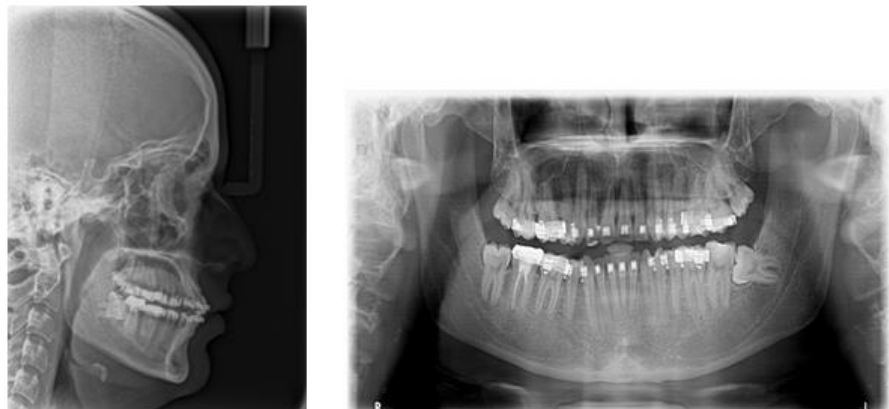


FIGURE 4: INTRAORAL TREATMENT PROGRESS

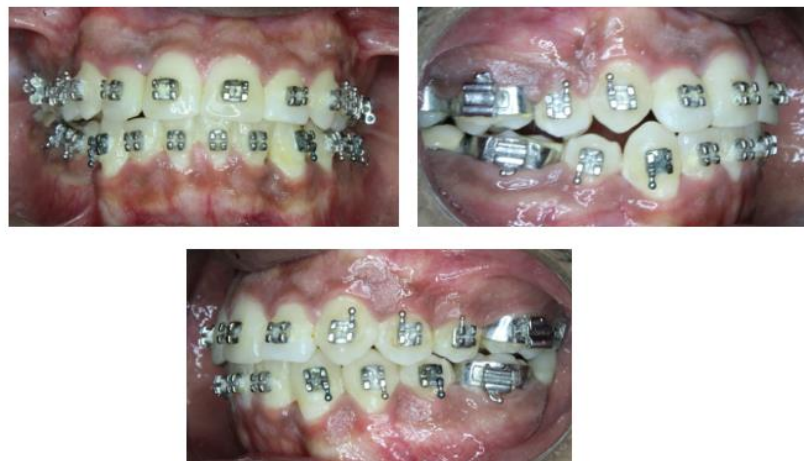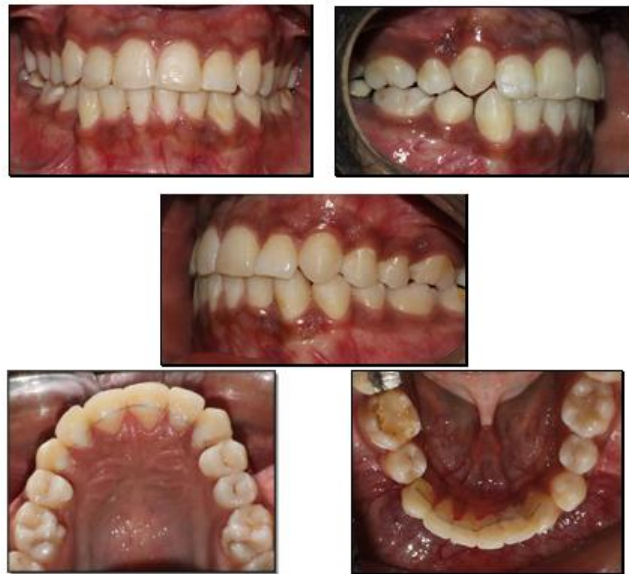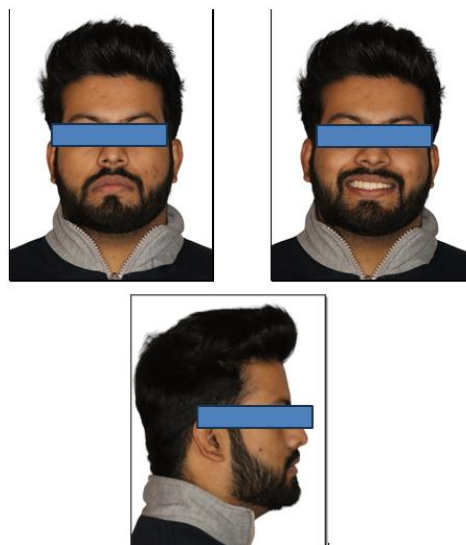


FIGURE 5: INTRAORAL RADIOGRAPHS (IN TREATMENT PROGRESS)



TREATMENT RESULTS

An ideal Class I occlusion was achieved in the patient with a positive overbite and overjet. The smile appearance improved along with the esthetic profile of the patient, which was maintained. The upper and lower midline coincided with each other. The treatment result justified all the methods used along with the input material as well as the psychological aspect.

FIGURE 6: INTRAORAL POST-TREATMENT PHOTOGRAPHS**FIGURE 7: POST-TREATMENT EXTRAORAL PHOTOGRAPHS**

DISCUSSION

The present case was of a non-growing male patient with buccally placed canine and anterior crossbite irt 12 and 43. Malocclusions with ectopically erupted canines are typically dealt with through all four first premolar extractions.³⁻⁹ The decision regarding the extraction or non-extraction treatment plan is based on the amount of arch-length tooth material discrepancy and the facial profile of the patient. According to Proffit and Fields, teeth length arch period discrepancies beneath four mm teeth extraction are hardly ever required, while discrepancies between five mm and nine mm permit remedy to be achieved without or with extractions, relying on the traits of the patient. In our patient, the tooth size-arch length discrepancy was 9 mm in the maxillary arch and 9 mm in the mandibular arch. Thus, it no longer suggests the extraction of all first premolars, as is robotically observed in instances with ectopic canines.¹⁰⁻¹²

The desire to extract teeth for orthodontic treatment ought to no longer be primarily based on the space between teeth but also on different factors, including the appearance and stability of the face.

According to Ramos et al., after 1 mm of retraction of the upper incisors, the upper lip retracts by 0.75 mm.¹³ Incisor retraction of 1 mm results in upper lip

retraction of 0.64 mm. For each 1 mm of lower incisor retraction, the lower lip retracts 0.6 mm. In our case, the patient has a pleasing profile. Thus, it did not indicate the extraction of all four first premolars, which would have resulted in a retrusive profile. A treatment plan was devised in such a way that space could be created for the blocked-out canine.

While correcting the position of a highly placed canine, it should not be engaged in the continuous wire so as to avoid the intrusive side effect on the adjacent lateral incisor. Once the canine is brought close to the occlusal plane, it can be aligned into the arch using continuous archwire mechanics.

Elastics were required in this patient for coordination of the maxillary and mandibular midlines. Midline shift can occur as a result of unilateral or asymmetric extractions; thus, coordination of midlines should be undertaken carefully in these cases.

CONCLUSION

Unilateral extractions can give good aesthetic results with stable occlusion that maintains a good impact on the dentomaxillary system. It should be undertaken carefully to prevent midline shift and the development of arch asymmetry during asymmetric or unilateral extraction treatment methods. An ideal Class I occlusion was achieved in this case with improved smile esthetics while maintaining the pleasing and esthetic profile of the patient.

Asymmetric or unilateral extractions could simplify and facilitate orthodontic treatment and mechanics in some specific cases. As a result, the first molar relationship could differ on the right or left sides, but this asymmetry would not cause functional or aesthetic problems for the patient.

REFERENCES

1. Felicita AS. Orthodontic management of a dilacerated central incisor and partially impacted canine with unilateral extraction: A case report. *The Saudi Dental Journal*. 2017 Oct 1;29(4):185–93.
2. Adiwirya MS, Purwanegara MK. Orthodontic Management of Maxillary Canine-First Premolar Transposition by Unilateral Extraction. *Journal of Dentistry Indonesia*. 2019;26(1):44–50.
3. Filho HL, Maia LH, Lau TC, de Souza MM, and Maia LC. Early vs. late orthodontic treatment of tooth crowding by first premolar extraction: A systematic review. *The Angle Orthodontist*. 2015 May 1;85(3):510–7.
4. Araújo TM, Caldas LD. Tooth extractions in orthodontics: first or second premolars?. *Dental press journal of orthodontics*. 2019 Aug 1;24:88–98.
5. Zimmer B, Schelper I, and Seifi-Shirvande N. Localized orthodontic space closure for unilateral aplasia of lower second premolars. *The European Journal of Orthodontics*. 2007 Apr 1;29(2):210–6.
6. Struhs TW. Effects of unilateral extraction treatment on arch symmetry and occlusion.
7. Melgaço CA, Araújo MT. Asymmetric extractions in orthodontics. *Dental Press Journal of Orthodontics*. 2012;17:151-6.
8. Dahiya GD. Effects of Unilateral Premolar Extraction Treatment on the Dental Arch Form of Class II Subdivisions (Doctoral dissertation, University of Illinois at Chicago).
9. Sitasari PI, Syahdinda MR, and Triwardhani A. Management of Angle Class I malocclusion with crowding and anterior crossbite by unilateral premolar extraction. *Makassar Dental Journal*. 2023 Aug 1;12(2):167–70.
10. Bolton, WA. Disharmony in tooth size and its relation to the analysis and treatment of malocclusion. *The Angle Orthodontist*. 1958 Jul 1;28(3):113-30.
11. Karanth D., Shetty vs. Canine Retraction by Sectional Arch Technique:

Comparison of Characteristics between T Loop Retraction Spring and PG Retraction Spring J Ind Orthod Soc. 2002;35:17–27.

12. Dahiya G., A. Masoud, Viana G., A. Obrez, B. Kusnoto, & Evans. (2017). Effects of unilateral premolar extraction treatment on the dental arch forms of Class II subdivision malocclusions. American Journal of Orthodontics and Dentofacial Orthopedics, 152(2), 232–241.

13. Tayer, BH. The asymmetric extraction decision. The Angle Orthodontist. 1992 Dec 1;62(4):291–7.