

Acute Stroke as the Initial Presentation of Takayasu Arteritis: Rare but Not Infrequent

Pratap Singh¹, Sanjay Kumar², Subodh Kumar Mahto³, Ramesh Chand Meena⁴

Abstract

Takayasu arteritis is an idiopathic, autoimmune, large vessel vasculitis, mainly affecting the young adults. Its exact etiopathogenesis is not known and it has varied clinical presentations. Acute stroke as initial presentation of Takayasu arteritis is uncommonly reported. Herein we present a case of a 24-year-old female who came to our hospital emergency with sudden onset of weakness of left half of the body of one-day duration. Takayasu arteritis complicated with acute ischemic stroke was diagnosed on the basis of CT angiography findings. The patient was managed accordingly and discharged in a stable condition. Relevant literature is also reviewed. Although considered to be a rare disease, Takayasu arteritis is not infrequent. A high index of suspicion is required for early diagnosis, so as to reduce the significant morbidity associated with the disease.

Keywords: Takayasu arteritis, Cerebrovascular accident, Infarction

Introduction

Takayasu arteritis is an idiopathic, chronic, granulomatous inflammation of medium and large arteries with a predilection for aortic arch and its branches. It is for this reason that it is also known as aortic arch syndrome. The progressive inflammation leads to stenosis, fibrosis, thrombosis and aneurysm formation in the involved arteries. It presents usually in females of 2nd or 3rd decade of life. It is most commonly reported from Japan, Southeast Asia and Mexico.^{1,2} It has two phases: the pre-pulseless or nonspecific or systemic phase and a pulseless phase. The former is characterized by fever, night sweats, malaise, arthralgia and weight loss while the latter presents with damage to end organs by either ischemia or infarction. The most common symptom of Takayasu arteritis is Raynaud's phenomenon and limb claudication because subclavian artery is invariably involved (Table 1).

Table 1. Symptoms and Signs of Takayasu Arteritis

Signs and symptoms	Artery Involved
Arm claudication, Raynaud's phenomenon, asymmetric or absent pulses	Subclavian artery
Hypertension	Renal artery
Retinopathy	Retinal artery
Aortic regurgitation	Ascending aorta
Pulmonary hypertension	Pulmonary artery
Cardiac ischemia or congestive heart failure	Hypertension or aortic disease
Headache, dizziness, seizures, stroke	Intracranial or extracranial arteries

^{1,2}Associate Professor, ^{3,4}Resident, Department of Medicine, Dr Ram Manohar Lohia Hospital & PGIMER, New Delhi, India.

Correspondence: Dr. Sanjay Kumar, Department of Medicine, Lady Hardinge Medical College & Smt S.K Hospital, New Delhi.

E-mail Id: drsanjaykumar_30@yahoo.com

Orcid Id: <http://orcid.org/0000-0001-5688-4376>

How to cite this article: Singh P, Kumar S, Mahto SK et al. Acute Stroke as the Initial Presentation of Takayasu Arteritis: Rare but Not Infrequent. *J Adv Res Med* 2017; 4(1&2): 1-4.

ISSN: 2349-7181

Case Presentation

A 24-year-old married female presented with the chief complaint of sudden onset, non-progressive left-sided weakness of upper and lower limbs since one day. It was not associated with headache, vomiting, fever, seizure or loss of consciousness. There was no history of blurring of vision, facial deviation, nasal regurgitation or any other cranial nerve abnormality. There was also no history of rashes, joint pains, photosensitivity, malaise, loss of appetite, loss of weight, breathlessness, chest pain, palpitation, photophobia, head injury, claudication or Raynaud phenomenon. There was no past history of similar episode, intake of oral contraceptive pills, recurrent abortion, tuberculosis, diabetes mellitus, or hypertension. She had regular menses without menorrhagia or dysmenorrhea. She had one live issue, full-term normal vaginal delivery and no abortions. She was a non-smoker, non-alcoholic, no substance abuse or any high-risk behavior. She consumed mixed diet with regular bowel and bladder habits. No relevant family history was present.

On examination, the patient was conscious, oriented to time, place and person. The left pulse was 90 beats per minute, regular, normal volume, no special character, no radio-femoral delay. Right-sided carotid artery pulsations were feeble with absent brachial and radial pulses. Right lower limb arterial pulsations were palpable and equal to that of left lower limb. Right carotid bruit was clearly heard on auscultation. The blood pressure was unequal in bilateral upper limbs (left upper limb 130/80 mmHg, not recordable in right upper limb), whereas it was comparable in bilateral lower limbs (136/88 mmHg). The oral temperature was 98°F and respiratory rate was 16 breaths per minute and thoracoabdominal. There was no pallor,

icterus, cyanosis, pedal edema, clubbing, lymphadenopathy, neck swelling or skin rash. The jugular venous pressure was not raised.

On CNS examination, the higher mental function was within the normal limit. There was no neck rigidity and no sign of meningeal irritation. Bilateral pupils were normal size with normal direct and consensual light reflex. The fundus examination of both eyes did not reveal any abnormality. The cranial nerves and sensory system were not affected. The muscle bulk was normal and symmetrical bilaterally. Power in the right upper limb and lower limb was normal while it was zero in left upper and lower limbs. The left plantar reflex was mute. The sensory examination was within normal limits. Coordination and cerebellar signs were normal on right side whereas it could not be tested on the left side. Rest of the systemic examination did not reveal any abnormality.

Investigations

Her hemoglobin was 10.7 g/dL, total leukocyte count 6800/mm³, platelet count 2.1 L/mm³, packed cell volume 24%, random blood sugar 98 mg/dL, blood urea 11 mg/dL, serum creatinine 0.7 mg/dL, total bilirubin 0.8 mg/dL, serum sodium 143 meq/L, serum potassium 3.4 meq/L, total cholesterol was 106 mg/dL and triglyceride was 109 mg/dL. Her erythrocyte sedimentation rate (ESR) was persistently high; it varied between 51 and 63 mm 1st hour. Human immunodeficiency virus (HIV), HBsAg, and anti HCV were non-reactive. Anti-nuclear antibody and VDRL were also negative. The chest X-ray and electrocardiogram was within the normal limit. Non-contrast CT head showed subtle loss of insular ribbon, suggestive of hyperacute ischemic infarct in the right middle cerebral artery territory (Fig. 1).

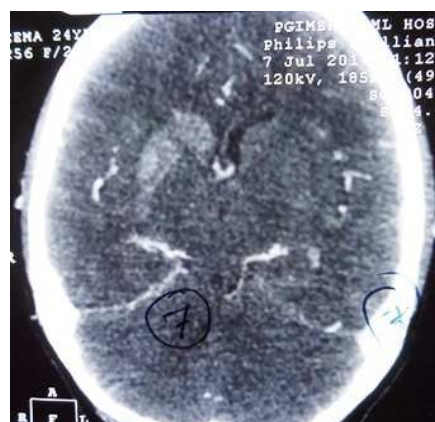

Figure 1. NCCT Scan Showing Hyperacute Ischemic Infarct in the Right MCA Territory

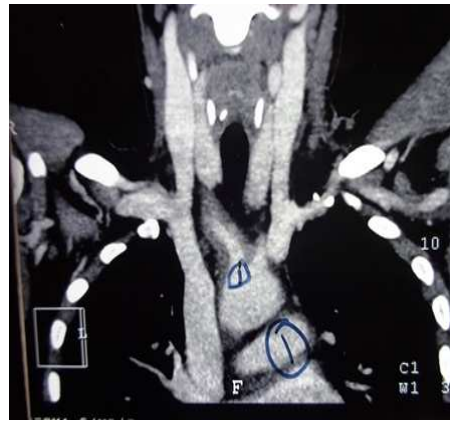


Figure 2. CT Aortography Showing Near Total Occlusions at Multiple Sites on Right Side as Described in Text

Doppler ultrasound of bilateral upper limb arteries showed biphasic flow with spectral filling and broadening in the left-sided subclavian, axillary, brachial, radial, and ulnar arteries. Right-sided arteries showed low resistance, monophasic flow with spectral broadening and increased acceleration time. No features to suggest occlusion or thrombosis was noted on either side. Two-dimensional echocardiography was essentially normal. Doppler ultrasound of bilateral carotid arteries showed marked wall thickening involving right common carotid artery with occlusion of the distal right common carotid artery. Left common carotid artery and its branches were normal. CT aortography was showing near-total occlusion of distal part of right subclavian, proximal part of right axillary artery, right common carotid artery at its origin to just proximal to its bifurcation and right internal carotid artery just beyond its origin up to its cavernous part (Fig. 2). Enhancing lesion is noted in right-sided caudate and lentiform nucleus suggestive of subacute infarct.

On the basis of history and examination, we kept a differential of large-vessel vasculitis (Takayasu arteritis), cerebrovascular accident (cardio-embolic or atherosclerosis) and infective arteritis (either tubercular or syphilitic).

The patient was started on anti-platelet, anti-lipidemic drug followed by steroids after diagnosis. Regular physiotherapy was done. Patient's general condition and motor power improved during hospital stay and she was discharged in a stable condition.

Discussion

Takayasu arteritis, also known as pulseless disease, thromboangiopathy and Martorell syndrome, is characterized by chronic large-vessel inflammation leading to wall-thickening fibrosis, stenosis and thrombosis, predominantly involving the aorta and its

branches. It was first described by Takayasu,³ a Japanese ophthalmologist in 1905. He described a 21-year-old female with characteristic retinal arterio-venous anastomosis, syncope and absent upper extremity pulses. Neurological involvement is not common in Takayasu arteritis and stroke as first presentation of disease is relatively rare.⁴ There is wide variation in the incidence, gender predisposition, disease morbidity and mortality reported in Takayasu arteritis across the globe. Etiology of Takayasu arteritis is unknown, but recent evidence suggests an association with certain human leukocyte antigen (HLA) alleles and other autoimmune processes like sarcoidosis and inflammatory bowel disease. It is also shown that tuberculosis may have deep association, given a high prevalence of active and past infection in patient with Takayasu arteritis.⁵ Non-specific features include fever, weight loss, arthralgia, myalgia, malaise and anemia. As inflammation progresses stenotic lesions develop and the patient develops associated symptoms and signs of diminished or absent pulses, vascular bruits, hypertension, retinopathy, aortic regurgitation, congestive heart failure and unusually neurological manifestations also. Panja's series of 650 cases of Takayasu arteritis, the largest series, reported an incidence of stroke of 22%. In 1990, the American College of Rheumatology proposed the criteria for Takayasu arteritis diagnosis: age at disease onset ≤ 40 years, claudication of the extremities, decrease brachial artery pulse, systolic blood pressure difference >10 mmHg in upper limbs, bruit over subclavian artery or aorta and radiographic abnormalities. The presence of three out of six criteria is required for a diagnosis and demonstrates a sensitivity of 90.5% and specificity of 97.8%.⁶

Doppler ultrasound, CT angiography (CTA), and recently magnetic resonance angiography (MRA) have shown promise in the diagnosis of Takayasu arteritis.⁷ MRA provides high resolution details of vessel wall

thickness and lumen configuration. It allows the measurement of wall enhancement as a reflection of edema and inflammation. Compared to the gold standard of angiography, 2% of stenosed vessels are over estimated as occluded on MRA. By reduction of enhancement on follow up, MRA also serves as a surrogate marker for disease activity. Steroids are the mainstay of treatment and approximately half of the patients respond to it. Steroids-unresponsive patients can be treated with cytotoxic drugs like cyclophosphamide, azathioprine and methotrexate. Some studies have reported the use of several immunosuppressive agents such as methotrexate, mycophenolate mofetil and azathioprine.⁸ Anti-TNF therapy has also been used successfully in a few patients.⁹ Surgical treatment is offered to those with severe stenosis of renal artery, extremity claudication, stenosis of three or more cerebral vessels or evidence of coronary artery involvement. Immediate priorities in treatment must address acute vascular compromise through either medical treatment with thrombolytics or surgical intervention. Long-term treatment is targeted at decreasing vessel inflammation and progression of vascular disease and controlling comorbid conditions. Cumulative survival at 5 years after disease onset was 91%, and after 10 years the figure was 84%.

Our patient had asymmetry of blood pressure in upper limbs with absent pulses in right upper limb. She presented with acute ischemic stroke caused by atheroembolic process, which was diagnosed immediately with clinical clue and CTA. The patient was given steroids and decongestant therapy to which she responded well.

Conflict of Interest: None

Conclusion

This case highlights the importance of palpation of all peripheral pulses and recording blood pressure in all four limbs at least in young stroke patients. Although

neurological manifestations are common in patients with Takayasu arteritis in the chronic phase, acute stroke as an initial presentation has rarely been reported. Our patient shows that Takayasu arteritis should also be considered in the differential diagnosis of young stroke. Early identification and continuous medical management will prevent these individuals in developing permanent stenotic lesions with better outcome.

References

1. Numano F, Okawara M, Inomata H et al. Takayasu's arteritis. *Lancet* 2000; 356: 1023-25.
2. Koide K. Takayasu arteritis in Japan. *Heart Vessels Suppl* 1992; 7: 48-54.
3. Takayasu M. A case with peculiar change of retinal vessels [in Japanese]. *Acta Ophthal Soc Japan* 1908; 12: 554-55.
4. Sikaroodi H, Motamedi M, Kahnooji H et al. Stroke as the first manifestation of Takayasu arteritis. *Acta Neurol Belg* 2007 Mar; 107(1): 18-21.
5. Johnston SL, Lock RJ, Gompels MM. Takayasu arteritis: A review. *J Clin Pathol* 2002; 55: 481-86.
6. Arend WP, Michel BA, Bloch DA et al. The American college of Rheumatology 1990 criteria for the classification of Takayasu arteritis. *Arthritis Rheum* 1990 Aug; 33(8): 1129-34.
7. Choe YH, Kim DK, Koh EM et al. Takayasu's arteritis: Diagnosis with MR imaging and MR angiography in acute and chronic active stages. *J Magn Reson Imaging* 1999; 10: 751-57.
8. Valsakumar AK, Valappil UC, Jorapur V et al. Role of immunosuppressive therapy on clinical, immunological, and angiographic outcome in active Takayasu's arteritis. *J Rheumatol* 2003 Aug; 30(8): 1793-98.
9. Hoffman GS, Merkel PA, Brasington RD et al. Anti-tumor necrosis factor therapy in patients with difficult to treat Takayasu arteritis. *Arthritis Rheum* 2004 Jul; 50(7): 2296-2304.

Date of Submission: 10th Jul. 2017

Date of Acceptance: 12th Jul. 2017