

ORIGINAL ARTICLE**COMPARISON OF ENDOFLAS AND ZINC OXIDE EUGENOL AS ROOT CANAL FILLING MATERIALS IN PRIMARY DENTITION**

Tarunvir Singh Rai¹, Inderdeep Kaur², Lakshay Dhawan³, Geetanjali³, Shazia Shafat⁴, Inderpreet Singh Oberoi⁵

¹BDS, Canada, ²BDS, Canada, ³BDS Intern, Dasmesh Dental College, Faridkot, Punjab, India, ⁴Pedodontist, Private practitioner, ⁵PG Scholar, Department of Oral Medicine and Radiology, Govt. Dental College & Hospital, Sri-Nagar

ABSTRACT:

Background: An ideal root canal filling material must possess the necessary properties of being antibacterial, resorbable at the same rate of the root and harmless to periapical tissues and the developing tooth bud. We planned this study to compare endoflas and zinc oxide eugenol clinically after 3, 6, and 9 month's postoperative period. **Materials and methods:** For the study, sample comprising of 35 primary molars from among patients aged 4-9 years reporting to department were selected. The teeth having history of spontaneous pain, presence of an abscess or a fistula, gingival swelling, pain on percussion, and radiograph revealing inter-radicular radiolucency were included in the study. The selected teeth were randomly divided into two groups of 18 (endoflas, Group I) and 17 (zinc oxide eugenol, Group II) teeth. **Results:** Statistically significant difference ($P < 0.05$) was seen between the two groups at postoperative 3 months follow-up for pain and tenderness. There were no extractions or failures in the endoflas group. In contrast, four teeth had to be extracted in the zinc oxide eugenol group 2 weeks postobturation. Radio graphically, the teeth were assessed for changes in the interradicular radiolucency. In endoflas, 100% decrease was seen in the size of interradicular radiolucency at the end of 9 months. In zinc oxide eugenol, a decrease of 45% was observed. **Conclusion:** This study indicates that endoflas with a success rate of 100% is a much better material compared with zinc oxide eugenol and should be widely used as a root canal filling material for deciduous dentition considering the drawbacks of zinc oxide eugenol.

Keywords: Endoflas, pulpectomy, zinc oxide eugenol

Corresponding author: Dr. Tarunvir Singh Rai, Canada

This article may be cited as: Rai TS, Kaur I, Dhawan L, Geetanjali, Shafat S, Oberoi IS. Comparison of endoflas and zinc oxide eugenol as root canal filling materials in primary dentition. *Int J Res Health Allied Sci* 2016;3(1):1-5.

INTRODUCTION:

In pulpectomy is a treatment of choice of preserving a pulpally involved primary tooth by eliminating bacteria and their products and ensuring hermetic seal of the root canals so that the primary teeth can complete its function until normal exfoliation can occur without harming the successor or affecting the health of the patient.¹

An ideal root canal filling material must possess the necessary properties of being antibacterial, resorbable at the same rate of the root and harmless to periapical tissues and the developing tooth bud. In addition, it must easily fill the canals, adhere to the walls, not shrink, must readily resorb if passed beyond the apex, be easily removed if necessary, be radiopaque and causes no discoloration of the tooth. At present there is no such ideal material to meet all the requirements.²⁻⁴ Calcium hydroxide, vitapex, and metapex have been extensively used as root canal filling material in primary dentition despite various drawbacks that are associated with these materials. The main disadvantage of calcium hydroxide as root canal filling material is that it has a tendency to resorb earlier than the physiological resorption of root of primary teeth. This creates a "hollow tube" effect wherein an unfilled root canal is permeated with tissue fluid that eventually becomes a site for infection.⁵ Zinc oxide eugenol is

resistant to resorption and eventually might result in a deflected successor.^{6,7} Moreover, it has limited antibacterial efficacy.^{8,9}

Since 1930s, zinc oxide eugenol has been the material of choice, but it has certain disadvantages like slow resorption, irritation to periapical tissues, necrosis of bone and cementum and alters the path of eruption of succedaneous tooth.⁵⁻⁸ Thus Zinc Oxide Eugenol either alone or with a fixative like formocresol or Iodoform gave a success rate of 65-86%.⁹ The use of calcium hydroxide in permanent teeth has been well documented. Two isolated case reports found it was highly successful in primary teeth.¹⁰ Calcium hydroxide being antibacterial, resorbable and biocompatible can also be used in primary teeth.¹¹ Iodoform was found to have excellent healing properties with resorption of the excess material giving a success rate of 84-100%.¹² Dominguez et al, reported that when combining Iodoform and Calcium Hydroxide, it gave a success rate of 100%.^{13,14} But the main disadvantage was intra-radicular resorption of the material.^{15,16} A mixture of Calcium Hydroxide, Zinc Oxide Eugenol and Iodoform gave a success rate of 83% with good healing and resorptive capabilities and was said to be a good alternative to the traditionally used materials. Endoflas (Sanlor and Cia. S. en C.S., Cali, Colombia), produced in South America, comprises of triiodomethane, zinc oxide eugenol,

calcium hydroxide, barium sulfate, and iodine dibutylorthocresol with a liquid consisting of eugenol and paramonochlorophenol.¹⁷

Despite the numerous advantages that endoflas has over zinc oxide eugenol, it is still not the most widely employed material for root canal filling in a primary tooth. So, we planned this study to compare endoflas and zinc oxide eugenol clinically and radiographically after 3, 6, and 9 month's postoperative period.

MATERIALS AND METHODS:

For the study, sample comprising of 35 primary molars from among patients aged 4-9 years reporting to department were selected. Ethical approval for the study was taken from the ethical committee of the college. The children and their caretakers were invited to participate in the study. An informed written consent was obtained from the parents of the patients after educating them about the whole procedure. The teeth having history of spontaneous pain, presence of an abscess or a fistula, gingival swelling, pain on percussion, and radiograph revealing inter-radicular radiolucency were included in the study. Teeth having external/internal root resorption, extreme mobility, and a perforated pulpal floor were excluded from the study. The selected teeth were randomly divided into two groups of 18 (endoflas, Group I) and 17 (zinc oxide eugenol, Group II) teeth. The procedure of pulpectomy was performed by same investigator on all the patients. After 3, 6, and 9 months of postoperative period, patients were recalled for clinical and radiographic evaluation. Treatment was considered successful when there was absence of pain, redness, and swelling, tenderness on percussion, and sinus or fistula. For radiographic evaluation, two investigators were trained and calibrated. Radiographically, the treatment was considered successful in the case of a reduction in the size of interradicular radiolucency or the size remaining the same.

The procedure was carried out in a single visit using a rubber dam after administration of local anesthesia. The access to the chamber was obtained after removal of the carious tooth structure. The coronal pulp was removed with a spoon excavator. A radiograph was taken to confirm the working length. The working length was maintained 1 to 2 mm short of the radiographic apex to minimize the chance of over instrumentation apically and causing periapical damage. In case the unerupted permanent tooth bud was within the furcation area, the working length was limited to a level above the occlusal plane of the permanent tooth. However, if it was below the apices of the primary tooth, the entire length of the root was considered as the working length. H files were used to enlarge the canals till size 35. Irrigation was carried out using 2.5% sodium hypochlorite alternatively with saline. Root canal treatment in the

primary dentition unlike the permanent dentition is more of chemo mechanical preparation owing to the tortuosity of the canals. Paper points were used for drying the canals. A lentulo spiral mounted on a slow speed hand piece was employed to introduce endoflas and zinc oxide eugenol into the root canals. The access cavity, postobturation was sealed with a thick paste of zinc oxide eugenol, and a radiograph was taken to determine the extent of the filling. The root canal filling was followed by placement of preformed stainless steel crown using a standard technique. The analysis of reliability of data was done using SPSS software for windows. Chi-square test was used for the comparison of radiographic and clinical success rate of zinc oxide eugenol and endoflas. Statistical significance was considered at $P < 0.05$.

RESULTS:

Thirty five primary molars were endodontically treated in children ranging in the age group of 4-9 years. The selected teeth were randomly divided into two groups of 18 and 17 teeth and were filled with endoflas (Group I) and zinc oxide eugenol (Group II), respectively [Table 1]. The patients were randomly divided into two groups, group 1 (Endoflas) and group 2 (Zinc Oxide Eugenol). The age range of patients was from 4-9 years. In the age group 4-6 years, there were total 7 patients, of whom randomly five patients were placed into group 1 and two patients into group 2. In the age group 6-7 years of age, there were total 13 patients, of whom randomly six patients were placed into group 1 and seven patients in group 2. In the age group 8-9 years, there were total 15 patients, of whom randomly seven patients were placed into group 1 and eight patients into group 2 [Table 1]. Preoperative signs and symptoms were evaluated for pain, soft tissue, redness, mobility, intraoral swelling, draining sinus, and tenderness on percussion. Postoperative signs and symptoms and radiographic assessment of the size of the interradicular radiolucency were recorded after 3, 6, and 9 months [Figure 1] and [Table 2].

The preoperative and postoperative clinical signs and symptoms are tabulated [Table 2]. Statistically significant difference ($P < 0.05$) was seen between the two groups at postoperative 3 months follow-up for pain and tenderness. There were no extractions or failures in the endoflas group. In contrast, four teeth had to be extracted in the zinc oxide eugenol group 2 weeks postobturation. Radio graphically, the teeth were assessed for changes in the interradicular radiolucency. In endoflas, 100% decrease was seen in the size of interradicular radiolucency at the end of 9 months. In zinc oxide eugenol, a decrease of 45% was observed. The overall clinical and radiographic findings in this study reveal 83% success in zinc oxide eugenol compared with 100% success in the endoflas group.

Table 1: Age and gender wise distribution of the sample

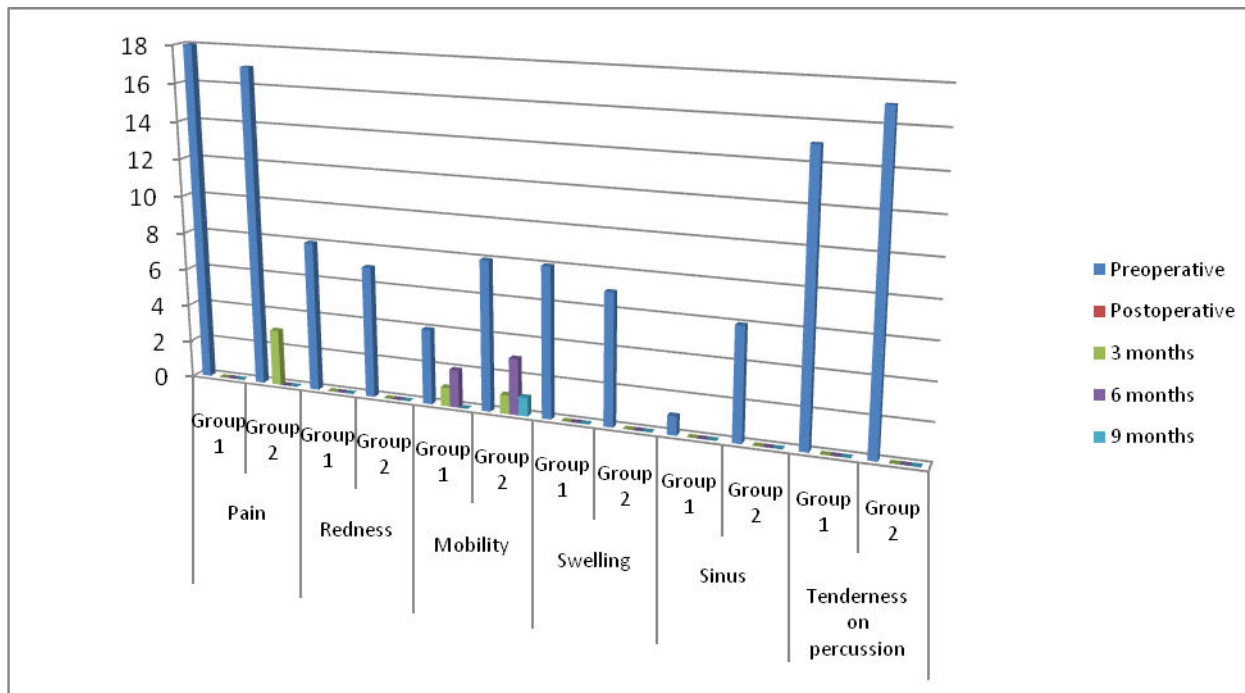
Age	Total	Group 1, ENDOFLAS			Group 2, ZINC OXIDE EUGENOL		
		N	Male	Female	N	Male	Female
4-6 years	7	5	3	2	2	1	1
6-7 years	13	6	3	3	7	4	3
8-9 years	15	7	3	4	8	5	3

Table 2: Comparison of clinical parameters preoperatively and postoperatively in Groups 1 and 2

Follow up period	Pain		Redness		Mobility		Swelling		Sinus		Tenderness on percussion	
	Group 1	Group 2	Group 1	Group 2	Group 1	Group 2	Group 1	Group 2	Group 1	Group 2	Group 1	Group 2
Preoperative	18	17	8	7	4	8	8	7	1	6	15	17
Postoperative												
3 months	0*	3*	0	0	1	1	0	0	0	0	0*	0*
6 months	0*	0*	0	0	2	3	0	0	0	0	0*	0*
9 months	0*	0*	0	0	0	1	0	0	0	0	0*	0*

*p<0.05

Figure 1: Comparison of clinical parameters preoperatively and postoperatively in Groups 1 and 2



DISCUSSION:

Zinc oxide eugenol and Calcium Hydroxide are the most commonly used root canal filling materials. Castagnola showed that iodoform pastes are bactericidal to microorganisms in the root canal and lose only 20% of the potency over a 10-year period.³ But Zinc oxide eugenol pastes are not bactericidal, unless mixed with drugs, such as formocresol. Due to various side effects of formaldehyde, the use of it is questionable.¹⁸ Healing depends on the ability of the root canal filling material to promote natural healing functions of periapical tissues of primary teeth.

This study reported immediate postoperative extractions in the zinc oxide eugenol group, which can be explained on the basis that zinc oxide eugenol is periapical irritant and utmost care should be taken not to force material past the apex.¹⁹ Second, it has a limited antibacterial activity. It is important that root canal filling material used in primary teeth should destroy the microorganisms in tissues as complete mechanical debridement is not possible due to the complexity of root canal system.²⁰ Anna Fuks et al. conducted retrospective study to report the success rate of root canal treatments (RCT) using Endoflas as a filling material in primary teeth. Fifty-five (55 teeth,

27 maxillary incisors and 28 molars) of 47 children fulfilled the criteria to be included in the study. The immediate post-operative radiograph was evaluated and the root filling was rated overfilled, flush or underfilled. Thirty-one (31) teeth were overfilled; of these 9 (29%) were normal pre-operatively and the remaining 22 (71%) presented with bone pathology. Twenty-four (24) teeth were flush or underfilled; of these, 50% had preoperative bone pathology. The children were examined clinically and radiographically at follow-up visits ranging from 6 to 52 months. Approximately 70% of the cases were successful at the last followup examination. The remaining 30% presented with pathology (Po); however, only one tooth had to be extracted (Pi). Overfilling led to a success rate of 58%, while in the combined flush and underfilled the success rate was 83%.²¹

PriyaSubramaniam et al. conducted study to evaluate and compare the efficacy of Endoflas, zinc oxide eugenol and Metapex as root canal filling materials. A total of forty-five primary molars from children aged 5-9 years were selected for a one stage pulpectomy procedure. Teeth were randomly divided into three groups of fifteen teeth each based on the type of root canal filling material used. All the molars were evaluated clinically and radiographically at regular intervals of 3, 6, 12 and 18 months. The observations were tabulated and statistically analyzed. Endoflas and zinc oxide eugenol showed 93.3% success, whereas a higher percentage of success was observed with Metapex (100%). Overfilling and voids were more commonly seen in teeth filled with Metapex. The authors concluded that there was no significant difference between the three root canal filling materials.²²

K Ramar undertook a study to evaluate clinically and radiographically the efficacy of three obturating materials - Calcium hydroxide with Iodoform (METAPEX), Zinc Oxide Eugenol with Iodoform (RC FILL) and Zinc Oxide Eugenol and Calcium hydroxide with Iodoform (ENDOFLAS) for a period of 9 months. Results showed ENDOFLAS gave an overall success rate of 95.1%, METAPEX - 90.5% and RC FILL - 84.7%. Authors concluded that ENDOFLAS, a mixture of Zinc Oxide Eugenol and Calcium hydroxide with Iodoform fulfills most of the required properties of an ideal root canal filling for primary teeth.

In this study, retention of extruded zinc oxide eugenol in four canals was present at 9-month follow-up. In comparison, there was no retention of excess material in the teeth, which were filled with endoflas. The study observed that endoflas unlike any other material employed for pulpectomy resorbs at the same pace as the physiological resorption of root. This factor results in the resorption of the material limited to the excess extruded extraradicularly without showing any signs of resorption intraradicularly. This study reported high clinical as well as radiographic success of endoflas over zinc oxide eugenol. Despite the drawbacks of zinc oxide eugenol, it is

still the most widely employed root canal material for the primary teeth.

CONCLUSION:

This study indicates that endoflas with a success rate of 100% is a much better material compared with zinc oxide eugenol and should be widely used as a root canal filling material for deciduous dentition considering the drawbacks of zinc oxide eugenol.

REFERENCES:

1. Rosendahl R, Weinert-Grodd A. Root canal treatment of primary molars with infected pulps using calcium hydroxide as a root canal filling. *J ClinPediatr Dent* 1995;19:255-8.
2. Rifkin A. A simple, effective, safe technique for the root canal treatment of abscessed primary teeth. *J Dent Child* 1980;47:435-41.
3. Castagnola L, Orlay HG. Treatment of gangrene of the pulp by the Walkoff method. *Br Dent J* 1952;93:93-102.
4. Woods RL, Kildea PM, Cabriel. A histologic study of hydron and Zincoxideeugenol as endodontic filling material in primary teeth of dogs. *Oral Surg* 1984;58:92-3.
5. Goldman M, Pearson AH. A preliminary investigation of the "Hollow Tube" theory in endodontics: Studies with neotetrazolium. *J Oral Ther Pharmacol* 1965;1:618-26.
6. Sadrian R, Coll JA. A long-term follow-up on the retention rate of zinc oxide eugenol filler after primary tooth pulpectomy. *Pediatr Dent* 1993;15:249-53.
7. Kennedy DB. *Pediatric Operative Dentistry. Dental Practitioner Handbook No. 21.* Bristol: John Wright and Sons; 1976. p. 232-9.
8. Tchaou WS, Turng BF, Minah GE, Coll JA. Inhibition of pure cultures of oral bacteria by root canal filling materials. *Pediatr Dent* 1996;18:444-9.
9. Cox STJr, HembreeJHJr, McKnight JP. The bactericidal potential of various endodontic materials for primary teeth. *Oral Surg Oral Med Oral Pathol* 1978;45:947-54.
10. Rosendhal K, WeinertGrodd A. Root canal treatment of primary molars with infected pulps using Calcium Hydroxide as a root canal filling. *J ClinPediatr Dent* 1995;19:255-8.
11. Sjogren U, Figdor D, Spangberg L, Sundqvist G. The antimicrobial effect of calcium hydroxide as a short term intra canal dressing. *Int Dent J* 1991;24:119-25.
12. Reddy VV, Fernandes. Clinical and radiological evaluation of Zinc oxide eugenol and Maisto's paste as obturating materials in infected primary teeth: A nine months Study. *J Indian SocPedodPrev Dent* 1996;14:39-44.
13. Dominguez RA, Solano R. Root canal treatment in necrotic primary molars. *J Pedodont* 1989;14:36-40.
14. Garcia-Godoy F. Evaluation of an iodoform paste in root canal therapy for infected primary teeth. *J Dent Child* 1987;54:30-4.
15. Nurko C, Ranly DM, Garcia-Godoy F, Lakshmyya KN. Resorption of a Calcium hydroxide/ iodoform paste (Vitapex) in root canal therapy for primary teeth: A case report. *Pediatr Dent* 2000;22:517-20.
16. Nurko C, Garcia Godoy F. Evaluation of a calcium hydroxide/ iodoform paste (Vitapex) in root canal therapy for primary teeth. *J ClinPediatr Dent* 1999;23:289-94.

17. Fuks A, Eidelman E, Pauker N. Root fillings with Endoflas in primary teeth: A retrospective study. *J ClinPediatr Dent* 2002;27:41-6.
18. Barker BC, Lockett BC. Endodontic experiments with resorbable pastes. *Aus Dent J* 1971;16:364-72.
19. Erausquin J, Muruzábal M. Root canal fillings with zinc oxide-eugenol cement in the rat molar. *Oral Surg Oral Med Oral Pathol* 1967;24:547-58.
20. Garcia-Godoy F. Evaluation of an iodoform paste in root canal therapy for infected primary teeth. *ASDC J Dent Child* 1987;54:30-4.
21. Anna Fuks, EliezerEidelman, and NitayPauker (2003) Root fillings with Endoflas in primary teeth: a retrospective study. *Journal of Clinical Pediatric Dentistry*: September 2003, Vol. 27, No. 1, pp. 41-45.
22. PriyaSubramaniam and KanupriyaGilhotra (2011) Endoflas, Zinc Oxide Eugenol and Metapex as Root Canal Filling Materials in Primary Molars—A Comparative Clinical Study. *Journal of Clinical Pediatric Dentistry*: July 2011, Vol. 35, No. 4, pp. 365-370.

Source of support: Nil

Conflict of interest: None declared

This work is licensed under CC BY: **Creative Commons Attribution 3.0 License.**