

# MANAGEMENT OF HORIZONTAL ROOT FRACTURE – A CASE REPORT

Bose S,<sup>1</sup> Yeluri R,<sup>2</sup> Garg N,<sup>3</sup> Lumbini P<sup>4</sup>

1. Post Graduate Student, Department of Pedodontics, Teerthanker Mahaveer Dental College & Research Center, Moradabad, Uttar Pradesh.
2. Professor & Head, Department of Pedodontics, Teerthanker Mahaveer Dental College & Research Center, Moradabad, Uttar Pradesh.
3. Reader, Department of Pedodontics, Teerthanker Mahaveer Dental College & Research Center, Moradabad, Uttar Pradesh.
4. Senior Lecturer, Department of Pedodontics, Teerthanker Mahaveer Dental College & Research Center, Moradabad, Uttar Pradesh.

## Abstract

**Background:** Root fracture is a complex injury that involves periodontal ligament, pulp, dentin and cementum. These injuries constitute <3% of all dental injuries affecting most commonly the maxillary central incisors. Immediate management of such type of traumatic injuries provides favourable prognosis.

**Aim:** The present case report aims to illustrate the management of horizontal root fracture in a young child with a one year follow up.

**Case report:** The horizontal root fracture occurred at the middle third of the roots of maxillary central incisors with separation of the fragments. Immediate repositioning and splinting was carried out. The tooth was diagnosed with pulp necrosis and therefore endodontic treatment of coronal fragment of the fractured teeth was carried out leaving the apical fragment as such.

**Follow up:** After a follow up period of one year, there were no signs of complications clinically. Radiographically, healing by calcific tissue at the fractured sites was evident.

**Conclusion:** Management of horizontal root fracture served to preserve the structural and functional integrity of teeth in the oral cavity.

**Keywords:** Dental trauma; Horizontal Root Fracture; Splinting

## Introduction

One of the main causes of anterior permanent tooth loss is dental trauma. Upper central incisors are mostly vulnerable to traumatic injuries, being affected in 80% of dental trauma, followed by upper lateral incisors and lower incisors.<sup>1,2</sup> Considering the types of trauma, root fractures are less frequent, with prevalence of 0.5% to 7% in permanent dentition and 2 to 4% in deciduous teeth.<sup>3</sup> Similar to dental trauma in a general manner, these fractures occur mainly in central incisors (68%) and lateral incisors (27%), and only 5% in lower incisors.<sup>4</sup> It happens in consequence of an impact force at the top of the root and frontal forces in the compression zone directed to vestibular and lingual, dividing root in coronal and apical fragments. This division may cause harmful consequences to cement, dentin, pulp and periodontal tissues.<sup>5</sup> The prognosis of root fractures is favorable in 60- 80% cases, however complications such as pulp necrosis, root resorption and calcification of root canal may emerge.<sup>1</sup>

The present case report illustrates management of a case of horizontal root fracture in middle third region in an effort to preserve the esthetic integrity of anterior teeth.

## Case report

An 11 year old female patient reported to the Department of Pedodontics & Preventive Dentistry with history of trauma to upper front teeth two days before. She fell while playing which led to an impact injury to the maxillary central incisors. Clinically, soft tissue lacerations over lips, tongue and gingiva were observed. The teeth 11 & 21 were having grade II mobility, palatally extruded and tender to percussion; and there was bleeding from gingival tissue at the cervical region of the teeth. On radiographic exam, it was observed that both the upper central incisor presented

horizontal root fracture at the middle third region with separation of the fragments. [Figure 1 A & B]

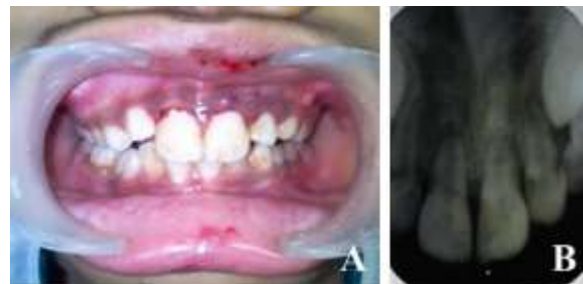

Figure 1: A) Preoperative intraoral view; B) Preoperative Intraoral Periapical Radiographic view

The treatment started with cleaning of the intraoral and extraoral lacerations followed by immediate repositioning of the extruded coronal fragments in the vertical direction with gentle finger pressure under local anesthesia. Splinting was carried out with composite wire splint for 2-4 weeks as recommended by Flores *et al.*<sup>6</sup> The position of teeth was verified radiographically and the patient was prescribed antibiotics and analgesics for three days. [Figure 2 A & B]

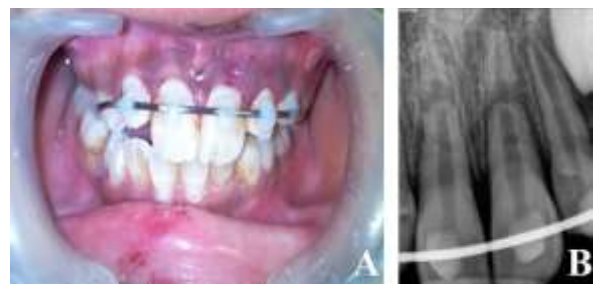

Figure 2: A) Stabilisation with composite wire splint; B) Radiograph after splinting

The patient returned for clinical and radiographic follow-up after one week. Electric and thermal pulp tests were performed and no response was observed for 11 & 21 indicating the possibility of pulpal necrosis of the coronal fragment. Root fractured teeth often possess a vital apical fragment;<sup>7,8</sup> hence it was decided to perform the endodontic treatment of the coronal fragment leaving the apical fragment as such.

The patient's parents were informed about the possible consequences and complications of the treatment. Conventional endodontic treatment was started in 11 & 21 while the splint still in its place. After access cavity preparation under local anesthesia, working length was determined upto the apex of coronal fragment. [Figure 3 A] This was followed by pulp extirpation and irrigations. Calcium hydroxide was placed as an intracanal medicament and was renewed every 2 weeks for 1 month. Meanwhile the splint was removed after successful stabilisation of the teeth. After biomechanical preparation of the coronal segment, they were obturated with gutta-percha using lateral condensation technique and restored with composite resin. [Figure 3 B & C]

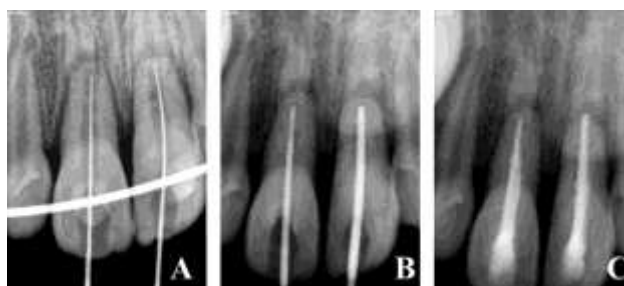


Figure 3: - A] Working length measurement; B] Master-cone selection; C] Post-Obturation.

Clinical and radiographic follow-up was performed after 30 days, 3, 6 and 12 months. At 1 month recall, the clinical examination revealed no mobility or discomfort during percussion of the maxillary right and left central incisors. On radiographic examination, there were no pathological changes. [Figure 4 A] After one year, there were no symptoms clinically and intraoral periapical radiograph revealed healing with calcific tissue at the fracture site [Figure 4 B].

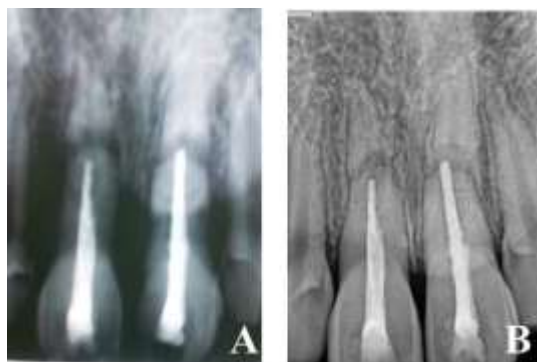


Figure 4: - A] One month follow-up; B] One year follow-up.

## Discussion

A traumatic dento/facial accident can compromise the integrity of a previously healthy dentition and result in an unsightly appearance, affecting the child's self esteem. One of the unusual sequelae to traumatic injury of a tooth is a root fracture. Root fracture is defined as a dentin and cementum fracture involving the pulp. Classification is based on the level of the fracture in relation to the apex of the root. The fracture may occur in the apical third, middle third or cervical third of the tooth. The more cervical position the fracture, the worse the prognosis.

The apical fragment usually remains in its original position while the coronal fragment is displaced. Since the crown of the tooth is often intact and stable, diagnosis of a root fracture can only be made radiographically and may require multiple radiographic exposures at different horizontal and vertical angulations for an accurate diagnosis. Clinical examination includes the evaluation of mobility, the presence or absence of tenderness and pain to palpation of the soft tissues, percussion of the teeth and pulp testing.

Horizontal root fractures may cause injury to neurovascular supply of the coronal fragment. On the contrary, the apical fragment remains essentially viable.<sup>8</sup> When a root fractures horizontally, mostly the coronal fragment get displaced and the apical segment does not generally displaced.<sup>9</sup>

The histological reactions at the fracture line are categorized into four types: (I) Interposition of calcified tissue (callus formation); (II) interposition of connective tissue, which is characterized by peripheral rounding of the fracture's ends; (III) interposition of bone and connective tissue, radiologically characterized by the clear separation of the two fragments; and (IV) interposition of granulation tissue, caused by an infected or necrotic pulp.<sup>10,11</sup>

The treatment objective is to reposition and stabilize the coronal fragment as soon as possible in its anatomically correct position to optimize healing of the neurovascular supply and periodontal ligament and maintain esthetic and functional integrity.

The patient should be priorly informed of the extent of injury and given a prediction as to the prognosis with the recommended treatment plan. Immediate treatment in horizontal root fractures includes repositioning of coronal segment and splinting and delayed management by endodontic treatment of coronal fragment.<sup>12</sup>

Radiographic examination revealed no periapical lesion in apical fragment with favourable crown-root ratio with respect to coronal fragment. So, decision was made to perform root canal treatment in coronal fragment. The patient's age at the time of injury is considered as one of the most important factors in pulpal healing after root fracture. Andreasen *et al*<sup>13</sup> studied the influence of "pre-injury and injury factors" on the healing of 400 intra-alveolar root fractures. Those authors found that the age of the patients, the stage of root growth, mobility of the coronal fragment, and dislocation of the coronal fragment

exerted the greatest influence on healing at the fracture line and on the occurrence of pulpal necrosis.

### Conclusion

A permanent tooth with root fracture that is endodontically treated may present a good prognosis, preserving esthetic and psychological integrity of the patient. Clinical and radiographic follow-up is essential for treatment success of a tooth with horizontal root fracture.

### References

1. Andrade ES, de Campos Sobrinho AL, Andrade MG, Matos JL. Root healing after horizontal fracture: a case report with a 13-year follow up. *Dent Traumatol* 2008;24(4):e1-3.
2. Hovland EJ. Horizontal root fractures. Treatment and repair. *Dent Clin North Am* 1992;36(2):509-25.
3. Andreasen FM, Andreasen JO, Cvek M. Root fractures. In: Andreasen JO, Andreasen FM, Andersson L. Textbook and color atlas of traumatic injuries to the teeth. Copenhagen: Munksgaard; 2007. p337-71.
4. Çaliskan MK, Pehlivan Y. Prognosis of root-fractured permanent incisors. *Endod Dent Traumatol* 1996;12(3):129-36.
5. Welbury RR, Kinirons MJ, Day P, Humphreys K, Gregg TA. Outcomes for root-fractured permanent incisors: a retrospective study. *Pediatr Dent* 2002;24(2):98-102.
6. Flores MT, Andersson L, Andreasen JO, Bakland LK, Malmgren B, Barnett F *et al*. Guidelines for the management of traumatic dental injuries. I. Fractures and luxations of permanent teeth. *Dent Traumatol* 2007;23(2):66-71.
7. Cvek M, Mejare I, Andreasen JO. Conservative endodontic treatment of teeth fractured in the middle or apical part of the root. *Dent Traumatol* 2004;20(5):261-9.
8. Andreasen FM, Andreasen JO, Bayer T. Prognosis of root-fractured permanent incisors prediction of healing modalities. *Dental Traumatology* 1989;5(1):11-22.
9. Cvek M, Andreasen JO, Borum MK. Healing of 208 intra-alveolar root fractures in patients aged 7-17 years. *Dent Traumatol* 2001;17(2):53-62.
10. Artvinli LB, Dural S. Spontaneously healed root fracture: report of a case. *Dent Traumatol* 2003;19(1):64-6.
11. Cvek M, Tsilingaridis G, Andreasen JO. Survival of 534 incisors after intra-alveolar root fracture in patients aged 7-17 years. *Dent Traumatol* 2008;24(4):379-87.
12. American Academy of Pediatric D. Clinical guideline on management of acute dental trauma. *Pediatric dentistry*. 2004;26(7 Suppl):120.
13. Andreasen JO, Andreasen FM, Mejare I, Cvek M. Healing of 400 intraalveolar root fractures. 1. Effect of pre-injury and injury factors such as sex, age, stage of root development, fracture type, location of fracture and severity of dislocation. *Dent Traumatol*. 2004;20(4):192-202.

### Corresponding Author

Dr. Sagorika Bose  
 Ppost Graduate Student,  
 Department of Pedodontics,  
 Teerthanker Mahaveer Dental College & Research  
 Center, Moradabad, Uttar Pradesh, INDIA  
 Email Id: - sagorika49@gmail.com