

Trabecular Variant of Juvenile Ossifying Fibroma (WHO Type) - A Rare Case Report and Review of the Literature.

Santosh Reddy G¹, K R Parameshwar Reddy², Mohammed Yousuf Qureshi³, Mohammed Abidullah⁴

¹Professor & H.O.D, Department of Oral & Maxillofacial Surgery, Malla Reddy Dental College for Women, Hyderabad, Telangana State.

²Reader, Department of Oral & Maxillofacial Surgery, Malla Reddy Institute of Dental Sciences, Hyderabad, Telangana State.

³Assistant Professor, Department of Oral & Maxillofacial Surgery, Malla Reddy Institute of Dental Sciences, Hyderabad, Telangana State.

⁴Reader, Department of Oral and Maxillofacial Pathology, S.B. Patil Dental college & Hospital, Naubad, Bider, Karnataka.

Received: January 2017

Accepted: January 2017

Copyright: © the author(s), publisher. Annals of International Medical and Dental Research (AIMDR) is an Official Publication of "Society for Health Care & Research Development". It is an open-access article distributed under the terms of the Creative Commons Attribution Non-Commercial License, which permits unrestricted non-commercial use, distribution, and reproduction in any medium, provided the original work is properly cited.

ABSTRACT

Trabecular juvenile ossifying fibroma is a rare fibro-osseous lesion that occurs in younger individuals. Clinically it shows a rapid growth with aggressive behaviour having high rate of recurrences. Histo-pathologically, trabeculae of immature bone tissue in highly cellular connective tissue are seen. We present a rare case report of JTOF in a 14 year old female patient, describing its clinical, radiographic and histopathological features along with review of its literature.

Keywords: Fibroosseous lesion, Juvenile, Maxilla, Neoplasm, Periodontal ligament, Trabeculae.

INTRODUCTION

Ossifying Fibromas (OF) represent rare Fibro-Osseous Lesions (FOL) which are benign neoplasms in nature and arise from undifferentiated periodontal ligament cells.^[1] OF are subdivided in to classical and juvenile types (JOF). WHO classification describes JOF as "an actively growing lesion consists of a cell rich fibrous stroma, containing bands of cellular osteoid without osteoblastic rimming together with trabeculae of more typical woven bone.

Name & Address of Corresponding Author

Dr Mohammed Yousuf Qureshi,
Assistant Professor,
Department of Oral & Maxillofacial Surgery,
Malla Reddy Institute of Dental Sciences, Hyderabad,
Telangana State, India.

Small foci of giant cells may also be present, and in some parts there may be abundant osteoclasts related to woven bone. Usually no fibrous capsule can be demonstrated, but like the ossifying fibroma (and unlike fibrous dysplasia), the JOF is well demarcated from the surrounding bone". JOF is categorized in to two variants psammomatoid and trabecular types (JPOF and JTOF).^[1,2]

Here, we present a rare case report of JTOF in a 14 year old female patient, describing its clinical, radiographic and histopathological features along with review of its literature.

CASE REPORT

A 14 year old female patient reported to the department of oral and maxillofacial surgery with a chief complaint of swelling over left cheek region since six months, which gradually increased and attained the present size. On examination, there was slight facial asymmetry. The swelling was firm in consistency and non-tender, measuring about 6x3cm. It extended posteriorly up to the retromolar area and anteriorly up to first premolar area [Figure 1]. A Swelling over the lower lip measuring about 4x2 cm, was also noticed extending from left corner of the mouth to the middle of lower lip. On palpation it was soft in consistency and non tender. There was no sinus opening and no pus discharge from the swelling. Multiple soft tissues nodular masses were noticed over tongue region which were soft in consistency, non tender, non pulsatile, without any sinus opening and pus discharge.

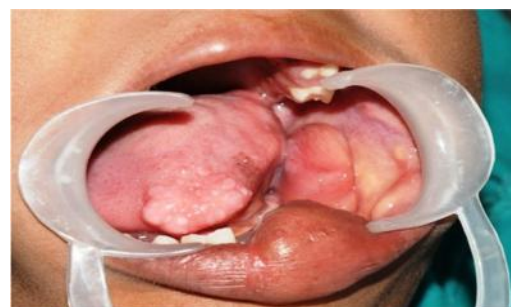

Figure 1: Intra Oral view

Radiographic examination OPG showed a radiolucent lesion over left posterior mandibular region with presence of mixed dentition with un erupted permanent teeth [Figure 2]. There was expansion and enlargement of lingual cortex over left posterior lingual aspect of mandible. 55 and 74 were decayed, 36 was missing and there was no root resorption in relation to 37. After hematological and radiological examination patient was recalled and an incisional biopsy from 75 and left buccal mucosa region was done and closure of the biopsied site was done with 3-0 black silk by placing interrupted sutures under local anesthesia. Based on clinical and radiological features, a provisional diagnosis of fibroosseous lesion was made and surgical procedure was planned under general anesthesia.

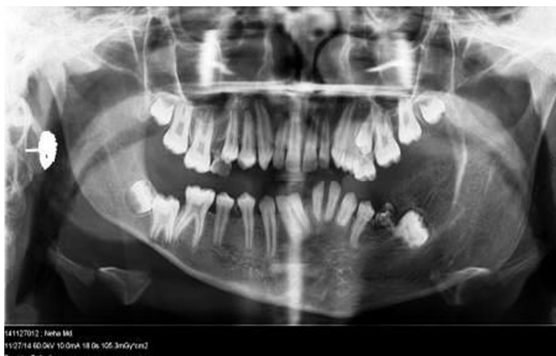

Figure 2: OPG

Surgical procedure

The area to be excised was painted with 5% povidine iodine solution, administration of lignocaine with 1:80000 adrenaline concentration was given in the form of infiltration over left posterior buccal soft tissue mucosa. A crestal incision was given extending from lower left premolar region posteriorly till anterior border of ramus, followed by reflection of soft tissue was done. With chisel and mallet excess bone was removed and irregularities were smoothed with mastoid round bur. Removal of 37 was done and closure of the area was done with 3-0 round body vicryl sutures by placing interrupted sutures. Similarly soft tissue over the left buccal mucosa, left packing dressing was placed extra orally.

The histopathological examination of excised tissue of lips and tongue showed mucosal surface lined by stratified squamous epithelium with irregularly elongated rete pegs and focal hyperkeratosis. In the underlying connective tissue, there were patchy lymphoid infiltrates and multiple small branching blood vessels in the submucosa and few lobules of mucous glands with ducts. The deeper region showed abnormal admixture of native tissue. They consists of skeletal muscle bundles, fibrous tissue, nerve bundles and blood vessels of varying sizes.

The features suggestive of Hamartoma of lip and tongue regions.

Excised tissue over buccal mucosa showed stratified squamous epithelium overlying connective tissue. Irregular trabeculae of immature bone tissue were seen in highly cellular connective tissue with many proliferating fibroblasts [Figure 3, 4 and 5]. A final diagnosis of JTOF was given.

Considering the age of the patient, no aggressive procedure was done for the asymmetry of the mandible. But we planned for regular follow up of the patient.

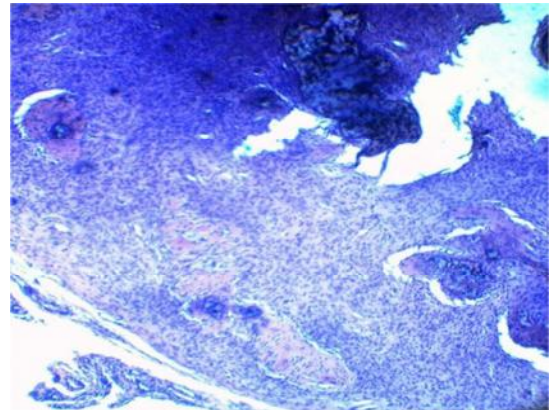


Figure 3: Photomicrograph (5x)

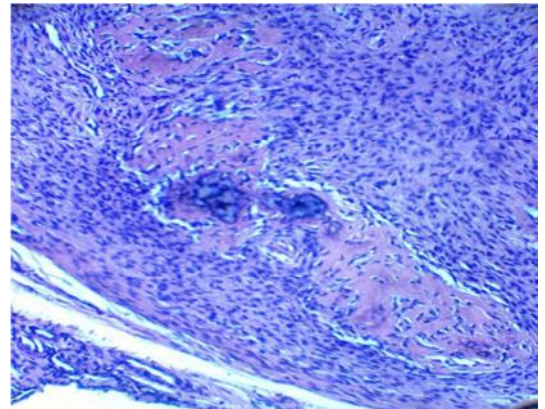


Figure 4: Photomicrograph (10x)

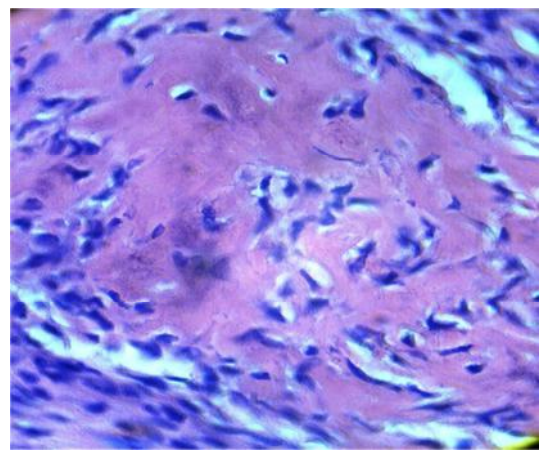


Figure 5: Photomicrograph (40x)

DISCUSSION

FOL of the head and neck region are rare and comprise a broad variety of tumors with similar histopathological findings. The lesions in this group are fibrous dysplasia (FD), cemento-osseous dysplasia (COD) and ossifying fibroma (OF).^[3] OF consists of two subtypes, conventional and juvenile (JOF).^[4] OF occurring in younger persons is termed as JOF. It differs from conventional OF by its characteristic features like occurring in younger age individuals, fast growing nature and chances of more recurrence rates. Studies have shown their prevalence to be about 2% of all oral tumors in children.^[3,4]

JOF is defined (WHO classification of odontogenic tumors) as "a lesion consisting of cell-rich fibrous tissue containing bands of cellular osteoid without osteoblastic rimming with trabeculae of more typical woven bone".^[5] Various authors have shown that the origin of JOF might be from the differentiation of mesenchymal cells of periodontal ligament, which are multi-potent precursor cells that result in formation of fibrous tissue, cementum or osteoid. Hence, these lesions are described as neoplasms containing fibrous tissue and also mineralized component in the form of cementum or bone at areas.^[6]

Literature search has revealed that JOF has been described under various terms like aggressive ossifying fibroma, active juvenile ossifying fibroma, reticular desmooosteoblastoma and active fibrous dysplasia.^[7]

There are many classification systems for JOF, Slootweg et al divided JOF into two separate categories, JOF (WHO type) and JOF-PO (psammomatoid type). The basis of their classification has been the disparity in the age of onset, the mean age of onset of JOF-WHO type being 11.8 years and that of JOF-PO being 22.6 years.^[4] Recently El-Mofty classified JOF in to two categories based on histopathologic criteria, trabecular JOF (TJOF) with trabeculae of fibrillar osteoid and woven bone and psammomatoid JOF (PJOF) with small uniform spherical ossicles that resemble psammoma bodies. They found in their study that average age of patients to be 8½–12 years and 16–33 years in TJOF and PJOF respectively. Clinically the both forms differ in their site of appearance, TJOF is mainly seen in maxilla whereas PJOF is normally seen in the paranasal sinuses.^[2]

Facial trauma was thought to have a role in etiology of TJOF in few cases, but was not seen in our case.^[8] TJOF is commonly seen in younger individuals, most of the cases in 2nd and 3rd decades, our patient was less than 15 years of age. El-Mofty in their study found male predominance, whereas our patient was a female.^[5,8] Reports have shown that TJOF is usually asymptomatic until the

growth produces a noticeable swelling, which was also seen in our case. The most common site was interdental gingiva, located anterior to molars and in the maxilla, whereas our case was seen in buccal mucosa. Most of the studies showed that the lesion has rapid growth, which was also the same in our case also.^[8,9]

Radiographically, these lesions show varied appearance, either present as radiolucent, radiopaque or mixed radiolucent-radiopaque.^[10] Our case showed a radiolucent area over left posterior mandibular region. Lesions to be included in differential diagnosis are fibrous dysplasia, osteblastoma, osteosarcoma and odontogenic tumours. Even though JOF is not capsulated, but is separated from surrounding bone by a radiopaque border thus differentiated from fibrous dysplasia. Osteoblastoma appears radiographically as a cystic bone lesion with sclerotic boundary. Osteosarcoma appears radiographically as an aggressive bone destruction. In odontogenic tumours the lesion appears to be connected to the associated teeth.^[10,11]

Histopathologically our case showed irregular trabeculae of bone in highly cellular connective tissue suggestive of JTOF as seen in other reported lesions.^[10-12]

Studies have shown that high levels of periodontal ligament activity and the constant irritation associated with both primary tooth exfoliation and permanent tooth eruption can contribute for the increased prevalence of reactive lesions in younger patients.^[13]

Rarely these lesions occur as a part of syndrome along with primary hyperparathyroidism designated as 'Hyperparathyroidism-Jaw tumor syndrome' (HPT-JT).^[14]

Genetic studies showed the presence of nonrandom chromosome break points at Xq26 and 2q33 resulting in (X; 2) translocation.^[12-14]

The recommended treatment is surgical excision. Recurrences in the range of 30 to 50% have been reported, mainly due to incomplete excision. Malignant transformation rate was found to be 0.4 to 1%.^[11,13]

As JTOF shows aggressive behaviour, clinicians should be aware of the lesion with distinct histopathology, so that proper treatment can be planned to prevent recurrence in future.

CONCLUSION

TJOF is a relatively rare FOL of the jaws, which arises in early age and has aggressive behaviour with high tendency to recur.

REFERENCES

1. Pandit N, Saini N, Kler S, Jindal S. Juvenile trabecular ossifying fibroma. J Indian Soc Periodontol. 2014;18(2): 232–5.

2. El-Mofty S. Psammomatoid and trabecular juvenile ossifying fibroma of the craniofacial skeleton: two distinct clinicopathologic entities. *Oral Surg Oral Med Oral Pathol Oral Radiol Endod.* 2002;93:296-304.
3. Kadam R, Patel S, Pathak J, Swain N, Kumar S. Trabecular Juvenile Ossifying Fibroma of the Craniofacial Skeleton: Etiopathogenesis and a Case Report of the Rare Entity. *J Contemp Dent.* 2014;4(1):51-5.
4. Slootweg PJ, Panders AK, Koopmans R, Nikkels PG. Juvenile ossifying fibroma: An analysis of 33 cases with emphasis on histopathological aspects. *J Oral Pathol Med.* 1994; 23:385-8.
5. Shekhar MG, Bokhari K. Juvenile aggressive ossifying fibroma of the maxilla. *J Indian Soc Pedod Prev Dent.* 2009;27:170-4.
6. Johnson LC et al. Juvenile active ossifying fibroma: Its nature, dynamics and origin. *Acta Otolaryngol Suppl.* 1991; 488:1-40.
7. Zama M, Gallo S, Santecchia L, Bertozzi E, De Stefano C. Juvenile active ossifying fibroma with massive involvement of the mandible. *Plast Reconstr Surg.* 2004;113:970-4.
8. Noffke CE. Juvenile ossifying fibroma of the mandible: An 8 year radiological follow-up. *Dentomaxillofac Radiol.* 1998; 27: 363-6.
9. Saiz-Pardo-Pinos AJ, Olmedo-Gaya MV, Prados-Sanchez E, Vallecillo-Capilla M. Juvenile ossifying fibroma: A case study. *Med Oral Patol Oral Cir Bucal.* 2004;9:454-8.
10. Lawton MT, Heiserman JE, Coons SW, Ragsdale BD, Spetzler RF. Juvenile active ossifying fibroma. Report of four cases. *J Neurosurg.* 1997;86(2):279-85.
11. Thankappan S, Nair S, Thomas V, Sharafudeen KP. Psammomatoid and trabecular variants of juvenile ossifying fibroma-two case reports. *Indian J Radiol Imaging.* 2009; 19(2):116-9.
12. Ravikumar R, Raghavendra K, Kumar S. Aggressive juvenile ossifying fibroma of the anterior mandible: Case report. *J Dent Sci Res.* 2011;2:26-34.
13. Rai S, Kaur M, Goel S, Prabhat M. Trabeculae type of juvenile aggressive ossifying fibroma of the maxilla: Report of two cases. *Contemp Clin Dent.* 2012; 3:S45-50.
14. Bohn OL et al. Trabecular and psammomatoid juvenile ossifying fibroma of the skull base mimicking psammomatoid meningioma. *Head and Neck Pathol.* 2011; 5: 71-75

How to cite this article: Reddy SG, Reddy KRP, Qureshi MY, Abidullah M. Trabecular Variant of Juvenile Ossifying Fibroma (WHO Type)-A Rare Case Report and Review of the Literature. *Ann. Int. Med. Den. Res.* 2017; 3(2): DE01-DE04.

Source of Support: Nil, **Conflict of Interest:** None declared