

A review of unusual complications following adenotonsillar surgery in a tertiary care center: An experience with 10 cases

Sanjay Kumar¹, Arun Patra², Anghusman Dutta³, Kashiroygoud Biradar⁴

¹Associate Professor, Department of ENT, ²Assistant Professor, Department of Anaesthesia, ⁴Resident, Department of ENT-HNS, Command Hospital Airforce Bangalore, Rajiv Gandhi University of Health Sciences, ³Professor and Head, Department of ENT-HNS, Command Hospital Airforce, Bengaluru, Karnataka, India

ABSTRACT

Background: Adenotonsillar surgery, a common surgical procedure, has been generally considered safe with minimal complications. The aim of this study was to investigate and elucidate uncommon complications observed post-adenotonsillar surgeries at a tertiary care center, aiming to enhance current clinical understanding. **Materials and Methods:** A retrospective analysis was conducted on 200 patients who underwent adenotonsillar surgeries from January 2020 to December 2021. Ten patients presenting with unusual post-operative complications were assessed. Data encompassing demographics, co-morbidities, presentation, diagnosis timeline, interventions, and management were collected. **Results:** Of the analyzed cohort, 5% (n=10) manifested unusual complications. Complications were evenly distributed across genders, with velopharyngeal insufficiency marginally more prevalent in females. Down syndrome was identified as a significant comorbidity for atlantoaxial subluxation. Age was a determining factor for complications, with atlantoaxial subluxation more common in younger patients and Eagle's syndrome in adults. Management varied from conservative to surgical interventions. **Conclusion:** Adenotonsillar surgeries, while routinely performed, can lead to unusual complications. Clinicians need to be observant postoperatively, ensuring comprehensive patient monitoring and communication. This case series contributes to the existing body of knowledge, promoting informed clinical decision-making.

Key words: Adenotonsillar surgery, Atlantoaxial subluxation, Eagle's syndrome, Post-operative complications, Tertiary care, Velopharyngeal insufficiency

Adenotonsillar surgeries, comprising tonsillectomy and adenoidectomy, are standard procedures in the domain of otolaryngology [1]. The literature extensively documents conventional complications, such as post-operative pain, hemorrhage, and infection [2]. However, there is a significant lack of comprehensive data addressing certain uncommon complications that can manifest postoperatively. The inability to identify and understand these unusual complications can have considerable implications for clinical outcomes and patient safety. Ensuring that clinicians and patients are well informed about these potential risks, although uncommon, is paramount for both clinical vigilance and comprehensive informed consent processes [3]. This study aimed to address this lack of information by presenting a detailed review of selected unusual complications observed after adeno-tonsil surgeries.

MATERIALS AND METHODS

Study Design, Setting, and Population

This study was a retrospective review of patients who underwent adenotonsillar surgeries between January 2020 and December 2021 in the Department of Otorhinolaryngology, Command Hospital Air force, Bangalore, Rajiv Gandhi University of Health Sciences, India. From a cohort of 200 patients who underwent adenotonsillar surgery within the specified timeframe, 10 patients presenting with unusual post-operative complications were selected for inclusion in this case series. In addition, the main reasons for the surgeries, such as recurrent tonsillitis or obstructive sleep apnea, were mentioned as these could have an impact on the post-operative results.

Inclusion Criteria

- Individuals of all age groups who underwent adenotonsillar surgery from January 2020 to December 2021

Correspondence to: Dr. Sanjay Kumar, Department of ENT, Command Hospital Airforce Bangalore, Rajiv Gandhi University of Health Sciences, Bengaluru, Karnataka, India. E-mail: kumarsanjay79@yahoo.co.in

© 2024 Creative Commons Attribution-NonCommercial 4.0 International License (CC BY-NC-ND 4.0).

Access this article online

Received - 23 December 2023
Initial Review - 26 December 2023
Accepted - 9 January 2024

DOI: 10.32677/yjm.v3i1.4407

Quick Response code



- Those who experienced rare or atypical complications following the surgery, which are not frequently linked with standard adenotonsillar procedures, such as velopharyngeal insufficiency (VPI), atlantoaxial subluxation, or Eagle's syndrome.

Exclusion Criteria

- Patients with incomplete medical records or follow-up data
- Patients who experienced standard post-operative complications such as post-operative pain, hemorrhage, infection, dehydration, and temporary voice changes.

Surgical Techniques

A meticulous review of medical records was conducted to ascertain the specific surgical methodologies employed for each patient. This encompassed the type of anesthesia administered, the surgical approach adopted, the instruments deployed, and any deviations from the standard procedure or intraoperative complications encountered. Predominantly, the standard cold dissection technique was employed for tonsillectomy, while adenoidectomy was primarily executed using curettage.

Definition of “Unusual” Complications

Complications were classified as “unusual” based on their observed frequency compared to the general population undergoing similar surgeries. The classification also considered the unexpected nature of these complications, diverging from standard post-operative complications lists. The rarity of these complications is further emphasized by comparing with standard complication rates from referenced studies (Windfuhr, *et al.* 2005) [2].

Data Collection

For each of the 10 cases, the following data were extracted from medical records: Patient demographics (age, gender), relevant medical history and co-morbidities, details of the surgical procedure, including the specific techniques used and any intra-operative complications, and detailed post-operative course, including the nature and timeline of the unusual complication, any interventions undertaken to address the complication, and the outcome.

Statistical Analysis

Given the descriptive nature of this case series, the primary analysis was qualitative. Patterns and insights were derived by comparing individual case complications, management techniques, and outcomes. This involved looking for commonalities, trends, or anomalies that could provide a deeper understanding of the complications' onset and progression.

Ethical Considerations

All patients included in this series provided informed consent for their medical details to be used for research and publication purposes, ensuring the protection of their confidentiality and anonymity. The case series adhered to the principles of the Declaration of Helsinki and was conducted in compliance with the guidelines set by the ethics committee of the hospital.

RESULTS

Out of the 200 patients who underwent adenotonsillar surgery at our institution between January 2020 and December 2021, 10 (5%) presented with unusual post-operative complications. Table 1 summarizes the characteristics of the selected cases, detailing the nature of complications, patient demographics, associated co-morbidities, and the management strategies adopted. This table emphasizes the diverse range of complications post-adenotonsillar surgeries and provides insights into their varied presentations and management.

Demographic Characteristics

The case series consists of 10 patients, predominantly male (60%). The mean age was 17.8 years and ranged from pediatric to middle aged. The different age ranges and rare post-operative complications in our series highlight the need for careful observation of patient management after surgery (Fig. 6).

Gender and Complication Distribution

There was an equal distribution of complications between males and females. VPI occurred more frequently in females. Nasopharyngeal stenosis was observed only in females, while taste alteration was exclusive to males (Fig. 7).

Comorbidity and Complication Distribution

Down syndrome was exclusively associated with atlantoaxial subluxation. In contrast, most other complications, such as Eagle's syndrome, nasopharyngeal stenosis, pulmonary edema, and taste alteration, did not have any linked comorbidity. VPI was observed in patients with cleft palate and those without any specific comorbidity (Fig. 8).

Clinical Features and Complication Distribution

Patients with atlantoaxial subluxation primarily presented with symptoms of neck pain and torticollis. Those diagnosed with Eagle's syndrome frequently reported throat pain and a sensation of a foreign body. Nasopharyngeal stenosis was characterized by breathing difficulty and snoring. Pulmonary edema patients showed symptoms of breathing difficulty accompanied by cough. Taste alteration, as expected, manifested as an altered

Table 1: Detailed overview of unusual post-operative complications in patients

Case no.	Complication	Age/gender	Comorbidity	Presentation and timeline	Management and outcome
1	Atlantoaxial Subluxation (Grisel's syndrome) (Figure 1a and b)	6/M	Down Syndrome (Fig. 5)	Neck pain, torticollis, 5–7 day post-operative	Cervical collar, anti-inflammatories, 4-week improvement
2	Atlantoaxial Subluxation (Grisel's syndrome)	7/F	Down Syndrome	Neck pain, torticollis, 5–7 days post-operative	Cervical collar, anti-inflammatories, 4-week improvement
3	Nasopharyngeal stenosis (Fig. 2)	8/M	Asthma	Nasal obstruction, snoring, 3 weeks post-operative	Surgical correction
4	Taste alteration	35/F	Diabetes Mellitus	Altered taste, metallic, 10 days post-operative	Zinc supplements improved in 2 months
5	VPI	5/M	None	Nasal regurgitation, hyper-nasal speech, 1-month post-operative	Speech therapy
6	VPI (Fig. 3)	6/M	None	Nasal regurgitation, hyper-nasal speech, 1-month post-operative	Speech therapy
7	VPI	7/F	Cleft palate history	Nasal regurgitation, hyper-nasal speech, 1-month post-operative	Surgical intervention
8	Eagle's syndrome (Fig. 4)	40/M	Hypertension	Throat pain radiating to the ear, post-operative	Pain management, physical therapy
9	Eagle's syndrome	38/F	Hypothyroidism	Throat pain radiating to the ear, post-operative	Pain management, physical therapy
10	Pulmonary edema	45/M	Cardiac disease	Acute respiratory distress, 12 hours post-operative	Respiratory support, diuretics, 48-h stabilization

VPI: Velopharyngeal insufficiency

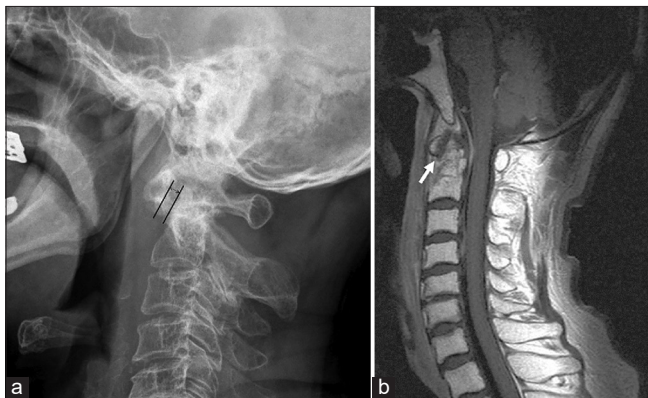

Figure 1: (a) X-ray lateral view cervical spine shows straightened curvature of cervical vertebra, and widened atlantodental interval, measuring 4 mm (gap of double head) (Grisel's syndrome), (b) T2-weighted sagittal view of cervical spine magnetic resonance imaging shows a widened atlantodental interval with heterogeneous hypointensity (white arrow) (Grisel's syndrome)

taste sensation, while VPI predominantly led to nasal speech in affected individuals (Fig. 9).

Time to Diagnosis and Complication Distribution

The time to diagnose atlantoaxial subluxation ranged between 2 and 3 days post-surgery. Eagle's syndrome diagnoses were found to be delayed, with a presentation at 10–11 days postoperatively. Patients with nasopharyngeal stenosis and taste alteration were typically diagnosed on the 4th and 2nd days, respectively. Pulmonary edema presented early, being diagnosed just a day post-surgery. VPI showed a varied

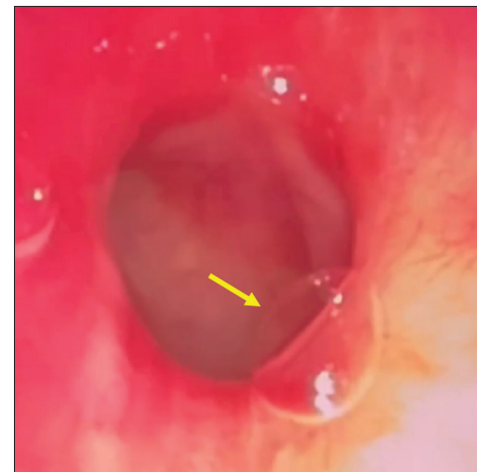


Figure 2: Fiberoptic bronchoscopy showing narrowed nasopharynx due to adhesions on left (arrow pointing) (nasopharyngeal stenosis)

presentation, with diagnoses made between 6 and 7 days after surgery (Fig. 10).

Intervention and Complication Distribution

Atlantoaxial subluxation and taste alteration were primarily managed conservatively. In contrast, Eagle's syndrome and nasopharyngeal stenosis required surgical correction. VPI was predominantly addressed through speech therapy, whereas pulmonary edema was managed conservatively (Fig. 11).

Different management techniques were used based on the complications observed. Both immediate cervical spine immobilization and conservative management with analgesics

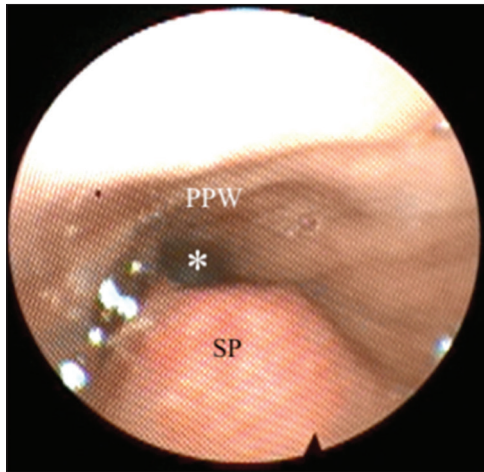


Figure 3: Nasal endoscopy showing incomplete anterior-posterior closure of the velopharynx* soft palate; posterior pharyngeal wall. (Velopharyngeal insufficiency)

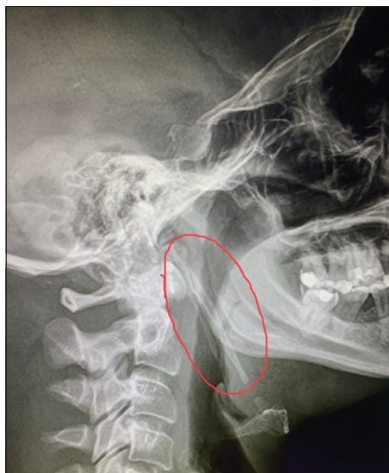

Figure 4: Lateral neck X-ray. The elongated styloid process extends from the tympanic plate of the temporal bone to the hyoid cartilage (circle enclosing) (Eagle's syndrome)



Figure 5: Down's syndrome child (Informed consent taken from the legal guardians for display of the pic)

were employed in two cases each. Speech therapy to improve resonance was the predominant technique, applied in three cases. Other methods, such as nasal steroids and saline rinses,

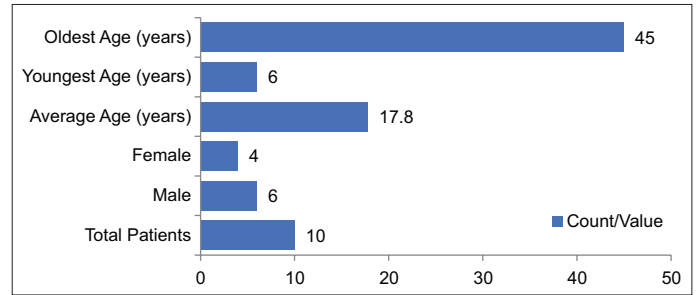


Figure 6: Demographic characteristics

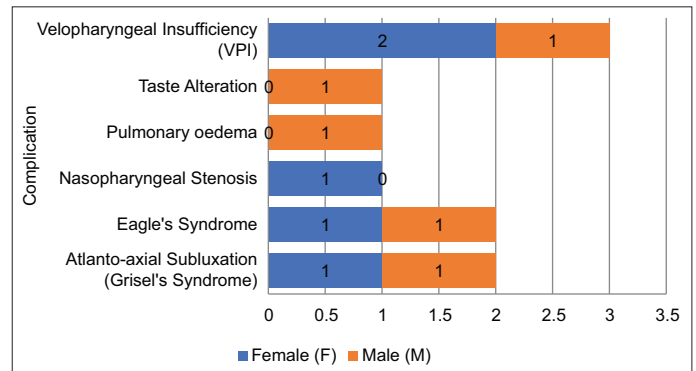


Figure 7: Gender and complication distribution

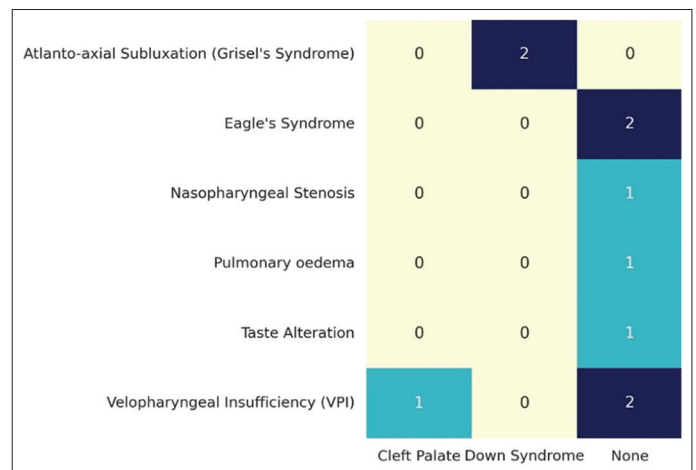


Figure 8: Comorbidity and complication distribution

conservative reassurance for transient symptoms, and immediate oxygen therapy, were each used in a single case. This highlights the diverse treatment strategies chosen for the various complications in this series (Table 2).

Age Distribution Related to Complications

The age of patients influenced the complications they experienced post-surgery. Atlantoaxial subluxation was distinctively observed in the youngest age group, specifically at 6–7 years. VPI was more prevalent in the middle childhood years, notably at ages 8, 12, and 13. Eagle's syndrome manifested later, with cases seen at 19–45 years. Pulmonary edema and taste alteration were identified in individuals aged 29–15 years, respectively. Nasopharyngeal

stenosis was a complication that appeared in early adulthood, at 23 years. These data highlight the relationship between age and the likelihood of certain complications arising after surgery (Fig. 12).

Table 2: Detailed management techniques distribution

Detailed management	Count
Immediate cervical spine immobilization	2
Nasal steroids and saline rinses	1
Mostly conservative as it is usually transient	1
Speech therapy to improve resonance	3
Conservative management with analgesics	2
Immediate oxygen therapy	1

DISCUSSION

Adenotonsillar surgery, a common surgical procedure, has been generally considered safe with minimal complications. However, post-operative complications, while unusual, can be diverse and significant. This case series has provided a unique insight into some of the unusual complications post-adenotonsillar surgery, along with the demographic information, comorbidities, clinical features, time to diagnosis, interventions, and detailed management techniques of the affected patients.

Comparison with Existing Literature

The case series revealed a uniform distribution of complications across genders, with a slight inclination of VPI toward females. Age, as our findings suggest, plays a crucial role in the manifestation of complications. Atlantoaxial subluxation was particularly observed in younger children, whereas complications like Eagle’s syndrome became more apparent in adults (Mitchell *et al.*, 2019) [1].

The association between comorbidities and complications was evident, with Down syndrome being a significant predisposing factor for atlantoaxial subluxation. This observation aligns with past studies that have identified a relationship between Down syndrome and atlantoaxial subluxation (Bocciolini *et al.*, 2005) [4]. On the other hand, most complications, such as Eagle’s Syndrome, did not have a linked comorbidity, suggesting that they could arise in the absence of predisposing factors.

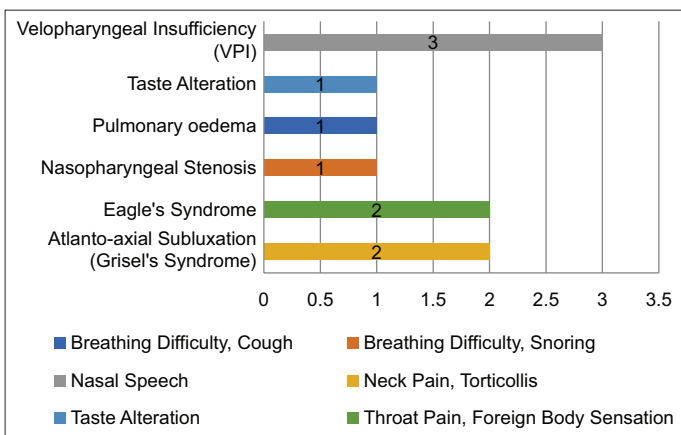


Figure 9: Clinical features and complication distribution

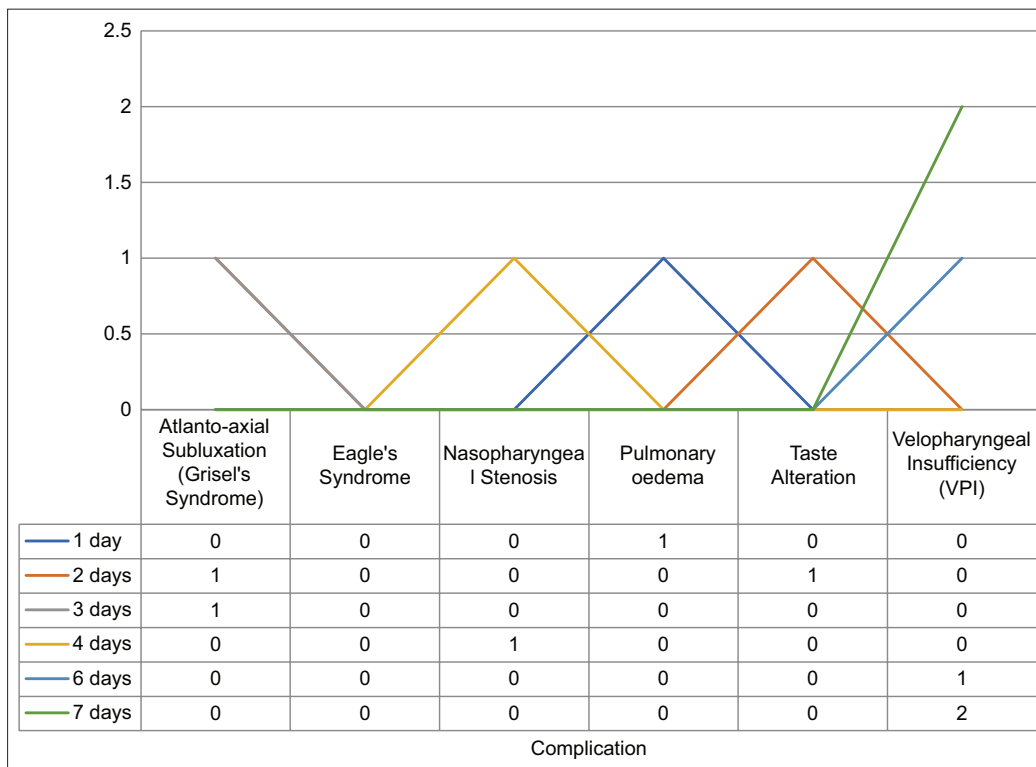


Figure 10: Time to diagnosis and complication distribution

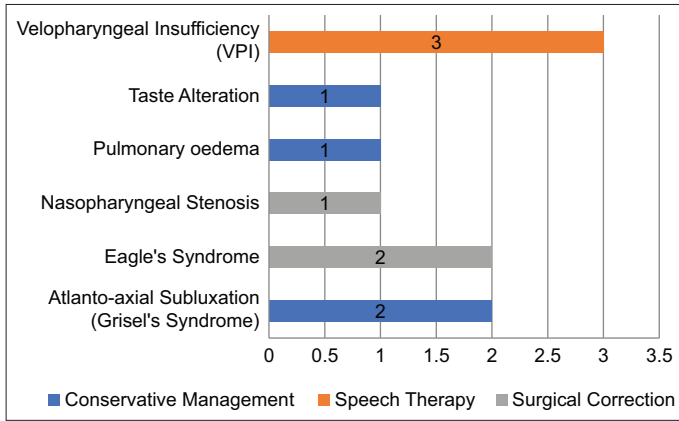


Figure 11: Intervention and complication distribution

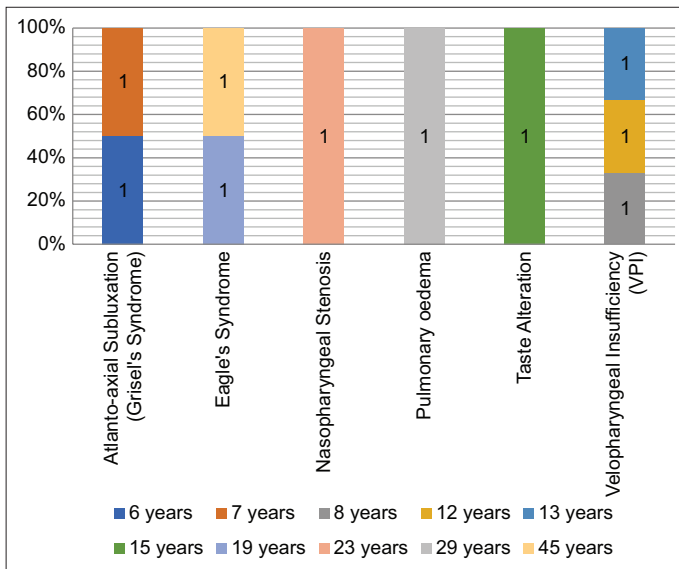


Figure 12: Age distribution related to complications

When it came to clinical presentations, each complication had a distinct symptomatology. Patients with VPI, for instance, predominantly presented with nasal speech, an observation that is consistent with previous research (Ysunza *et al.*, 1992) [5].

Taste Alteration, as seen in one of our cases, is infrequently reported but can have significant implications on quality of life [6]. The literature suggests that most cases resolve spontaneously or with minimal intervention.

The time taken to diagnose various complications post-surgery varied. While some complications such as pulmonary edema were diagnosed almost immediately [7], others like Eagle's syndrome took longer, indicating the subtlety and latent presentation of certain complications.

Interventions for complications ranged from conservative management to surgical correction. Atlantoaxial subluxation, for example, was primarily managed conservatively, which has been the recommended approach in the literature (Bocciolini *et al.*, 2005) [4]. While complications like Eagle's syndrome required surgical intervention, aligning with prior studies that advocated for the surgical removal of the elongated styloid process in persistent cases (Aydin *et al.*, 2018) [8].

In summary, the findings from this case series are compared with existing literature to provide a comprehensive understanding of post-adenotonsillar surgery complications. The data reveal associations between specific complications and patient demographics or co-morbidities.

Clinical Implications

The broader ramifications of these complications on patients' quality of life merit consideration:

- Patients with VPI may encounter social and communication challenges, potentially leading to diminished self-confidence and psychological distress
- Taste alteration, despite its transitory nature, can influence dietary preferences and overall satisfaction with food
- Persistent pain from Eagle's syndrome can interfere with daily activities such as eating, speaking, and sleeping, leading to increased psychological stress.

Financial Implications

From an economic perspective:

- Extended treatments or frequent follow-ups can escalate direct medical expenses for patients, particularly for complications necessitating surgical interventions or prolonged therapies.
- Indirect costs, encompassing missed workdays or additional caregiving, can impose financial strains on patients and their families.

In summary, while these complications are rare, their clinical, quality-of-life, and financial implications can be profound. This emphasizes the importance of comprehensive pre-operative counseling and diligent post-operative monitoring.

Limitations of the Study

The retrospective nature of this study may introduce biases due to reliance on records. The study's sample size is limited, with data from only 200 patients, of which 10 presented with unusual complications. This limited sample might not be indicative of broader trends. In addition, data from a single tertiary care center may not be representative of all clinical settings.

Preventive Measures

This series points to the potential of preventive measures. Improved patient counseling before surgery, adherence to standard surgical procedures, and strict post-operative monitoring can reduce the risk of complications. Comprehensive post-operative monitoring could be beneficial for patients with Down syndrome given their risk of atlantoaxial subluxation. Similarly, early interventions, such as physiotherapy or speech therapy at the onset of symptoms, might help manage complications like VPI.

CONCLUSION

This case series highlights the unusual complications that can occur after adenotonsillar surgeries. Although these complications are rare, they have significant clinical consequences. It is critical for physicians to prioritize thorough post-operative counseling and regular follow-up visits. Identifying these complications and associated risk factors can lead to better patient outcomes. The study contributes to current understanding and highlights the importance of ongoing research in the field of adenotonsillar surgery.

AUTHORS' CONTRIBUTIONS

All authors have made a significant contribution to the work reported, whether in conception, study design, implementation, data collection, data analysis, and interpretation, or all of these areas, they also participated in drafting, revising, or critically reviewing the article and gave final approval to publish the version.

REFERENCES

1. Mitchell RB, Archer SM, Ishman SL, *et al.* Clinical practice guideline: Tonsillectomy in children (Update)-executive summary. *Otolaryngol Head Neck Surg* 2019;160:187-205.
2. Windfuhr JP, Chen YS, Remmert S. Hemorrhage following tonsillectomy and adenoidectomy in 15,218 patients. *Otolaryngol Head Neck Surg* 2005;132:281-6.
3. Sarny S, Ossimitz G, Habermann W, *et al.* Hemorrhage following tonsil surgery: A multicenter prospective study. *Laryngoscope* 2011;121:2553-60.
4. Bocciolini C, Dall'Olio D, Cunsolo E, *et al.* Grisel's syndrome: A rare complication following adenoidectomy. *Acta Otorhinolaryngol Ital* 2005;25:245-9.
5. Ysunza A, Pamplona C, Toledo E. Change in velopharyngeal valving after speech therapy in cleft palate patients. A videonasopharyngoscopic and multi-view videofluoroscopic study. *Int J Pediatr Otorhinolaryngol* 1992;24:45-54.
6. Soldatova L, Doty RL. Post-tonsillectomy taste dysfunction: Myth or reality? *World J Otorhinolaryngol Head Neck Surg* 2018;4:77-83.
7. Westreich R, Sampson I, Shaari CM, *et al.* Negative-pressure pulmonary edema after routine septorhinoplasty: Discussion of pathophysiology, treatment, and prevention. *Arch Facial Plast Surg* 2006;8:8-15.
8. Aydin E, Quliyev H, Cinar C, *et al.* Eagle syndrome presenting with neurological symptoms. *Turk Neurosurg* 2018;28:219-25.

Funding: None; Conflicts of Interest: None Stated.

How to cite this article: Kumar S, Patra A, Dutta A, *et al.* A review of unusual complications following adenotonsillar surgery in a tertiary care center: An experience with 10 cases. *Yemen J Med.* 2024;3(1):36-42.