

Tonsillolith – A rare cause of halitosis and odynophagia in a 9-year-old girl

Maher Mohamad Najm^{1,2}, Bashar Hasan Kayal³, Abdalmalek Mohamad Najm⁴, Mohamad Zaher Shaaban¹, Lama Ahmad Alyousef⁵

From ¹Consultant, Department of Pediatrics, Pediatric Emergency Center, Hamad General Hospital, ²Clinical Lecturer, Department of Clinical Medicine, College of Medicine, Qatar University, Doha, Qatar, ³Specialist, Department of Pediatrics, Alnoor Hospital, Relief International, Taftanaz, Syria, ⁴Intern, Department of Pediatrics, Faculty of Medicine, Mansoura University, Mansoura, Egypt, ⁵Medical Student, Department of Pediatrics, Faculty of Medicine, Sivas Cumhuriyet University, Sivas, Turkey

Tonsil stones, also known as tonsilloliths or tonsiliths, are usually tiny white or yellowish mineralized structures packed with organic debris and bacteria that develop in the enlarged palatine tonsillar crypt. Tiny tonsillitis is commonly detected in diagnostic imaging such as computed tomography (CT) and less so in panoramic radiography, with the prevalence increasing with age. Giant tonsilloliths are rare and most reported cases have been in adults, with only a few cases reported in the pediatric population. In this report, we described a 9-year-old girl who had suffered from halitosis for 6 months and odynophagia with oropharyngeal foreign body sensation for 2 weeks and was later diagnosed with a tonsil stone.

A 9-year-old Syrian girl had a 1-year history of recurrent non-specific mild-to-moderate abdominal pain and recurrent sore throat, sometimes accompanied by fever, for which multiple courses of oral antibiotics were prescribed. During the past 6 months, the parents found that the girl had bad breath. The girl was examined by several pediatricians and was investigated for abdominal pain and halitosis. Complete blood counts (CBC), renal function and serum electrolytes, liver function tests, pancreatic enzymes, and urinalysis were all within normal limits. Helicobacter pylori antigen in stool was negative while the abdominal ultrasound examination was unremarkable with no gallbladder or urinary stones. Consequently, the girl was diagnosed with functional abdominal pain and poor oral hygiene-related halitosis.

Two weeks before her presentation to the emergency department, she developed occasional right otalgia, sore throat, and progressively worsening odynophagia/dysphagia, with oropharyngeal foreign body sensation, prompting her parents to seek medical attention. There was no history of fever, fish-eating, or foreign object ingestion. On examination, the patient looked well and afebrile, but examination of the head, eyes, ears, nose, and throat revealed an erythematous throat with a big white solid calculus projecting from the right tonsil (Fig. 1), the estimated size of the exposed part was 15 × 7 mm, and no dental caries was

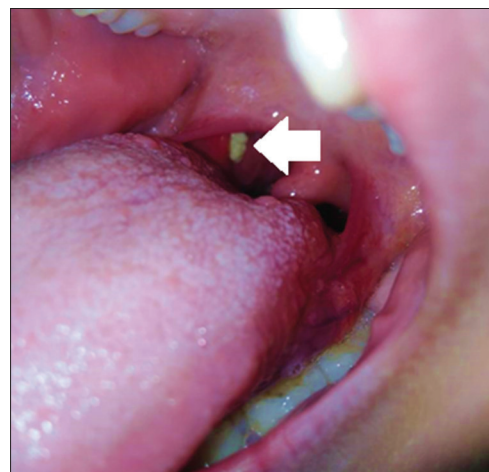


Figure 1: A tonsil stone lodged in a tonsillar crypt in the right tonsil (white arrow)

observed, and her periodontal tissues situation was good, and no palpable neck lymphadenopathy with unremarkable nose and ears examination. The rest of her examination was unremarkable. CBC was within normal limits and rapid antigen testing to investigate Group A Streptococcal infection was negative. The patient and her parents were reassured and referred to the (ear, nose, and throat) clinic advising them to use salt water gargle frequently if the daughter was cooperative and to avoid any attempts to extract the calculus to avoid the likelihood of foreign body aspiration. When we followed up with the patient 2 weeks later, the father stated that the girl had been gargling with salt water once or twice a day, and the patient reported that after a few days of gargling, foreign body sensation was disappeared, and she is mostly able to swallow solid food easily. A clinical examination confirmed that there was no tonsillar stone.

Most case reports in the literature have described the onset of tonsilloliths in adult patients, while only a few involved children [1,2]. The reason for this finding is unclear. This may be due to underreporting of cases among pediatrics or it may be attributed to the fact that tonsillolith formation is a prolonged

Access this article online

Received - 17 November 2022
Initial review - 20 November 2022
Accepted - 29 November 2022

DOI: 10.32677/yjm.v1i2.3716

Quick Response code



Correspondence to: Maher Mohamad Najm, Department of Pediatrics, Pediatric Emergency Center, Hamad General Hospital, Doha, Qatar. E-mail: dr.mmmajm@hotmail.com

© 2022 Creative Commons Attribution-NonCommercial 4.0 International License (CC BY-NC-ND 4.0).

multifactorial process that is generally completed by adulthood. Tonsilloliths in adults are generally asymptomatic and are mostly discovered incidentally during orthopantomography and CT of the neck and head [3], while in pediatrics, tonsilloliths are symptomatic in almost all reported cases [4-10] with variable clinical presentations including halitosis, foul taste, sore throat, earache, foreign body sensation, and odynophagia. Symptomatic nature of tonsilloliths in children may be attributed to their size, as all reported cases in children had large calculi [4-10].

Tonsilloliths can be small or big, single or multiple, unilateral, or bilateral. The mechanism of tonsillolith genesis is still a subject for dispute and discussion. Tonsilloliths are thought to be a result of recurrent tonsils' infection, calculi consist of a mixture of aerobic and anaerobic bacteria with organic wreckage that calcifies by deposition of minerals which change them from a soft structure to a hard concretion. Minerals usually include calcium hydroxyapatite and calcium carbonate with other minerals such as phosphorus, ammonia, and magnesium. Alternative suggested mechanisms include minor salivary ducts stagnation which lead to formation of stones, peritonsillar abscess materials calcification, and ectopic tonsillar tissue [2].

As noted in our case, the diagnosis can be easily made by clinical examination. Doubtful cases can be confirmed with imaging diagnostic techniques which will show the radiopaque shadow [3]. Management of tonsilloliths depends on the stone's size, clinical presentation, and discussion with patient and parents. Tiny and small tonsilloliths within tonsillar crypts may require nothing more than patient reassurance and may be manually extracted from the tonsil crypt. Larger tonsilloliths may require extraction by curettage under local or topical anesthesia. Giant tonsilloliths associated with significant complaints, or if there is a suspicion of malignancy, requires surgical management and tonsillectomy [2]. In our case, the stone was removed by salt water gargle. We hypothesize that in our case, the embedded portion of the tonsil stone was smaller than the exposed portion, making it easy to dislodge by repeatedly gargling with salt water, which creates vibrations

that tend to separate the stone from its lead base. As shown in our case, antibiotics should not be used routinely, unless a bacterial infection is proven.

Tonsillolith is a rarely recognized clinical entity in children that can manifest as a recurrent sore throat, foreign body sensation, odynophagia, referred otalgia, and halitosis. A thorough oral cavity clinical examination may be sufficient for diagnosis. Treatment of large tonsiloliths usually requires an otolaryngologist to remove it alone or with tonsillectomy; however, vibration movement during gargling with salt water may help in spontaneous extraction of the calculous in adults and cooperative children.

REFERENCES

1. Gangaraj SS, Maruthi N. A case report of giant Tonsillolith. *Int J Otorhinolaryngol Clin* 2013;5:100-1.
2. Mesolella M, Cimmino M, Di Martino M, *et al.* Tonsillolith. Case report and review of the literature. *Acta Otorhinolaryngol Ital* 2004;24:302-7.
3. Akahashi A, Sugawara C, Kudoh T, *et al.* Prevalence and imaging characteristics of palatine tonsilloliths evaluated on 2244 pairs of panoramic radiographs and CT images. *Clin Oral Invest* 2017;21:85-91.
4. Gulia JS, Singh V, Yadav SP, *et al.* Giant tonsillolith in a child. *Int J Pediatr Otorhinolaryngol Extra* 2006;1:19-21.
5. Thakur JS, Minhas RS, Thakur A, *et al.* Giant tonsillolith causing odynophagia in a child: A rare case report. *Cases J* 2008;1:50.
6. Dykes M, Izzat S, Pothula V. Giant tonsillolith-a rare cause of dysphagia. *J Surg Case Rep* 2012;2012:4.
7. Gulia J, Kumar A, Hooda A. Tonsillolith in a child: A case report and review of literature. *J Oral Health Community Dent* 2020;14:37-8.
8. Bai KY, Kumar BV. Tonsillolith: A polymicrobial biofilm. *Med J Armed Forces India* 2015;71:S95-8.
9. Babu TA, Joseph NM. Persistent earache due to Tonsillolith. *Indian Pediatr* 2012;49:144-5.
10. Cerný R, Bekárek V. Tonsillolith. *Acta Univ Palacki Olomuc Fac Med* 1990;126:267-73.

Funding: None; Conflicts of Interest: None Stated.

How to cite this article: Najm MM, Kayal BH, Najm AM, Shaaban MZ, Alyousef LA. Tonsillolith – A rare cause of halitosis and odynophagia in a 9-year-old girl. *Yemen J Med*. 2022;1(2):110-111.