

Content available at: <https://www.ipinnovative.com/open-access-journals>

IP International Journal of Orthopaedic Rheumatology

Journal homepage: [www.ijor.org](http://www.ijor.org)

## Original Research Article

# Uncemented total hip replacement with impaction bone grafting in protrusio acetabuli

Aman Agrawal<sup>1,\*</sup><sup>1</sup>Dept. of Orthopaedic Rheumatology, RD Gardi Medical College, Ujjain, Madhya Pradesh, India

## ARTICLE INFO

## Article history:

Received 01-11-2022

Accepted 09-01-2022

Available online 23-01-2023

## Keywords:

Protrusio Acetabuli

Morselised Bone Graft

Total Hip Replacement

## ABSTRACT

**Background and Aim:** Protrusio acetabuli is a central acetabular defect resulting from migration of femoral head medial to Kohler's line. Idiopathic central displacement of femoral head within the acetabulum is quite rare. However, it may be seen in arthritic hips secondary to rheumatoid arthritis, ankylosing spondylitis, previous trauma, osteomalacia, etc. Primary Total Hip Replacement (THR) in such cases is difficult because of the deficient medial bone, decreased peripheral bony support to the acetabular component and proximal and medial migration of the joint centre. Several techniques described previously in the surgical management of protrusio acetabuli include cemented acetabular components with cement alone or in association with morselized bone graft to reconstruct the acetabulum. However, cement has high rates of migration and loosening of cemented acetabular components in young patients leads to more revision surgeries within the first decade of implantation. The purpose of the study is to describe the technique and results of using impacted morselized bone graft with a porous coated cementless acetabular component in patients with protrusio acetabuli.

**Materials and Methods:** A total of 20 primary THR's (10 unilateral and 5 bilateral) in 15 patients (8 females and 7 males) with protrusio acetabuli were performed between 2018 and 2021, out of which 4 had mild, 7 had moderate and 9 had a severe grade of protrusion.

**Results:** A total of 10 hips were affected by rheumatoid arthritis, 3 by ankylosing spondylitis and 7 had unknown etiology. After the surgery, all bone grafts had united by the sixth month with no perceptible change in acetabular component position in any case. The mean preoperative Harris Hip Score was 48 which improved to 82 at the latest follow-up. 45% had excellent, 33% had good, and 22% had fair results. There was no dislocation.

**Conclusion:** The use of impacted morselized autograft with a cementless porous acetabular component is a good technique of restoration of hip biomechanics and sound fixation in cases of protrusio acetabuli.

This is an Open Access (OA) journal, and articles are distributed under the terms of the [Creative Commons Attribution-NonCommercial-ShareAlike 4.0 License](https://creativecommons.org/licenses/by-nc-sa/4.0/), which allows others to remix, tweak, and build upon the work non-commercially, as long as appropriate credit is given and the new creations are licensed under the identical terms.

For reprints contact: [reprint@ipinnovative.com](mailto:reprint@ipinnovative.com)

## 1. Introduction

Protrusio acetabuli is a central acetabular defect resulting from migration of femoral head medial to Kohler's line.<sup>1</sup> This results in medialization of the center of rotation (COR) of the hip. Primary Total Hip Replacement (THR) in such situations can be technically demanding due to associated significant medial and proximal migration of the center of

the joint, deficient bone medially<sup>2</sup> and reduced bony support to the acetabular component peripherally.

Cemented total hip arthroplasty resulted in promoting bone lysis and implant loosening, however, uncemented total hip arthroplasty with impacted morselized autograft with a porous coated cementless acetabular component provided a biological solution to bone deficiency and long-term fixation in arthritic hips with protrusio.<sup>3,4</sup>

\* Corresponding author.

E-mail address: [amanagrwal294@gmail.com](mailto:amanagrwal294@gmail.com) (A. Agrawal).

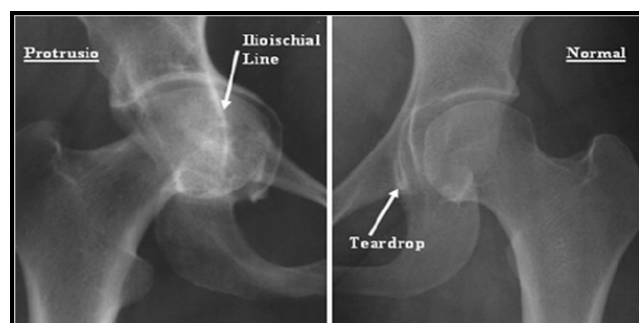


Fig. 1:

Functional outcome of uncemented total hip arthroplasty was evaluated by Harris hip score pre & post operatively in the cases.<sup>5,6</sup>

## 2. Classification

### 2.1. Sotelo-Garza and Charnley classification<sup>5</sup>

- Sotelo-Garza and Charnley used the iliioischial line on an AP radiograph of the pelvis as a reference point from which to measure the location of the acetabulum.

Grade	Protrusion (mm)
0	None (0)
I	Mild (1-5)
II	Moderate (6-15)
III	Severe (>15)

Grade	Men	Women
I	3-8 mm	6-11 mm
II	8-13 mm	12-17 mm
III	Over 13 mm with fragmentation	Over 17 mm with fragmentation

Fig. 2:

The aim of this study is to evaluate the functional and radiological outcome of using impacted morselized autograft with a porous coated cementless cup in cases of protrusio acetabuli hip joint.<sup>7,8</sup>

## 3. Materials and Methods

1. This is an Observational study conducted at R.D. Gardi Medical College and associated CRGH, Ujjain (M.P.), between period August 2019 to July 2021 on a total of 20 cases who are fulfilling the Inclusion criteria.
2. All the patients included in the study were functionally evaluated by Harris hip score pre operatively along with an X-Ray of pelvis with both hips.
3. Surgery was performed with the patient in the lateral position.
4. All the patients were operated with uncemented total hip replacement by a standard posterior (Southern Moore) approach.

5. Same type of implant was used in all the patients.
6. Dislocation of hip was challenging due to deepened acetabulum and medial displacement of the femoral head. It was facilitated by an extensive capsulotomy, along with simultaneous and sustained gentle traction and rotation.
7. Removal of posterior osteophytes before dislocation also helped.
8. Adductor tenotomy performed in cases with excessive adductor tightness.
9. In cases of difficult dislocation, femoral neck was resected in situ and the femoral head was excised piecemeal.
10. Normally, before neck osteotomy, dislocated femoral head was cut into slices with a power saw.
11. The bone slices were then morselized into 8mm-10mm sized pieces using a bone cutter.
12. After neck osteotomy, acetabular floor prepared while avoiding penetration of a soft, deficient medial wall until a bleeding bony surface was obtained.
13. Acetabular periphery reamed using large sized reamers initially.
14. The morselized graft was then introduced into the prepared acetabulum and impacted against the floor using hemispherical impactors.
15. Reverse direction reaming was done to further impact and set the graft in the floor of acetabulum.
16. An acetabular cup trial was inserted to ensure good peripheral fit and more than 50% contact with the host bone.
17. Finally, the chosen acetabular component was impacted into place.

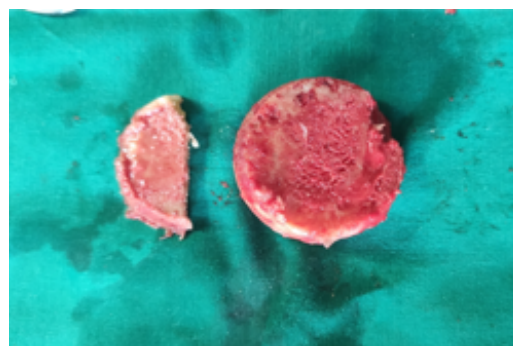


Fig. 3: Bone slice

### 3.1. Post-operative protocol

1. Post operative AP X-Ray view of the operated hip obtained.
2. Abduction pillow used during the sleeping time for 7-10 days post-operatively.



**Fig. 4:** Morsellised autograft

3. Active and active assisted range of motion exercises started within the first 24-48 hrs.
4. Partial weight bearing with a walker was advised upto 3 months until bone grafts appeared to be incorporated in xray.
5. Full weight bearing started at 3 months.

### 3.2. Follow up protocol

1. Patients were advised not to squat, not to sit crossed legged and not cross the leg across midline.
2. Patients were called upon at 6 weeks, 3 months, 6 months and 12 months follow ups.
3. At each visit functional outcome was taken according to Harris Hip score along with an X-ray pelvis with both hips.

## 4. Results

1. Maximum patients (10) were in the age group of 50-60 years.
2. With a female predominance of 8 patients (53%), and 7 male patients (47%).
3. 10 patients had unilateral involvement whereas 5 patients had bilateral involvement.
4. The most common etiology was found to be Rheumatoid Arthritis (10) followed by Idiopathic (7) followed by Ankylosing Spondylitis (3).
5. 4 had mild, 7 had moderate and 9 had severe grades of protrusio.
6. The operation time ranged from 60 to 120 minutes (mean= 79.4 ±14 mins).
7. The blood loss ranged from 200-400 ml (mean=262±36 ml).
8. The mean preoperative Harris Hip Score was 48 which improved to 90 at the latest follow-up.
9. 10 hips (50%) had excellent, 8 hips (40%) had good, and 2 hips (10%) had fair results. There was no

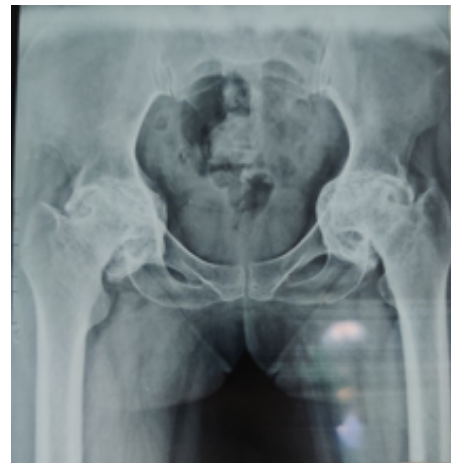dislocation.

10. The mean acetabular inclination angle was 44.2° (range 39°-47°).
11. The distance from the femoral head center to Kohler's line improved from 17.98 preoperatively to 20.36 post operatively).

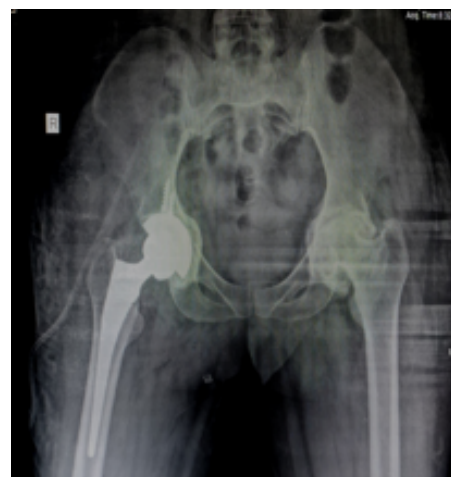**Table 1**

Harris hip score					
S.No.	Pre-Op	6 weeks	03 Months	06 Months	01 Year
1	48.4472	68.0364	76.2004	84.6428	90.0852

### 4.1. Case – 1



**Fig. 5:** PRE-OP



**Fig. 6:** Immediate post op Rt. Side

## 4.2. Case 2

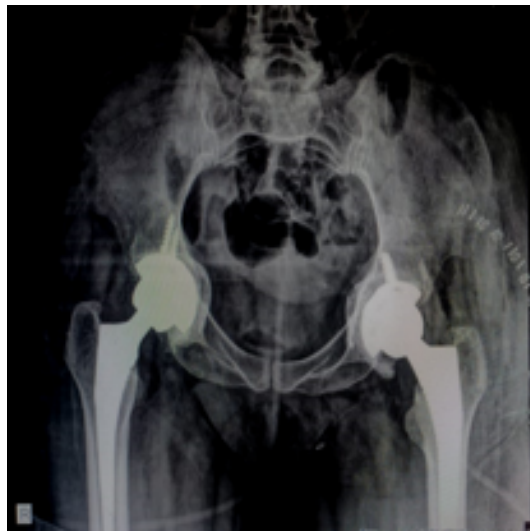

Fig. 7: Immediate post op Lt.side

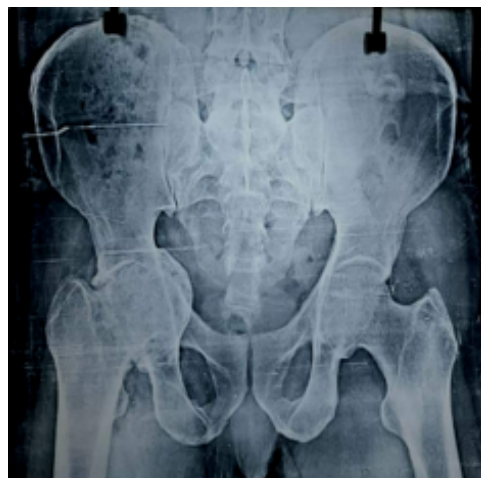

Fig. 10: Pre-op

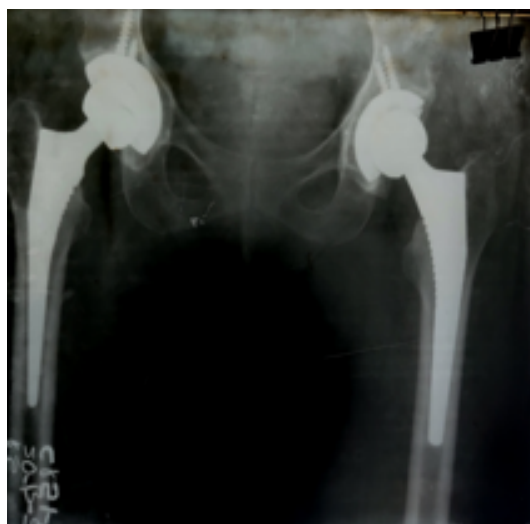


Fig. 8: 1 year post op

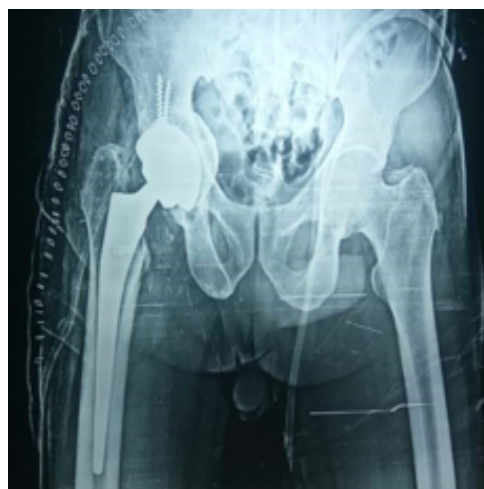

Fig. 11: Immediate post op

## 4.3. Case 3

## 5. Discussion

Study by Mullaji et al suggested that the use of impacted morselized autograft in conjunction with porous coated cementless acetabular component restored hip biomechanics after an intermediate duration follow up. 30 primary THR's were conducted with a 4.2 year follow up which showed excellent outcome in 90% patients, fair in 7% patients and poor in 3% patients.<sup>9</sup> Study by Atanu et al showed that using only cement for acetabular reconstruction in protrusio acetabuli has had unacceptably high rates of recurrence, with components migrating into the acetabulum and occurrence of thermal necrosis of the thinned out medial

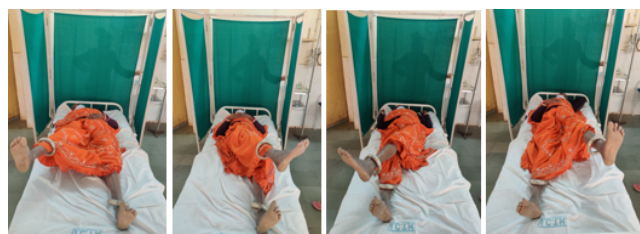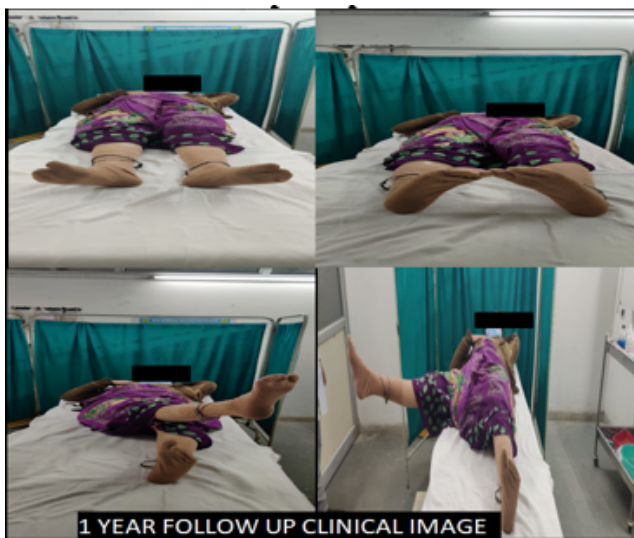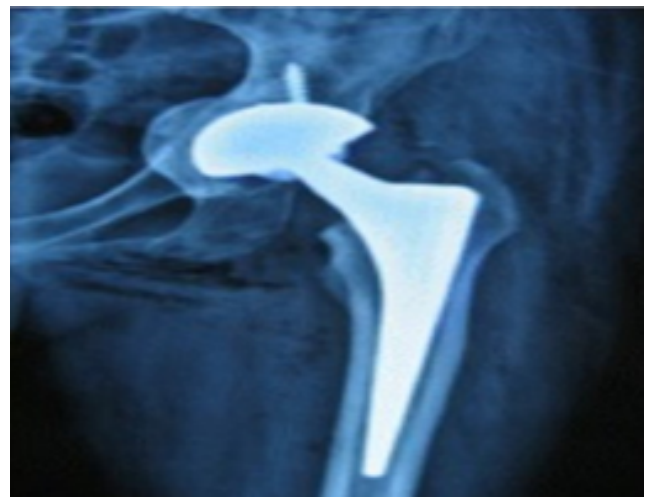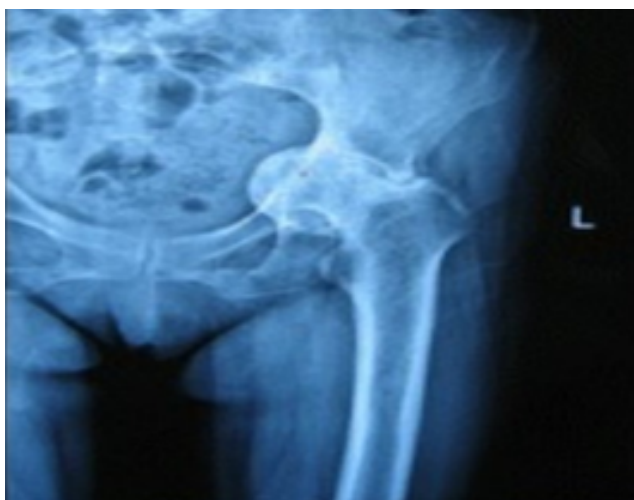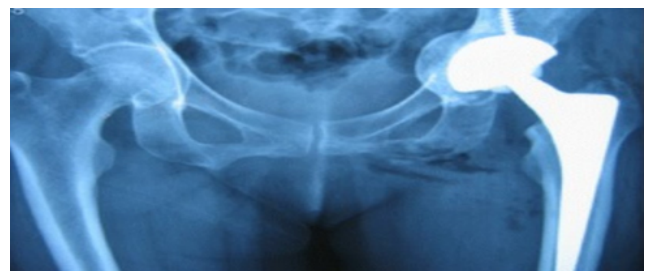


Fig. 9: 1 year follow up



**Table 2:** Comparison of results of different techniques used to treat acetabular protrusion with primary THR in literature published since 2000

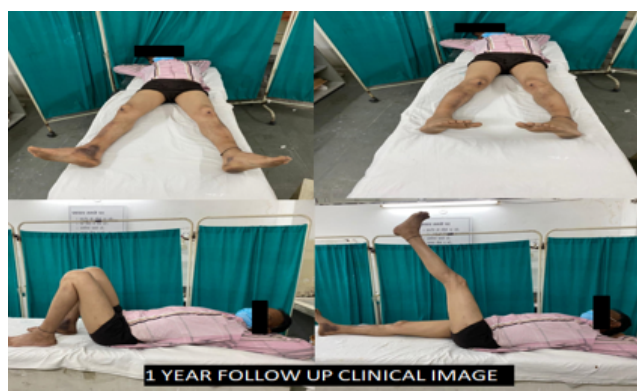Studied	No. of Hips	Mean age at surgery (Years)	Technique	Survival of acetabular component
Mullaji et al <sup>9</sup>	30	46	Impacted morselised bone graft with cement less cup	100% at 4.2 years
Garcia Cimbrello et al. <sup>11</sup>	148	54	Cemented polyethylene component	79% at 16 Years
Perwira et al <sup>12</sup>	23	62	Impacted morselised bone graft with cementless component	100% at 7.8 years
Rssenberg et al <sup>13</sup>	36	53	Impacted bone graft with cemented component	90% at 12 years
Krushell et al <sup>14</sup>	29	66	Impacted morselised bone graft with dual geometry cementless component	100% at 2 years
Current study	9	54	Impacted, morselised bone graft with cementless cup	100% at 2 yeras

**Fig. 12:** 1 Year follow up clinical image**Fig. 14:** Immediate post-op**Fig. 13:** PRE-OP**Fig. 15:** 6 Months Follow Up

wall due to heat polymerization of the cement.<sup>10</sup> These were some of the factors responsible for poor outcome.

## 6. Conclusion

We treated 20 cases of Protrusio Acetabuli of mild, moderate and severe grades by Sotello-Garza and Charnley by uncemented total hip arthroplasty using morselized



**Fig. 16:** 1 Year follow up clinical image

autograft. It helps in restoring biomechanics of hip joint and preventing recurrence of protrusio. We observed fair, good and excellent functional outcomes in our patients. There was no evidence of progression of protrusio or socket loosening in any of our cases. Osteolytic lesions were also not encountered by us in our study. All bone grafts united within 4-6 months after surgery and continuous trabecular bone that grew through the host bone and the bone graft was apparent. But a larger sample size and a longer follow up are required to ascertain this fact.

### 7. Conflict of Interest

None.

### 8. Source of Funding

None.

### References

1. Ries MD. Total hip arthroplasty in acetabular protrusio. *Orthopedics*. 2009;32(9). doi:10.3928/01477447-20090728-12.
2. Martin CT, Heiner AD, Baer TE, Pugely AJ, Noiseux NO. Protrusio After Medial Acetabular Wall Breach in Total Hip Arthroplasty. *Iowa Orthop J*. 2015;35:99-107.
3. Gerber SD, Harris WH. Femoral head autografting to augment acetabular deficiency in patients requiring total hip replacement. A

4. minimum five-year and an average seven-year follow-up study. *JBJS*. 1986;68(8):1241-8.
4. Zhen P, Li X, Zhou S, Lu H, Chen H, Liu J, et al. Total hip arthroplasty to treat acetabular protrusions secondary to rheumatoid arthritis. *J Orthop Surg Res*. 2018;13(1):1-7. doi:10.1186/s13018-018-0809-y.
5. Sotelo-Garza A, Charnley J. The results of Charnley arthroplasty of the hip performed for protrusio acetabuli. *Clin Orthop Relat Res*. 1978;(132):12-8.
6. Greig D, Hsiue PP, Chen CJ, Trikha R, Khoshbin A, Stavrakis AI, et al. Outcomes of Total Hip Arthroplasty in Patients With Acetabular Protrusio. *J Am Acad Orthop Surg Glob Res Rev*. 2020;4(7):e2000121. doi:10.5435/JAAOSGlobal-D-20-00121.
7. Slooff TJ, Huiskes R, van Horn J, Lemmens AJ. Bone grafting in total hip replacement for acetabular protrusion. *Acta Orthop Scand*. 1984;55(6):593-6. doi:10.3109/17453678408992402.
8. Zwartele RE, Witjes S, Doets HC, Stijnen T, Poll RG. Cementless total hip arthroplasty in rheumatoid arthritis: a systematic review of the literature. *Arch Orthop Trauma Surg*. 2012;132(4):535-46. doi:10.1007/s00402-011-1432-0.
9. Mullaji AB, Shetty GM. Acetabular protrusio: surgical technique of dealing with a problem in depth. *Bone Joint J*. 2013;95(11 Suppl A):37-40. doi:10.1302/0301-620X.95B11.32900.
10. Mohanty A, Parida S, Biswas R, Mohanty A. Evaluation of Uncemented Total Hip Arthroplasty in Acetabular Protrusio. *Int J Contemp Med Res*. 2020;7(5):E5-11.
11. Garcia-Cimbrelo E, Diaz-Martin A, Madero R, Munuera L. Loosening of the cup after low-friction arthroplasty in patients with acetabular protrusion. The importance of the position of the cup. *J Bone Joint Surg Br*. 2000;82(1):108-15. doi:10.1302/0301-620x.82b1.9796.
12. Pereira GC, Kubiak EN, Levine B, Chen FS, Cesare PD. Cavitary acetabular defects treated with morselized cancellous bone graft and cementless cups. *Int Orthop*. 2007;31(4):445-50.
13. Rosenberg WW, Schreurs BW, Malefijt MC, Veth RP, Slooff TJ. Impacted morsellized bone grafting and cemented primary total hip arthroplasty for acetabular protrusion in patients with rheumatoid arthritis: an 8-to 18-year follow-up study of 36 hips. *Acta Orthopaedica Scandinavica*. 2000;71(2):143-6.
14. Krushell RJ, Fingerth RJ, Gelling B. Primary total hip arthroplasty using a dual-geometry cup to treat protrusio acetabuli. *J Arthroplasty*. 2008;23(8):1128-31. doi:10.1016/j.arth.2007.09.020.

### Author biography

Aman Agrawal, Junior Resident

**Cite this article:** Agrawal A. Uncemented total hip replacement with impaction bone grafting in protrusio acetabuli. *IP Int J Orthop Rheumatol* 2022;8(2):87-92.