

Content available at: <https://www.ipinnovative.com/open-access-journals>

IP Indian Journal of Orthodontics and Dentofacial Research

Journal homepage: <https://www.ijodr.com/>

Original Research Article

Effect of premolar extraction on mandibular rotation

Deepak Chandra^{1,*}, Tripti Tikku¹, Rohit Khanna¹, Sneh Lata Verma¹,
Rana Pratap Maurya¹, Kamna Srivastava¹¹Dept. of Orthodontics & Dentofacial Research, Babu Banarasi Das College of Dental Sciences, Lucknow, Uttar Pradesh, India

ARTICLE INFO

Article history:

Received 28-07-2022

Accepted 06-10-2022

Available online 29-12-2022

Keywords:

Orthodontists

Planmeca proline XC

Cephalogram

ABSTRACT

Introduction: Various types of appliances have been tried by the Orthodontists for the fixed orthodontic treatment. Irrespective of the appliance used the main goal of retraction of anterior teeth in extraction cases is to keep the vertical dimension stable so as not to allow downward and backward rotation of mandible. The aim of this study was to compare changes in mandibular rotation following fixed orthodontic treatment on subjects who have undergone extraction of all first premolars.

Materials and Methods: Pre and post treatment lateral cephalogram of 25 subjects were taken (13 females and 12 males), aged 18-25 years and the tracings were done using Nemoceph software. Parameters assessed were facial height (anterior and posterior), mandibular plane angle (FMA & SN-GoGn), and Jaraback ratio. Student t-test was used to make statistical comparison.

Results: Mean difference of SN-GoGn(0.15 ±0.07), FMA(0.23 ±0.52), Anterior facial height(0.18±0.01) and posterior height(0.45±0.01) and Jaraback ratio(0.47±0.32) did not show statistically significant difference between pre and post treatment.

Conclusion: Mandibular plane did not alter during treatment. When adequate mechanics is followed during treatment desirable treatment outcome with insignificant alteration of mandibular plane can be achieved.

This is an Open Access (OA) journal, and articles are distributed under the terms of the [Creative Commons Attribution-NonCommercial-ShareAlike 4.0 License](https://creativecommons.org/licenses/by-nc-sa/4.0/), which allows others to remix, tweak, and build upon the work non-commercially, as long as appropriate credit is given and the new creations are licensed under the identical terms.

For reprints contact: reprint@ipinnovative.com

1. Introduction

Various types of appliances have been tried by the orthodontist for retraction of maxillary anterior teeth in extraction cases.¹ The main goal of retraction of anterior teeth in extraction cases is to keep the vertical dimension stable so as not to allow downward and backward rotation of mandible. If mandibular plane angle opens during treatment, for subjects with skeletal class II malocclusion, having retrognathic mandible, it may appear more retrognathic with downward and backward rotation of mandible. In vertical grower, downward and backward rotation of mandible may also exaggerate open bite thus worsening the aesthetics. Any unfavourable changes in mandibular angle, on completion

of orthodontic treatment affects aesthetics and balance. The extraction of all 1st premolar to gain space for relieving crowding or correction of proclination as a part of fixed orthodontic treatment is a common practice. Orthodontic mechanics, should aim at intrusion of anterior teeth and avoiding extrusion of posterior teeth. This will eliminate opening of mandibular angle in adult patients undergoing all 1st premolar extraction.

The aim of this study was to compare changes in mandibular rotation following fixed orthodontic treatment on subjects who have undergone extraction of all first premolars.

* Corresponding author.

E-mail address: deepak.c.yadav@gmail.com (D. Chandra).

1.1. Sample selection

The study was retrospective in nature thus the samples were selected only after the completion of treatment. From the records of patients in the department of orthodontics and dentofacial orthopedics, Babu Banarasi Das College of dental sciences.

2. Materials and Methods

The sample consisted of pre and post treatment lateral cephalogram of 25 subjects (13 females and 12 males) aged 18-25 years, who had undergone fixed orthodontic treatment.

Inclusion criteria for the subjects are:

1. Adult subjects (minimum age at the start of treatment was 18 years).
2. Extraction of all first premolar was planned.
3. Profile had improved during and after treatment.

Exclusion criteria

1. No other method was used for retraction such as headgears
2. Patient who had undergone orthodontic treatment previously
3. Patients who had undergone orthognathic surgery
4. Lateral cephalogram were taken from record files of the patient's lateral cephalogram was taken from the same machine (planmeca proline XC) in department of Oral medicine and Radiology (using panoramic x-ray machine planmeca proline XC) exposed at 68.0kV 5mA for a exposure time of 23.0 seconds (Figure 1). The subjects were placed at a distance of 60 inches. Soft copy of lateral cephalogram was taken by copying it into a CD rom. Nemoceph(dental studio v6.0) software was used for tracing and analysing the lateral cephalogram. The size of headfilm used was 8X10 inches.

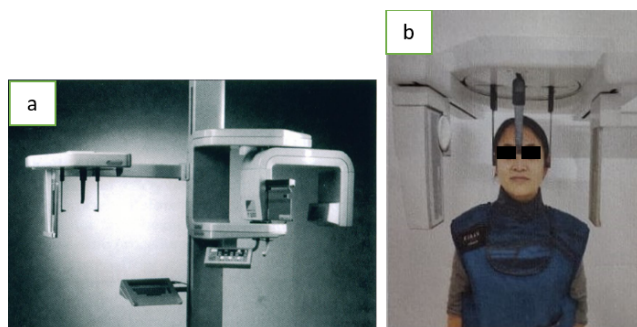


Fig. 1: a: Planmeca 2002 pan/ceph combination unit, b: Patient undergoing cephalometric exposure

Lateral cephalograms were taken using standard protocols. Lateral cephalogram was taken in natural head

position with lips relaxed and teeth in centric occlusion. Soft copies of lateral cephalograms were transferred to a computer loaded with planmeca software from where the digital lateral cephalogram was saved in bitmap file and taken into a CD ROM.

The soft copies of all the lateral cephalograms was transferred to nemotec software program (dental studio NX version 6.0).(Figure 2)

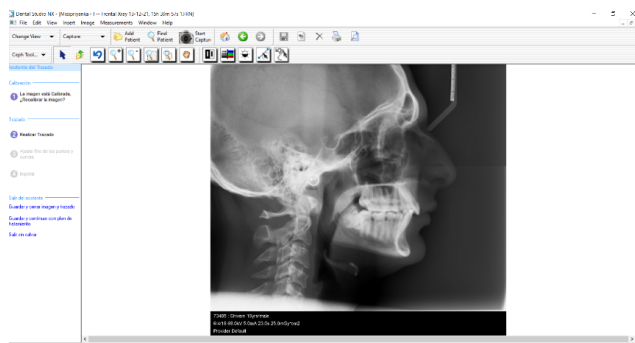


Fig. 2: Nemotec software

Calibration of image: image calibration was done by identifying the cross hairs 10mm apart on lateral cephalogram using the calibration tool of the (nemotec) software. Identification of landmarks was done after using image enhancement feature of the software like brightness, contrast adjustment and magnification were used to identify individual cephalometric landmarks as precisely as possible. The landmarks were marked using the inbuilt touchpad of the laptop, for both pre and post treatment cephalogram. Following landmarks were used in the study.(Figure 3)

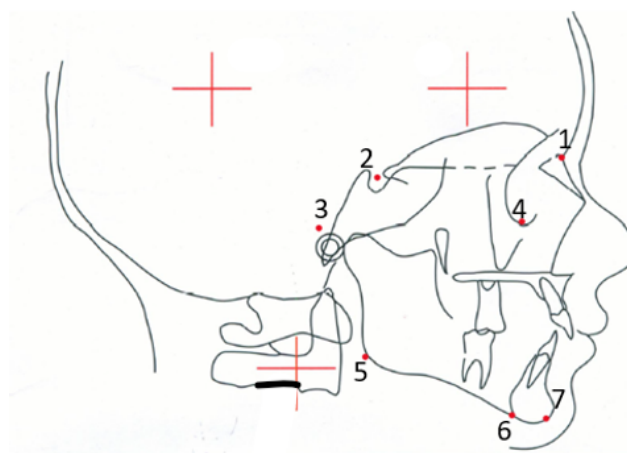


Fig. 3: Landmarks used in the study; Landmarks, 1. Nasion, 2. Sella turcica, 3. Porion, 4. Orbitalle, 5. Gonion, 6. Gnathion

Reference planes used in the study are shown in Figure 4
Parameters used to assess the changes are shown in Figure 5

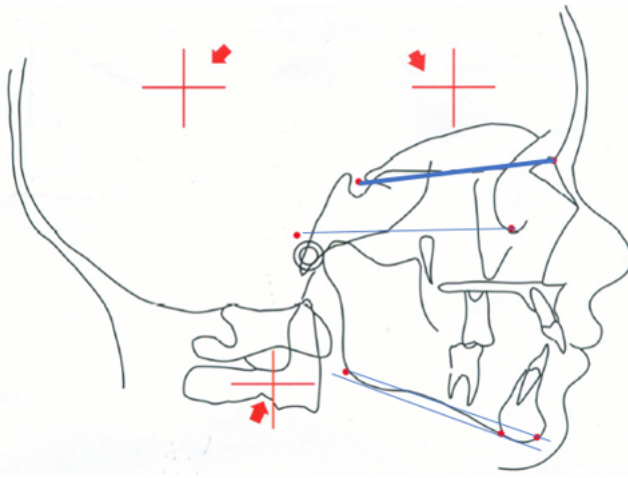


Fig. 4: Reference planes used in the study; Reference planes, 1. S-N plane, 2. Frankfort horizontal plane, 3. Mandibular plane (Go-Me), 4. Mandibular plane (Go-Gn)

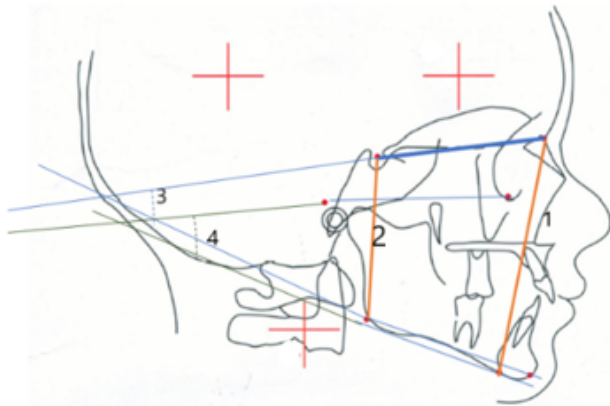


Fig. 5: Linear and Angular parameters to assess the changes

2.1. Data analysis

Data was entered into Microsoft excel data sheet and was analyzed using SPSS for Windows (Statistical Presentation System Software, SPSS Inc.) version 17.0. Continuous data was represented as mean and standard deviation. Paired t test was used to make adequate comparison.

3. Observation and Results

Comparison of various linear and angular parameter used to assess relation between group I and group II

4. Discussion

This study was aimed to assess the relationship between changes in mandibular plane angle before and after treatment in cases with premolar extraction. Brodie² stated

that the facial patterns once established did not change much. Bishara³ in his study concluded that differences among facial types were more pronounced at adulthood. Studies have shown that the growth changes of the facial tissues, although not completed, occurred predominantly before the age of 18 years, hence samples included subjects above 18 years. The results of present study stated that vertical dimension did not alter significantly from pre to post treatment in subjects who had undergone premolar extraction. Stagers,⁴ Beit,⁵ Sharma,⁶ Al-Nimri,⁷ Kim⁸ and Kocadarel⁹ showed no significant increase in vertical dimension between premolar extraction and no extraction cases. According to these authors extraction did not result in collapse of vertical dimension when compared with non extraction cases. For present study there was no alteration in mandibular plane angle in extraction cases. Similar to present study, Alhajeri-K,¹⁰ reported a non significant decrease in SNGoGn when compared to post treatment records. He also reported contradictory result for anterior facial height which showed significant increase in this study whereas it was non-significant in the present study. Aras A. et al.,¹¹ reported no significant alteration in mandibular plane related in subjects with skeletal open bite who had undergone all 1st premolar extraction. Dwivedi et al.,¹² reported significant increase in mandibular plane angle in post treatment tracing in subjects with hyperdivergent growth pattern.

Though sample was mixed in present study but we achieved no significant difference in mandibular rotation between pre and post treatment. Thus, it can be suggested that appropriate mechanism as per growth pattern must be followed so as to keep vertical dimension stable and prevent distortion of facial aesthetics.

Further studies must be directed in larger sample size divided as per growth pattern to observe changes between pre and post treatment.

5. Conclusion

1. No significant alteration in SN-GoGn angle and FMA was observed from pre to post.
2. Changes in facial height (anterior and posterior) was insignificant between pre and post treatment
3. No significant alteration was seen in Jaraback's ratio between pre and post treatment.

It can be suggested that appropriate mechanics as per growth rotation must be followed to keep vertical dimension stable.

6. Conflict of Interest

The authors declare that they have no conflict of interest.

7. Source of Funding

None.


Table 1: hows results obtained from the present study.

Days	Groups	N	Mean	Std. Deviation	Std. Error Mean	P-value
SN-Go-Gn	Group I	25	28.70	7.15	1.43	0.651
	Group II	25	28.55	7.08	1.42	
FMA	Group I	25	23.26	6.86	1.37	0.641
	Group II	25	23.49	6.34	1.27	
AFH	Group I	25	107.18	6.41	1.28	0.711
	Group II	25	107.00	6.42	1.28	
PFH	Group I	25	75.65	8.97	1.79	0.250
	Group II	25	76.10	8.96	1.79	
Ratio	Group I	25	70.47	5.86	1.17	0.226
	Group II	25	70.94	6.18	1.24	

References


- Baumrind S, Molthen R, West EE, Miller DM. Mandibular plane changes during maxillary retraction. *Am J Orthod.* 1978;74(1):32–40.
- Brodie AG. Behavior of normal and abnormal facial growth patterns. *Am J Orthod Oral Surg.* 1941;27(11):633–47.
- Bishara SE, Ortho D, Jakobsen JR. Longitudinal changes in three normal facial types. *Am J Orthod.* 1985;88(6):466–502.
- Staggers JA. Vertical changes following first premolar extractions. *Am J Orthod Dentofac Orthop.* 1994;105(1):19–24.
- Beit P, Konstantonis D, Papagiannis A, Eliades T. Vertical skeletal changes after extraction and non-extraction treatment in matched class I patients identified by a discriminant analysis: cephalometric appraisal and Procrustes superimposition. *Prog Orthod.* 2017;18(1):44. doi:10.1186/s40510-017-0198-5.
- Sharma A, Hariyani H, Vinay DS. Effect of Extraction Versus Non-extraction Orthodontic Treatment on Anterior Facial Height in Class II division 1 Malocclusion. *National J Integr Res Med.* 2014;5(1).
- Al-Nimri K. Vertical changes in class II division 1 malocclusion after premolar extractions. *Angle Orthod.* 2006;76(1):52–8.
- Baek SH, Kim TK, Kim JT, Mah J, Yang WS. First or second premolar extraction effects on facial vertical dimension. *Angle Orthod.* 2005;75(2):177–82. doi:10.1043/0003-3219(2005)075<0173:FOSPEE>2.0.CO;2.
- Kocadereli İ. The effect of first premolar extraction on vertical dimension. *Am J Orthod Dentofac Orthop.* 1999;116(1):41–5.
- Alhajeri K, Premjani P, Ismail A, Ferguson D. Changes In vertical dimension: Extraction versus non-extraction. *Orthod J Nepal.* 2019;9(1):19–27.
- Aras A. Vertical changes following orthodontic extraction treatment in skeletal open bite subjects. *Eur J Orthod.* 2002;24(4):407–16.
- Dwivedi S, Sonwane S, Chokotiya H, Patel P, Gupta G. Effect of premolar extractions on facial vertical dimension-A cephalometric study. *Indian J Orthod Dentofacial Res.* 2016;2(4):194–6.


Author biography

Deepak Chandra, Post Graduate Student  <https://orcid.org/0000-0002-4648-7219>

Tripti Tikku, Professor  <https://orcid.org/0000-0003-0054-8554>

Rohit Khanna, Professor and Head  <https://orcid.org/0000-0002-3930-9238>

Sneh Lata Verma, Reader  <https://orcid.org/0000-0002-9924-9521>

Rana Pratap Maurya, Reader  <https://orcid.org/0000-0003-4708-9842>

Kamna Srivastava, Reader  <https://orcid.org/0000-0001-9390-1454>

Cite this article: Chandra D, Tikku T, Khanna R, Verma SL, Maurya RP, Srivastava K. Effect of premolar extraction on mandibular rotation. *IP Indian J Orthod Dentofacial Res* 2022;8(4):267-270.