

Content available at: <https://www.ipinnovative.com/open-access-journals>

IP Indian Journal of Conservative and Endodontics

Journal homepage: <https://www.ijce.in/>

## Case Report

# Occlusal re-establishment of posterior teeth using stamp technique- A case report

Jasmitha Chapati<sup>1</sup>, Vamsee Krishna Nallagatla<sup>1,\*</sup>, R Bharathi Suma<sup>1</sup>,  
Chandra Sekhar Manduru<sup>1</sup>

<sup>1</sup>CKS Teja Institute of Dental Sciences and Research, Tirupati, Andhra Pradesh, India



### ARTICLE INFO

#### Article history:

Received 10-12-2022

Accepted 16-12-2022

Available online 14-01-2023

#### Keywords:

Occlusion

Stamp Technique

Composites

### ABSTRACT

According to Sturdevant, the main aim of restoration is to restore the form, function and occlusion of individual tooth which is mutilated by dental caries. To achieve all these factors many techniques and restorative materials have evolved in modern dentistry. Stamp technique is a new and decisive method for re-establishing the occlusal anatomy. In the present case report, a 15 year old male patient with occlusal caries on tooth number 37 is treated with composite restoration using stamp technique.

This is an Open Access (OA) journal, and articles are distributed under the terms of the [Creative Commons Attribution-NonCommercial-ShareAlike 4.0 License](https://creativecommons.org/licenses/by-nc-sa/4.0/), which allows others to remix, tweak, and build upon the work non-commercially, as long as appropriate credit is given and the new creations are licensed under the identical terms.

For reprints contact: [reprint@ipinnovative.com](mailto:reprint@ipinnovative.com)

## 1. Introduction

Occlusal surfaces of posterior teeth are most susceptible areas for dental caries. The primary goal of restorative material is to re-establish the occlusal anatomy, as even the mild discrepancy will alter the cusp fossa relationship.<sup>1,2</sup>

According to method of fabrication in restorative dentistry, we have direct and indirect restorations. Compared to indirect restoration, where the contact, contour and occlusion are well established in the laboratory, the direct restorations pose a challenge to achieve the same intraorally. It can be due to technique sensitive, time consuming and may not result in precise occlusal anatomy.<sup>3</sup> To achieve the benefits of indirect restorations intraorally in a single visit, Stamp technique is used because it is an admixture of function and aesthetics. It was introduced by Dr.Waseem riaz, a London based practitioner.<sup>4</sup>

This new technique involves making of occlusal stamp, which duplicates the occlusal topography of molars before preparing the cavity. Just before curing the final increment of composite restoration, the occlusal stamp obtained is

pressed over the final increment to achieve exact replica of pre operative occlusal anatomy.<sup>5</sup>

## 2. Case Report

A 15 year old male patient reported to the department of conservative dentistry and endodontics with chief complaint of black discolouration in his lower left back tooth region since 2 months. Clinical examination revealed pit and fissure caries with respective to 37. No sensitivity is present and tooth is vital. Radiographically, there is a radiolucency involving enamel and a part of dentin with no pulpal involvement. Following this, the patient was explained about the treatment protocol and a written consent is obtained.

Before starting the procedure, oral prophylaxis is done, later shade selection is done using vita shade guide then the tooth was isolated followed by application of separating medium on the tooth surface. Then stamp is made using flowable composite material to record the occlusal details.<sup>6</sup> Flowable composite is placed on the occlusal surface and a micro brush is attached to composite to use it as a handle, light cured for 20 sec, according to manufacturer instructions and the template is removed from the tooth.

\* Corresponding author.

E-mail address: [dr.vamseekrishna@gmail.com](mailto:dr.vamseekrishna@gmail.com) (V. K. Nallagatla).

Cariou lesion is excavated and simple class 1 cavity is prepared. Etching is done for 15-20 sec, then the acid is rinsed with water and checked for white frosty appearance. Bonding agent is applied, light cured for 20 sec according to manufacturer instructions. Incremental technique for composite restoration is used upto 1mm short of occlusal surface and each layer is light cured for 20 sec. Later, the last layer of composite is applied, then a teflon material is placed on it and the prepared template is placed. A gentle pressure is applied over it and the stamp along with the Teflon material is removed. The excess material which is flowed over the cusps is removed and light cured for 20 sec. Occlusion is checked for premature contacts and no high points are recorded. Minimal finishing and polishing is done.

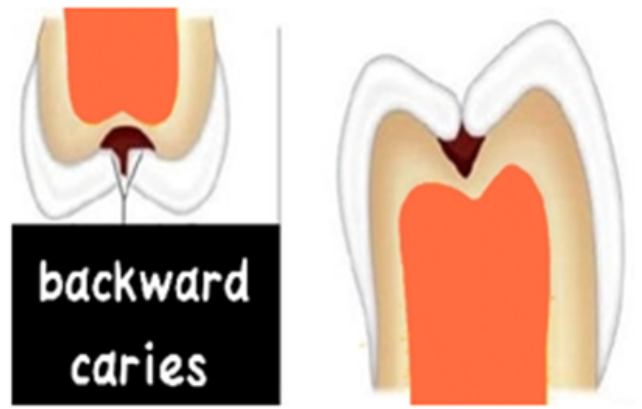

Fig. 3: Backward caries

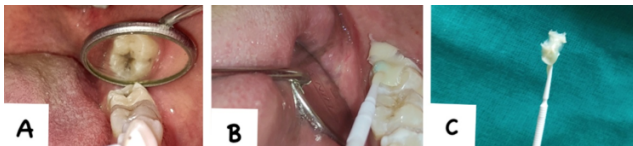

Fig. 1: A: Pre operative image; B: Occlusal stamp preparation; C: Occlusal stamp

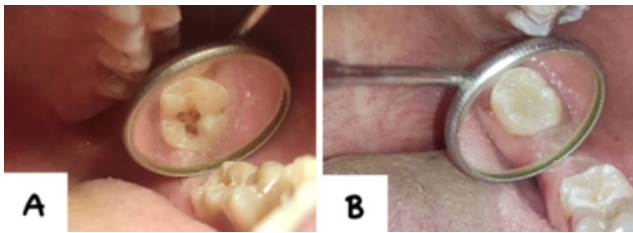


Fig. 2: A: Cavity preparation; B: Post operative

### 3. Discussion

Re-establishment of occlusal anatomy in anterior teeth is mostly concerned to aesthetics but in posterior teeth it is mainly helpful in maintaining proper masticatory function of the restored teeth and cusp fossa relationship with antagonist teeth. Unfavourable occlusion can cause alterations in temporomandibular joint, centric occlusion, teeth and its supporting structures.<sup>6</sup>

The use of stamp technique in class I cavities with intact occlusal morphology and in occult caries helps to re-establish the natural contour of the tooth.<sup>7</sup> This technique is also indicated in the lesions called fluoride bombs, where undermined dentin decay in absence of frank cavitation.<sup>8</sup>

In Backward caries and occlusal hidden caries, on clinical examination only a small carious lesion is seen but radiographically we will find an extended lesion in the dentin with undermined enamel. In such cases, for complete excavation of lesion we should prepare a large cavity and

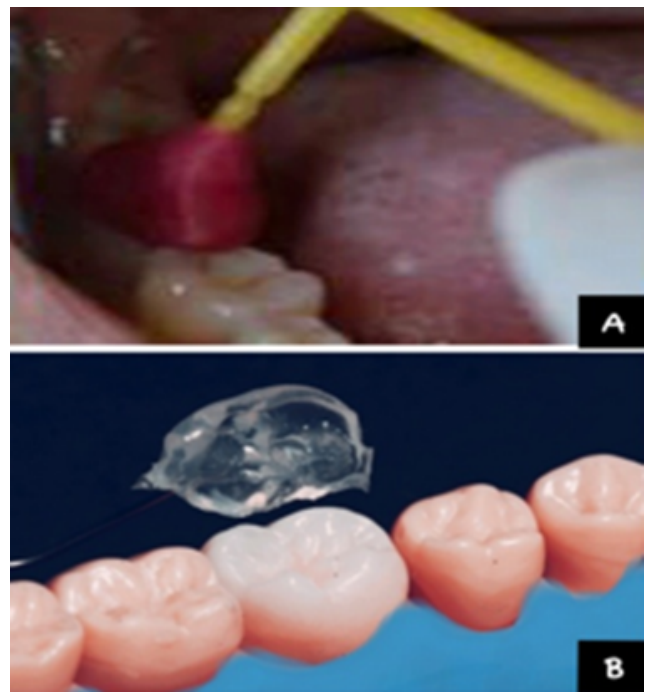
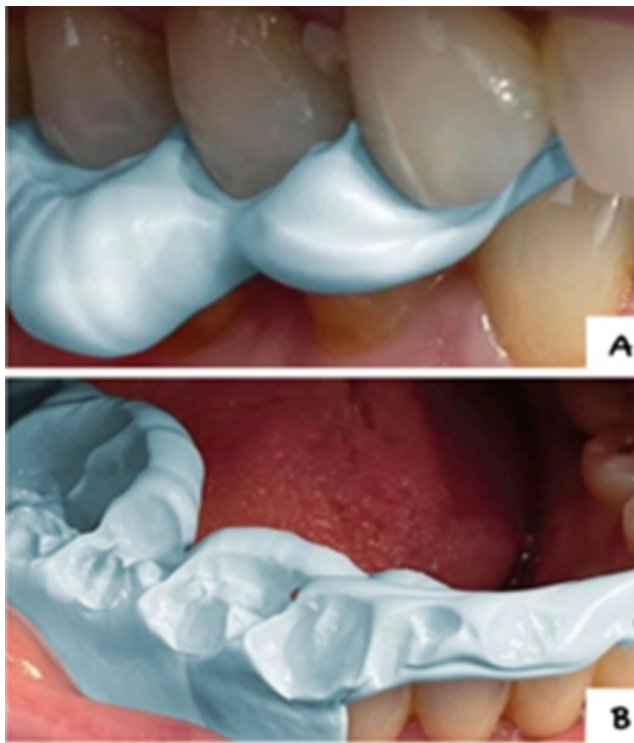

Fig. 4: A: Impression compound; B: Silicone stamp

this poses a challenge to restore the occlusal anatomy, there stamp technique plays a major role to re-establish the anatomy of the tooth.<sup>9,10</sup>

In present case report, for the stamp preparation flowable composite material is used to record the occlusal details. Other materials which are used for stamp preparation to record the occlusal details are polyvinyl siloxane impression materials, bite registration paste, clear poly methyl methacrylate, pattern resin, pit and fissure sealants, impression compound, thermoforming foil.<sup>3,11–15</sup>



**Fig. 5: A,B:** Bite registration paste

### 3.1. Silicone stamp technique

In this technique occlusal stamp is made using a transparent addition- vulcanizing 2-component vinyl polysiloxane. The surface layer was polymerized for 20s from the buccal and 20 sec from the lingual side of the stamp with the light curing lamp and defined digital pressure of 5N is applied onto the top of silicone stamp.<sup>16</sup>

According to Gabriele conte, due to stiffness of the resin matrix, it will be difficult to remove the stamp from the undercuts once it gets completely polymerized. Besides, the removal of stamp before the resin is completely cured will lead to deformation of the stamp. Considering all these factors, he proposed utilizing a polyvinyl siloxane material to record the occlusal details.<sup>17</sup>

It is imperative to mention that the correct and precise placement of occlusal stamp is a prerequisite to achieve the accurate cusp fossa relationship. The degree of porosities present in the final restoration is considerably reduced and increases the strength of the restoration. This is due to the fact that the stamp exerts pressure on the composite, there by reduces the formation of micro bubbles. These factors have been shown to be major determinants for long term success of composite restoration.<sup>5,7,18,19</sup>

The potential limitation of this technique is, only for desired cases it can be used. Nevertheless, modification in technique and further research, expands the scope of its use.<sup>20</sup>

## 4. Conclusion

The stamp technique helps us to restore the direct posterior restorations with natural topography and with less post restoration adjustments. This technique aids in achieving aesthetics and functional rehabilitation effortlessly in a single visit.

## 5. Conflict of Interest

None.

## 6. Source of Funding

None.


## References


1. Tambake NJ, Tambake S, Gandhi N, Jadhav Y, Madhu K, Burad P, et al. Sumit tambake , Dr.neha gandhi, Dr.yogesh jadhav, Dr. Kumari madhu, Dr.pratik burad. *IOSR J Dent Med Sci.* 2017;16(6):49–51.
2. Mishra L, Dash G, Govind S, Jena SP, Pattanaik S, Kumar M, et al. Different Techniques to Establish Occlusal Anatomy of Posterior Teeth with Composite. A Review. *Indian J Forensic Med Toxicol.* 2020;14(4):8175–9.
3. Geena M, Jayadevan A. Microbrush stamp technique to achieve occlusal topography for composite resin restorations- A Technical report. *J Sci Dent.* 2016;6(2):76–82. doi:10.5005/jsd-6-2-76.
4. Patel SS, Shah SJ, Solanki VD, Patel BN, Ruparelia NK. Stamp technique to restore occlusal anatomy of the posterior tooth: A case report. *IP Indian J Conserv Endodod.* 2021;6(1):64–6.
5. Jaiswal A, Ikhar A, Nikhade P, Chandak M, Relan K, Rathi S, et al. Replica of Anatomy of Posterior Teeth using Stamp Technique- A Case Report. *Eur J Mol Clin Med.* 2020;7(7):1661–5.
6. Gupta R, Thakur S, Mallikarjun G, Fares K, Jayasheel A. Mallikarjun goud k, Fares kt , Arun jayasheel. A biomimetic approach for class I restorations using stamp technique: A case report. *Int J Appl Dent Sci.* 2021;7(2):161–3.
7. Agrawal P, Nikhade P. Stamp Approach for Posterior Composite Restorations: A Case Report. *Cureus.* 2022;14(7):e26584. doi:10.7759/cureus.26584.
8. Murashkin A. Direct posterior composite restorations usings stamp technique-conventional and modified: A case series. *IJDR.* 2017;2(1):3–7.
9. Mabrouk R, Oueslati A, Frih N. Direct restoration of posterior teeth using stamp technique and bulk fill composite resin. *J Dent App.* 2020;6(1):444–6.
10. Pompeu JGF, Morais RC, Ferreira TO, Prado VLG, Sampaio TJS, Pedrosa M, et al. Marlus da Silva Pedrosa et al. Occlusal stamp technique for direct resin composite restoration: A clinical case report. *Int J Recent Sci Res.* 2016;7(7):12427–30.
11. Shafi N, Sanjeev MN, Kaur H, Choudhary R, Yeluri R. Replicating Occlusal Topography Via Stamp Technique. *Essent Dent.* 2022;1(2):62–5. doi:10.5152/EssentDent.2022.21005.
12. Shamra F, Prasad K, Ghorpade B, Sajeev N. Microbrush Stamp Technique for Direct Composite Resin Restoration-A Clinical Case Report. *J Adv Med Dent Sci.* 2019;7(12):90–4.
13. Alshehadat SA, Halim MS, Carmen K, Fung CS. The stamp technique for direct Class II composite restorations: A case series. *J Conserv Dent.* 2016;19(5):490–3.
14. Carneiro ER, Paula A, Saraiva J, Coelho A, Amaro I, Marto CM, et al. Aesthetic restoration of posterior teeth using different occlusal matrix technique. *Br Dent J.* 2021;231(2):88–92. doi:10.1038/s41415-021-3225-3.
15. Hamilton JC, Krestik KE, Dennison JB. Evaluation of custom occlusal matrix technique for posterior light-cured composites. *Oper Dent.*


- 1998;23(6):303–7.
16. Christian D, Klein C, von Ohle C, Wolff D, Meller C. A quantitative assessment of silicone and PTFE-based stamp techniques for restoring occlusal anatomy using resin-based composites. *Clin Oral Invest.* 2022;26(1):207–15. doi:10.1007/s00784-021-03992-8.
  17. Conte G, Cianconi L. A clear PVS matrix technique for the placement of posterior direct composites. *Dent Today.* 2008;27(5):126–7.
  18. Zakirulla M, Ziad A, Alshehri N, Raji D, Alruwaili A, Alqarni OA, et al. Occlusal stamp technique: knowledge and perception of dentist towards novel technique for composite restoration. *J Res Med Dent Sci.* 2022;10(11):58–61.
  19. Soesilo D, Hadinata Y, Pangabdian F, Rochyani L. Direct composite restoration using stamp technique and pizza technique: A case report. *IJDR.* 2020;5(1):4–6.
  20. Shikha S. Biomimetic dentistry using Stamp Technique for Direct Posterior Composite Restorations: A Case Report. *Acta Scientific Dent Sci.* 2019;3(9):69–73.

## Author biography

**Jasmitha Chapati, BDS**  <https://orcid.org/0000-0003-1786-8888>

**Vamsee Krishna Nallagatla, Professor**  <https://orcid.org/0000-0003-0226-1071>

**R Bharathi Suma, Assistant Professor**  <https://orcid.org/0000-0003-1135-5344>

**Chandra Sekhar Manduru, Professor and HOD**  <https://orcid.org/0000-0002-9541-2563>

**Cite this article:** Chapati J, Nallagatla VK, Suma RB, Manduru CS. Occlusal re-establishment of posterior teeth using stamp technique- A case report. *IP Indian J Conserv Endod* 2022;7(4):190-193.