

Content available at: <https://www.ipinnovative.com/open-access-journals>

Indian Journal of Clinical Anatomy and Physiology

Journal homepage: <https://www.ijcap.org/>

Case Report

Bilateral bony fusion of sacroiliac joint- A rare case report

Rashmi C Goshi^{1,*}

¹Dept. of Anatomy, JSS Medical College, Mysuru, Karnataka, India



ARTICLE INFO

Article history:

Received 16-11-2022

Accepted 03-12-2022

Available online 12-01-2023

Keywords:

SI joint

Spondyloarthropathies

Back ache

ABSTRACT

SI joint dysfunction is responsible for about 15-30% of low backache causes. It is crucial for locomotor activity as well as delivery during labour. It aids in axial body weight transmission and distribution from the sacrum to the pelvis. Limited gliding movements occur within joint cavity of this synovial joint. They are a category of inflammatory illnesses that affect the vertebral spines and peripheral joints, with stiffness as a common symptom. Anatomical differences in SI joint morphology, such as auxiliary SI joint, ilio sacral complex and sacral defect, and dimorphic joint, are of compelling interest when it comes to SI joint diseases. Obese people suffer from a variety of health problems related to sacroiliac joint.

This is an Open Access (OA) journal, and articles are distributed under the terms of the [Creative Commons Attribution-NonCommercial-ShareAlike 4.0 License](https://creativecommons.org/licenses/by-nc-sa/4.0/), which allows others to remix, tweak, and build upon the work non-commercially, as long as appropriate credit is given and the new creations are licensed under the identical terms.

For reprints contact: reprint@ipinnovative.com

1. Case Report

This case report describes a bilateral fusion of the SI joint discovered in a skeleton at JSS Medical College in Mysuru, Karnataka, India. There was a complete Bilateral fusion of the ventral surface of the posterior most segment of the iliac crest, including both the posterosuperior and posteroinferior iliac spine, and anteriorly throughout the line of articulation between the ilium and the corresponding articular surface of the sacrum except a small part in the superior part in this bony pelvis. (Figures 1 and 2) Pelvic anthropometrics were used to determine the gender of the bone (pelvis). The sacral index was 97.3 (92.42 to 99.03), the Ischiopubic Index (IPI) was 108.6 (84 to 118), the larger sciatic notch angle was 50°, and the subpubic angle was 92° (Female).

2. Discussion

Joint fusion can be due to inflammation, fibrosis, calcification leading to decreased joint mobility. The process of calcification termed as biomineralisation that

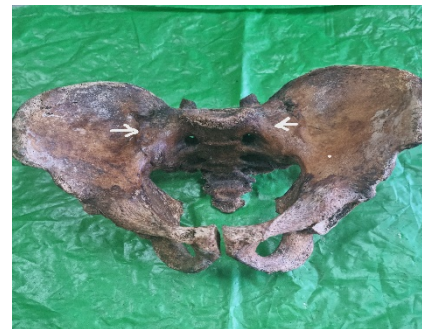

Fig. 1: Anterosuperior view of pelvis: arrows indicating fused sacroiliac joint

can take a pathological turn in some tissues of the human body namely arteries, cartilages, muscles, joints, and so on.¹ In the human body, the SI joint is a skeletal structure that is prone to Ankylosing Spondylitis alterations. This joint is responsible for distributing and transmitting body weight through the pelvic girdle in a consistent manner. In clinical practise, about 15-30% of cases with the predominant complaint of low backache

* Corresponding author.

E-mail address: rashmicgoshi@jssuni.edu.in (R. C. Goshi).

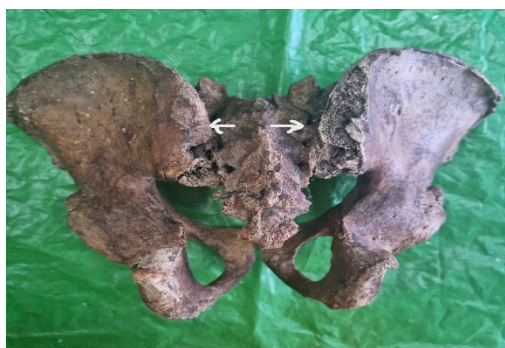

Fig. 2: Posterior superior view of pelvis: arrows indicating fused portion of sacroiliac joint

are connected to SI joint inflammation,^{2,3} which is a significant cause that is often neglected by clinicians, necessitating a complete examination of SI structural and functional fitness. As seen in this example, SI fusion on both sides is a somewhat unusual event. This misrepresentation might be caused by aberrant bone metabolism, which results in the formation of osteophytes, or excessive bone development on the bone's edge, which can result in bridging between the bones, leading in ankylosis symptoms. Chondrogenesis is a precursor to active bone growth and osteophyte production, and it resembles the healing process in damaged bones.⁴ Over time, additional bone deposition may occur, culminating in osteophyte growth and eventual fusion of articular portions between the ala of the sacrum and the ilium part of the hipbone. Osteophyte production could be caused by advanced ageing, excessive biochemical activity of cells, mechanical stimulation, and other factors. Such structural abnormalities can be detected in healthy people without causing any symptoms until they produce undue compression on nearby structures. Joint stiffness, mobility restriction, and pain may result with these alterations.^{5,6} The production of osteophyte bones is influenced by a number of biological growth factors such as Transforming growth factor, a multifunctional cytokine.⁷ Noninvasive radiological examinations serve an important role in the early clinical diagnosis of unresolved clinical symptoms of low back pain. SI scans utilising Positron Emission Tomography and Computed Tomography (PET-CT) are more sensitive than CT or MRI in terms of quantifying inflammation and assessing the condition of reactive bone formation using the F-fluorodeoxyglucose (FDG) (18F-fluorodeoxyglucose) and NaF (F-sodium fluoride) test.⁸ Increased BMI exerts a strain on locomotor activity, which has been connected to SI inflammatory changes. The metabolic activity measured by FDG and NaF PET/CT on each side of SI is linked to the patient's BMI. It's likely that the degree of inflammatory changes between the right and

left SI joints changed because the extent of fusion of the SI joint differed bilaterally.

3. Conclusion

Osteology is a necessary precursor for further study of the musculoskeletal system. The SI joint abnormalities are among the AS illnesses that represent significant clinical problems in terms of diagnosis and therapy of low back pain. In order to make an early clinical diagnosis, an unbiased patient assessment and selective radiological examinations are essential. In order to address complaints of low back discomfort, orthopaedicians, neurosurgeons, and physiotherapists need to be aware of atypical variations like the one in this case.

4. Source of Funding

None.


5. Conflict of Interest

None.

References

1. Pawlikowski M. Centres of human tissue biomineralisation (Calcification). *Cardiol Cardiovascmed*. 2017;1(6):252–61.
2. Martin BI, Turner JA, Mirza SK, Lee MJ, Comstock BA, Deyo RA. Trends in health care expenditures, utilization, and health status among US adults with spine problems. *Spine (Phila Pa 1976)*. 1997;34(19):2077–84.
3. Sembrano JN, Polly DW. How often is low back pain not coming from the back? *Spine (Phila Pa 1976)*. 2009;34(1):27–32.
4. Kraan P, Berg W. Osteophytes: relevance and biology. *Osteoarthritis Cartilage*. 2007;15(3):237–44.
5. Snodgrass JJ. Sex differences and aging of the vertebral column. *J Forensic Sci*. 2004;49(3):458–63.
6. Rabelo GD, Scheidt A, Klebig F, Hemmatian H, Citak F, Amling M, et al. Multiscale bone quality analysis in osteoarthritic knee joints reveal a role of the mechanosensory osteocyte network in osteophytes. *Sci Rep*. 2020;10:673.
7. Uchino M, Izumi T, Tominaga T, Wakita R, Minehara H, Sekiguchi M. Growth factor expression in the osteophytes of the human femoral head in osteoarthritis. *Clin Orthop Relat Res*. 2000;377:119–25.
8. Raynal M, Bouderraoui F, Ouichka R, Melchior J, Morel O, Blum A, et al. Performance of 18F-sodium fluoride positron emission tomography with computed tomography to assess inflammatory and structural sacroiliitis on magnetic resonance imaging and computed tomography, respectively, in axial spondyloarthritis. *Arthritis Res Ther*. 2019;21(1):119.

Author biography

Rashmi C Goshi, Assistant Professor  <https://orcid.org/0000-0001-6803-2576>

Cite this article: Goshi RC. Bilateral bony fusion of sacroiliac joint- A rare case report. *Indian J Clin Anat Physiol* 2022;9(4):283-284.